8. ATRİYAL FİBRİLASYON ZİRVESİ 2019
8 - 9 Subat 2019 Xanadu Hotel, Belek, Antalya

"PAPİLLER KAS ARİTMİLERİ"

Dr. Özcan ÖZEKE
Türkiye Yüksek İhtisas Hastanesi

Ventricular arrhythmias originating from a papillary muscle in patients without prior infarction: a comparison with fascicular arrhythmias.

Good E, Desjardins B, Jongnarangsin K, Oral H, Chugh A, Ebinger M, Pelosi F, Morady F, Bogun F.
Heart Rhythm. 2008 Nov;5(11):1530-7. doi: 10.1016/j.hrthm.2008.08.032.

Post-infarction ventricular arrhythmias originating in papillary muscles.

Bogun F, Desjardins B, Crawford T, Good E, Jongnarangsin K, Oral H, Chugh A, Pelosi F, Morady F.
J Am Coll Cardiol. 2008 May 6;51(18):1794-802.

Ventricular tachycardia originating from the posterior papillary muscle in the left ventricle: a distinct clinical syndrome.

Doppalapudi H, Yamada T, McElderry HT, Plumb VJ, Epstein AE, Kay GN.
Circ Arrhythm Electrophysiol. 2008 Apr;1(1):23-9.

Endovasküler yapılar :"dördüncü boyut"

Sol ventrikülde ''2 papiller kas''

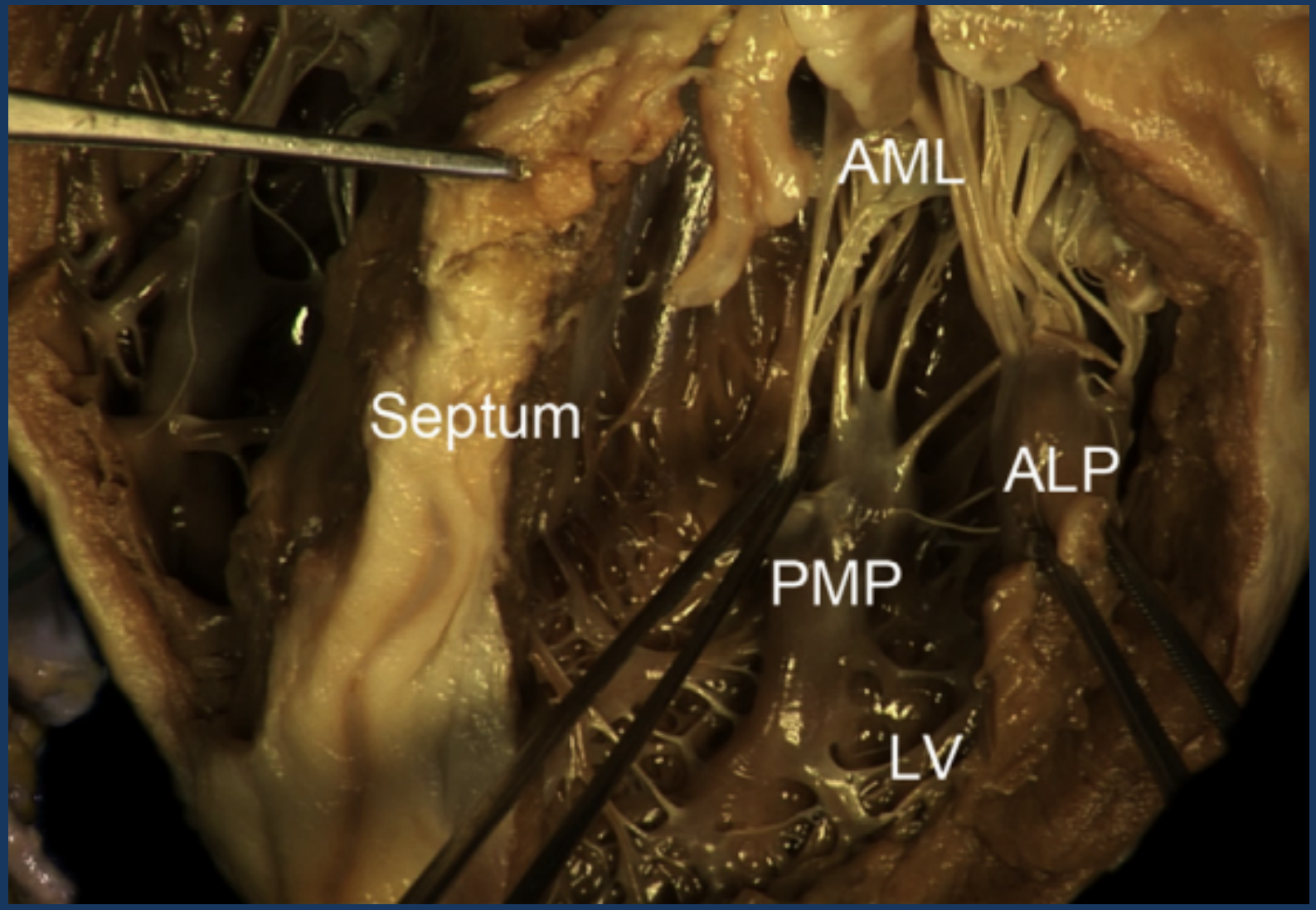

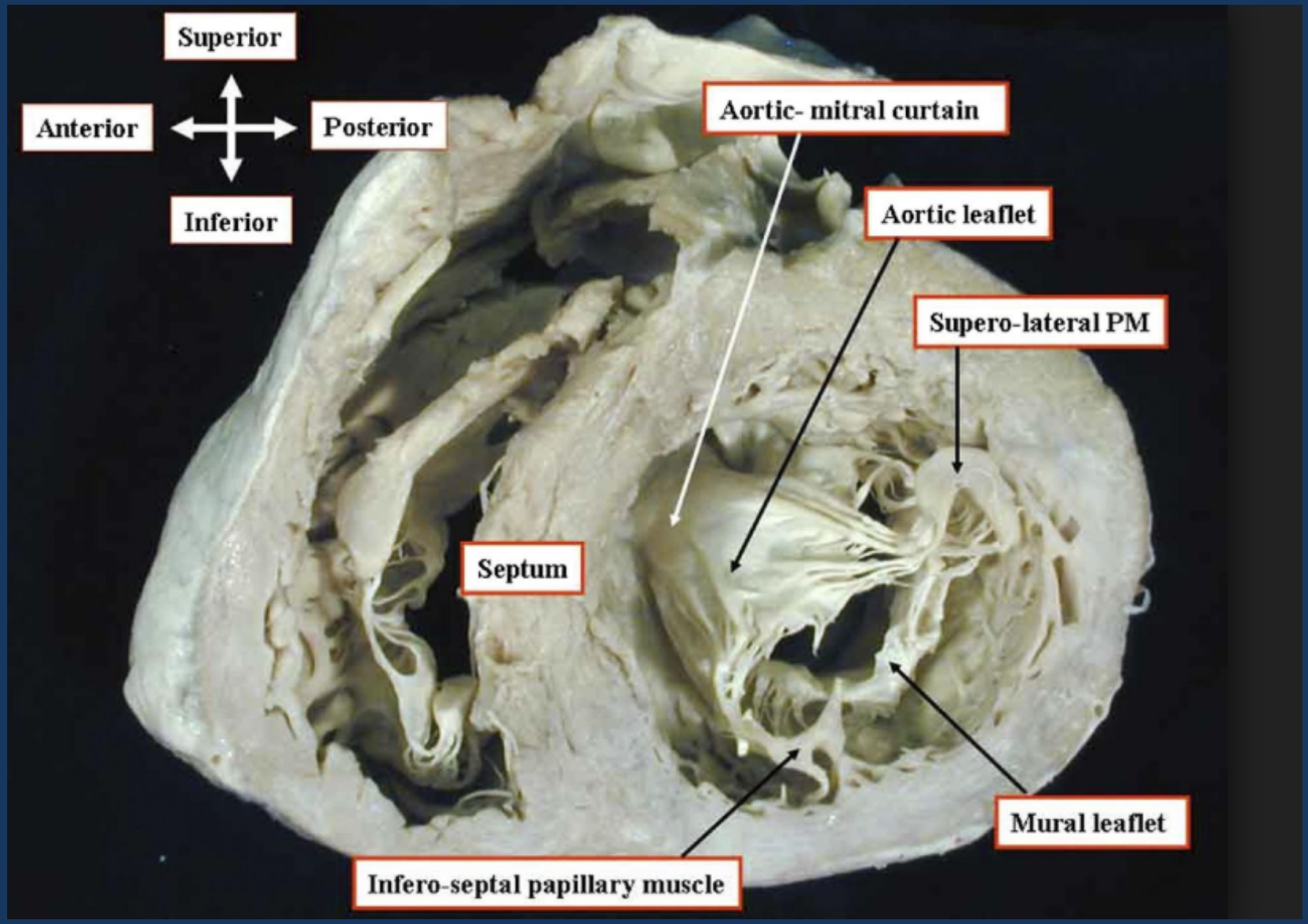
Superior
Anterior
Posterior
Inferior
Aortic- mitral curtain
Aortic leaflet
Supero-lateral PM
Septum
Mural leaflet
Infero-septal papillary muscle

Sağ ventrikülde ‘’3 papiller kas’’

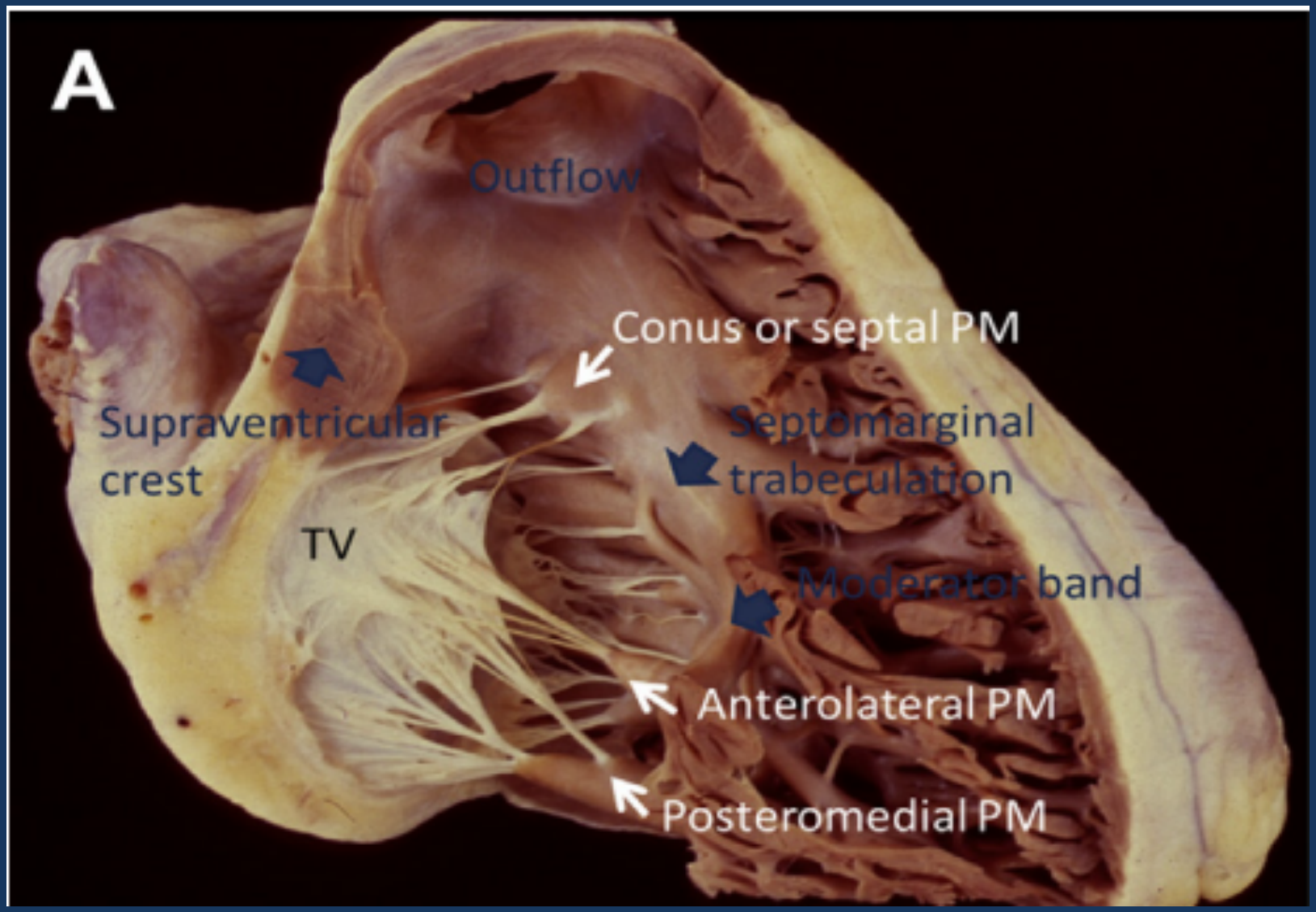

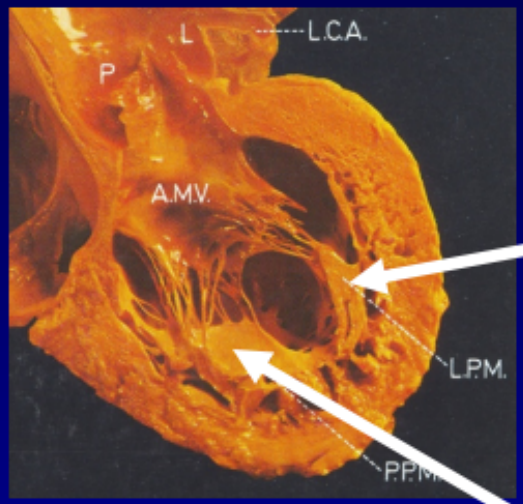

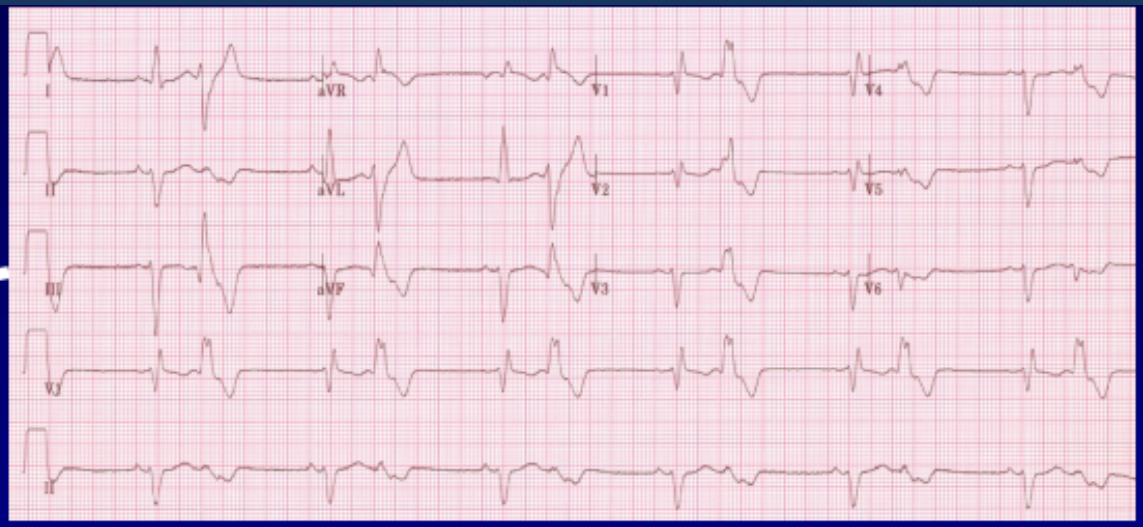

Anterolateral

Posterior

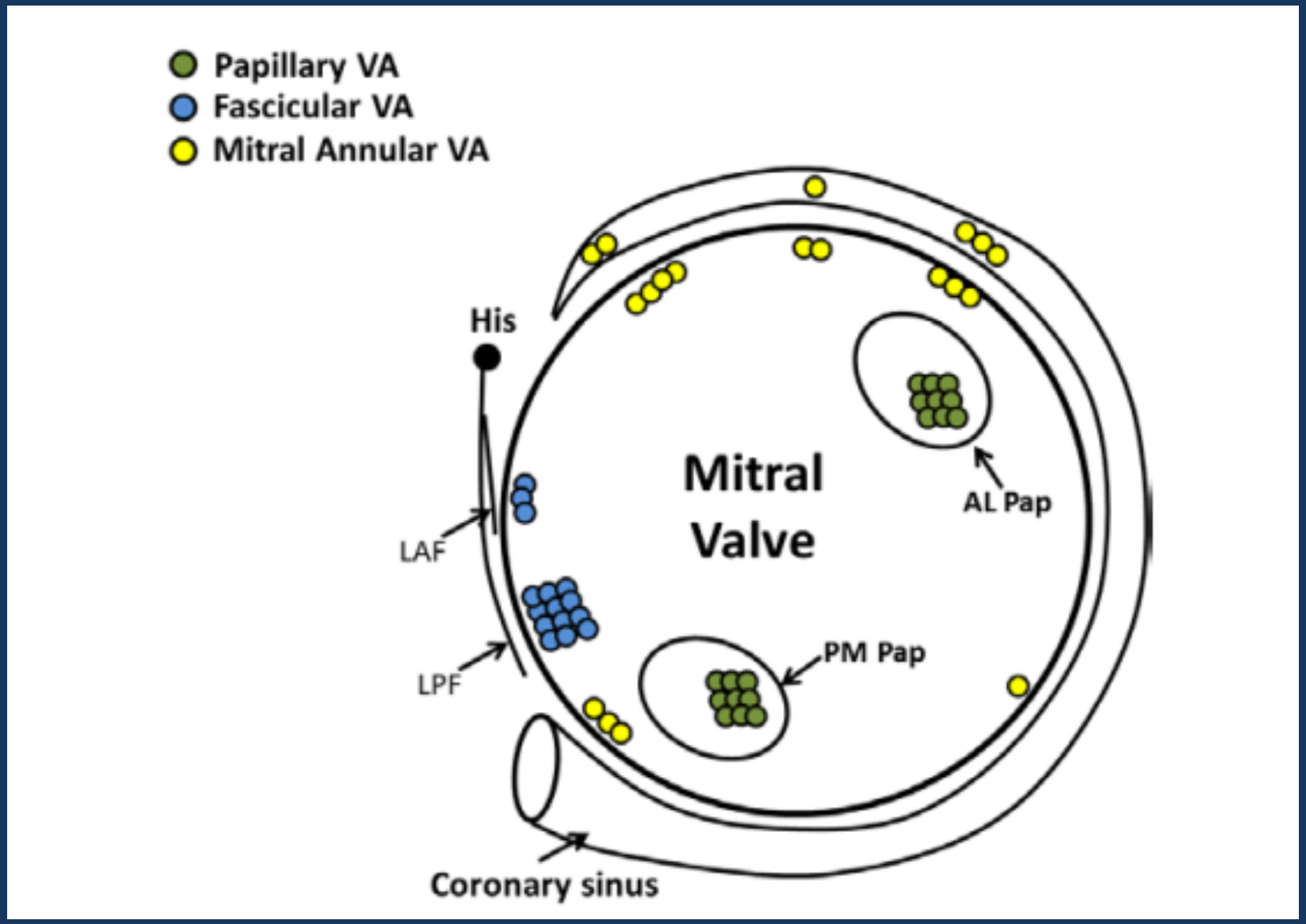
Papillary VA
Fascicular VA
Mitral Annular VA
His
Mitral Valve
AL Pap
LAF
LPF
PM Pap
Coronary sinus

Ventricular arrhythmias originating from a papillary muscle in patients without prior infarction: A comparison with fascicular arrhythmias

Eric Good, DO, Benoit Desjardins, MD, Krit Jongnarangsin, MD, Hakan Oral, MD, Aman Chugh, MD, Matthew Ebinger, DO, Frank Pelosi, MD, Fred Morady, MD, Frank Bogun, MD

From the University of Michigan Medical Center, Ann Arbor, Michigan.

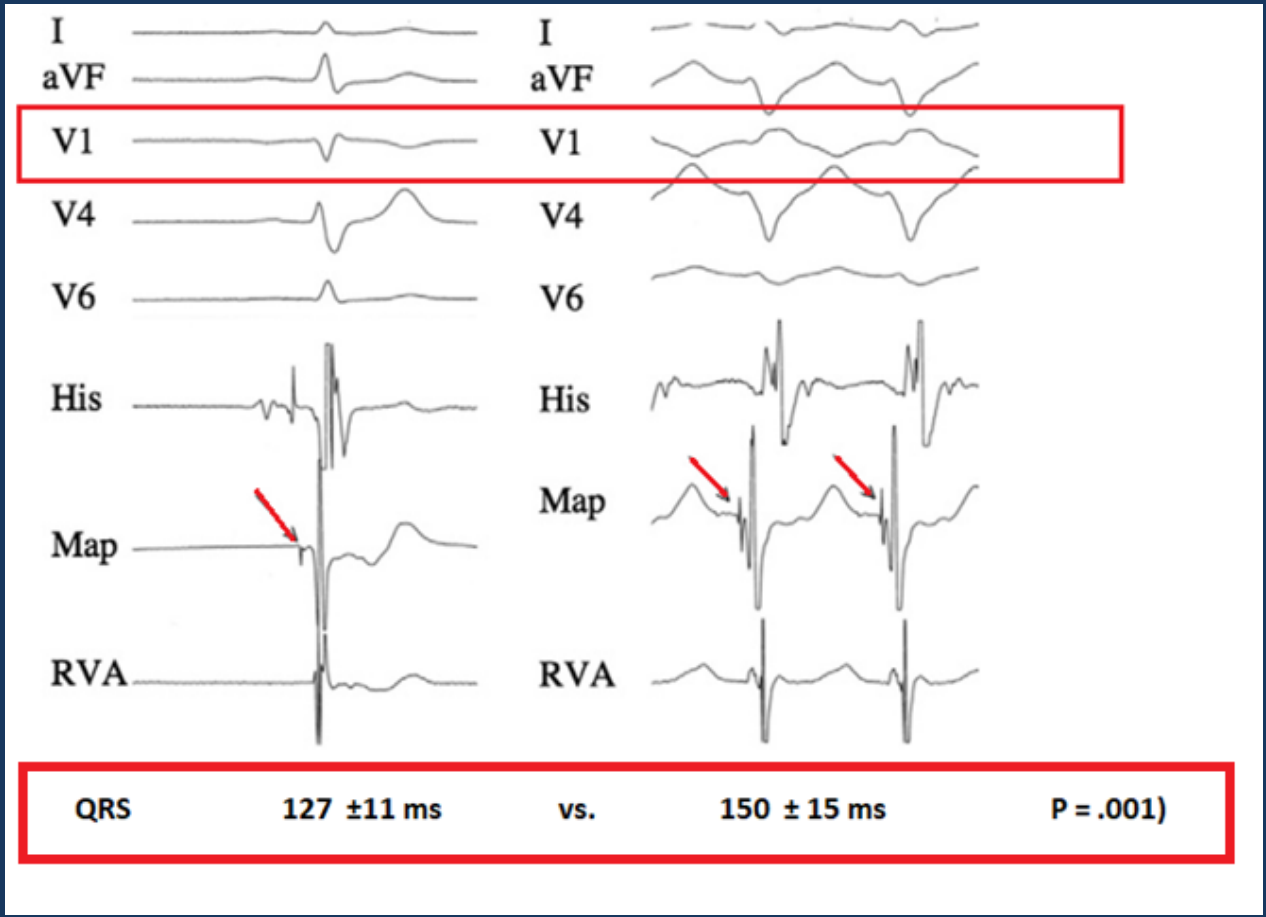

doi:10.1016/j.hrthm.2008.08.032

ECG (per arrhythmia)			
RB SA	6/8	9/11	.9
RB IA	2/8	2/11	.9
Axis RBSA (°)	−87 ± 16	−76 ± 31	.4
Axis RBIA (°)	135 ± 21	120 ± 0	.4
rsR′ pattern in V1	8/8	0/11	<.0001
Q in limb leads	8/8	1/11	.0001
Notches in precordial leads	4/8	7/11	.9

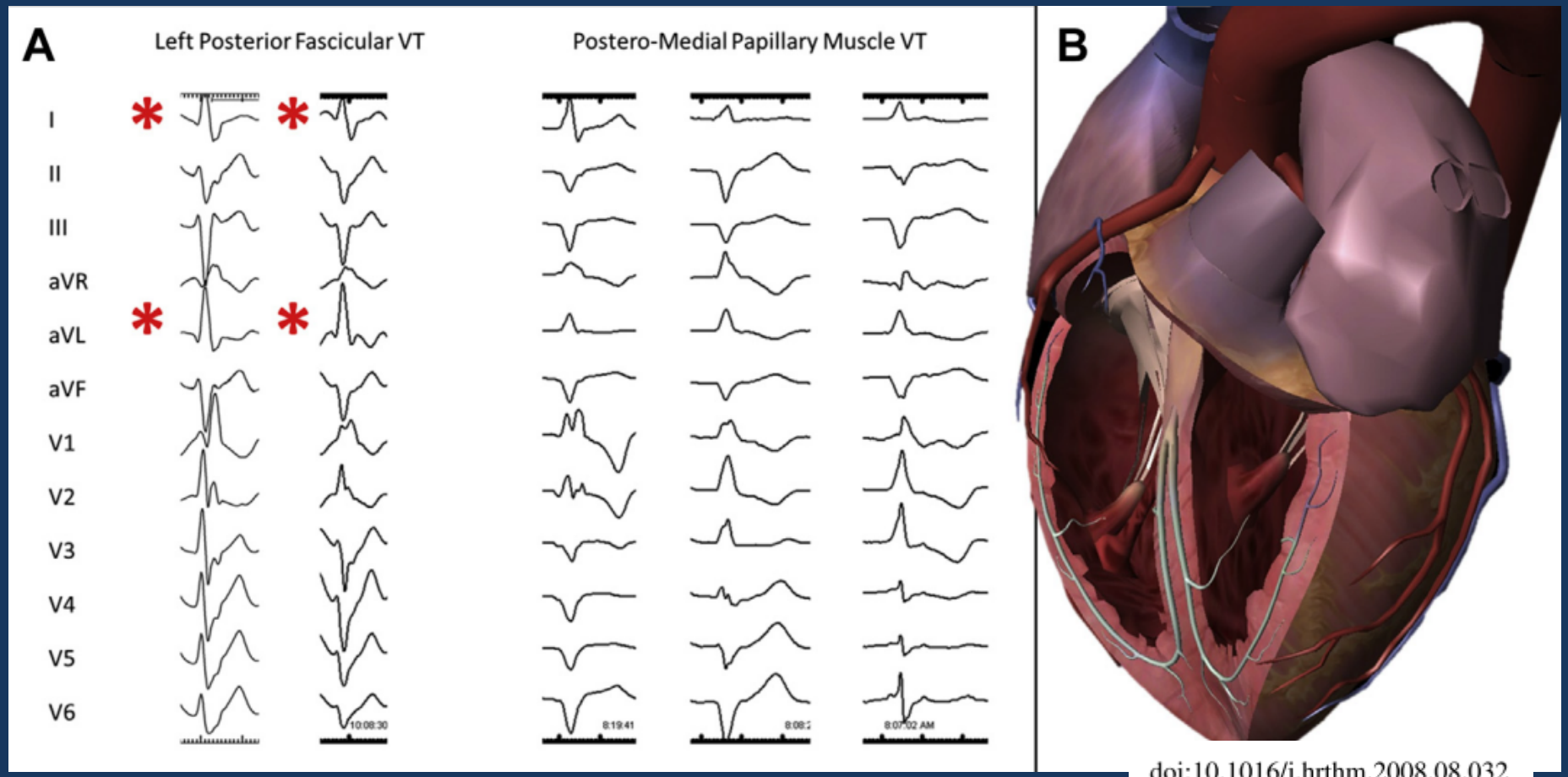

doi:10.1016/j.hrthm.2008.08.032

http://dx.doi.org/10.1016/j.ccep.2016.04.005

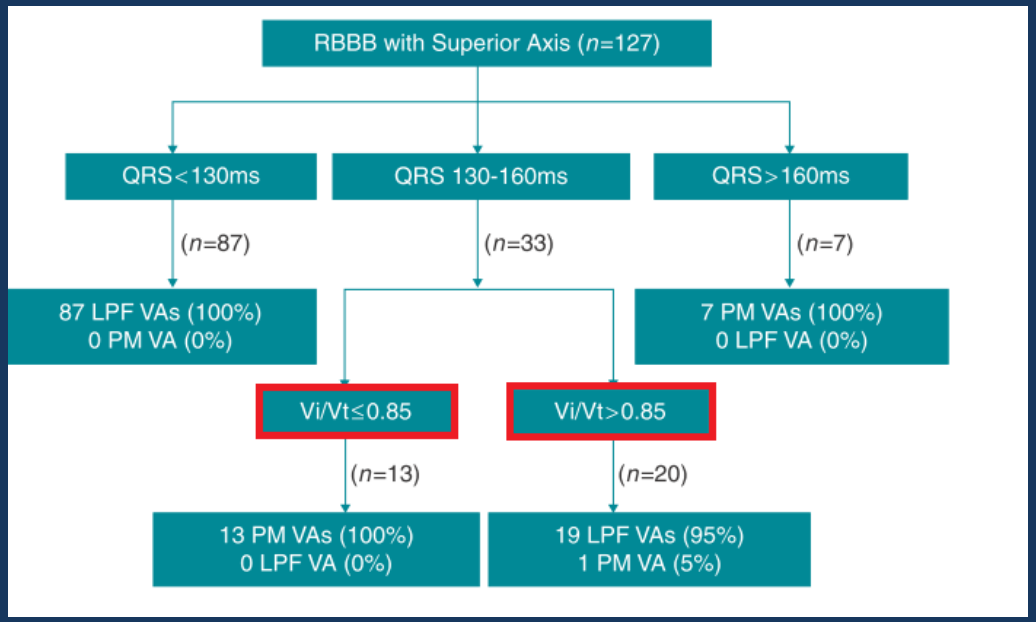

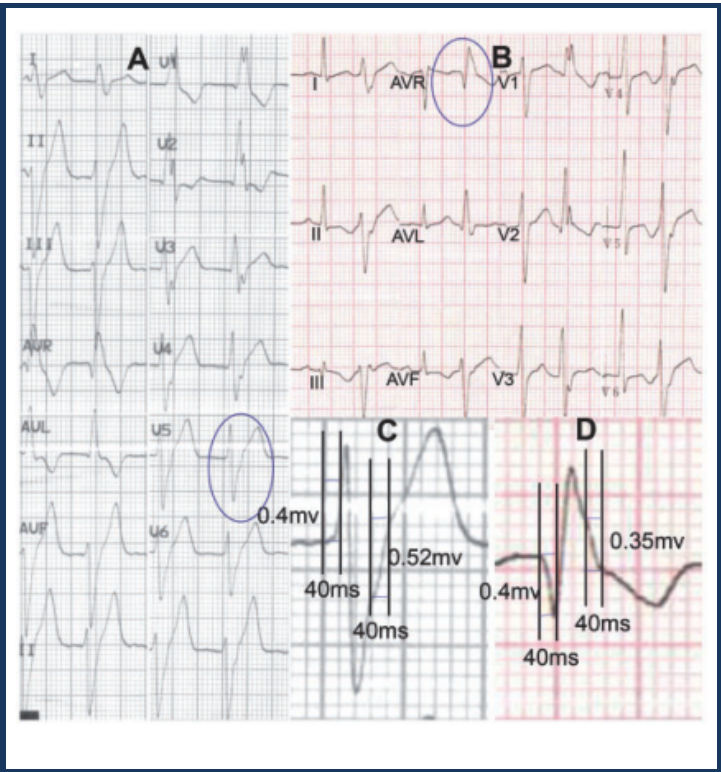

doi:10.1093/europace/eux071

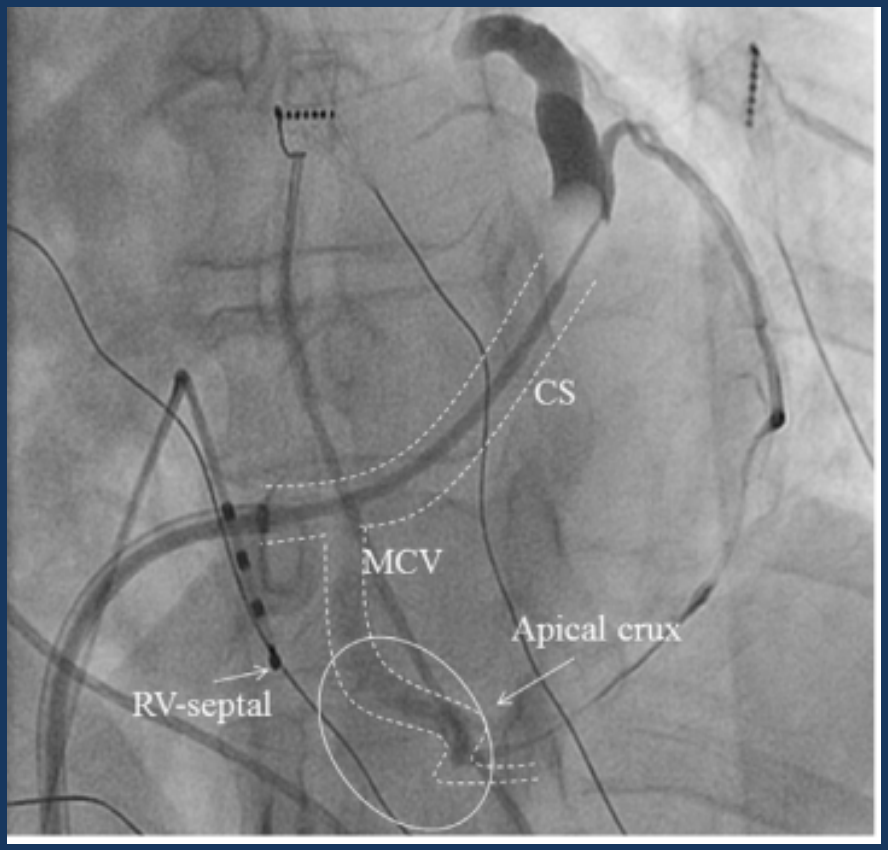
CS
MCV
Apical crux
RV-septal

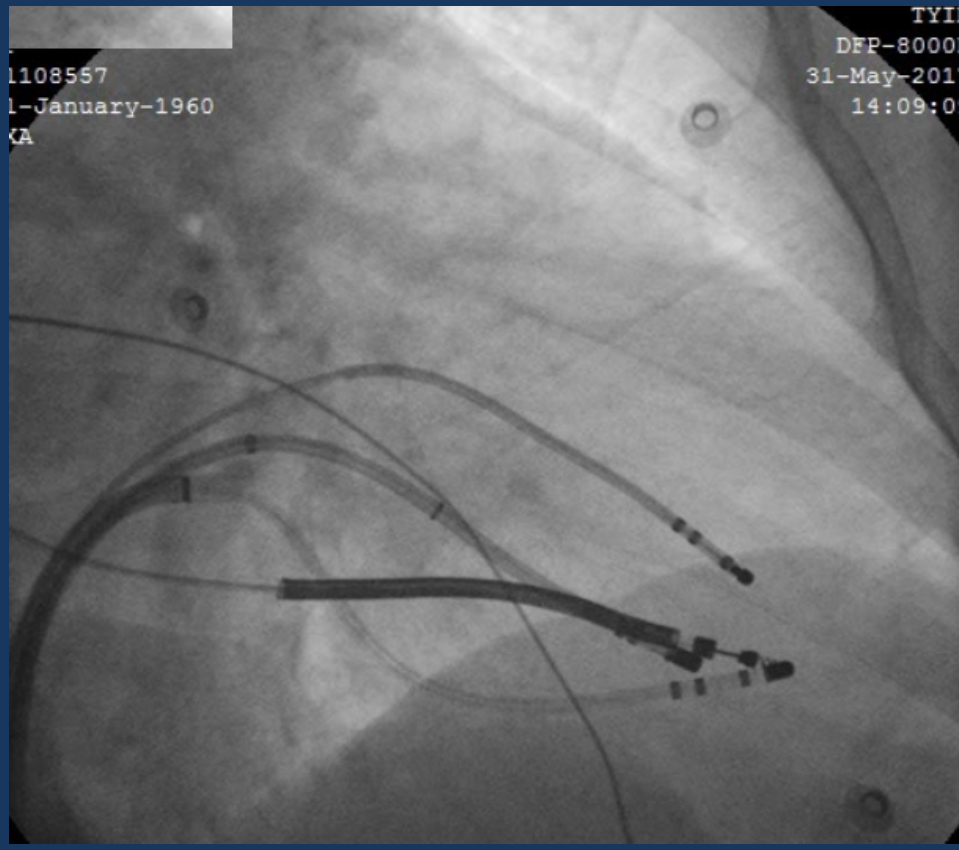
1108557
1-January-1960
XA
DFP-8000
31-May-201
14:09:0

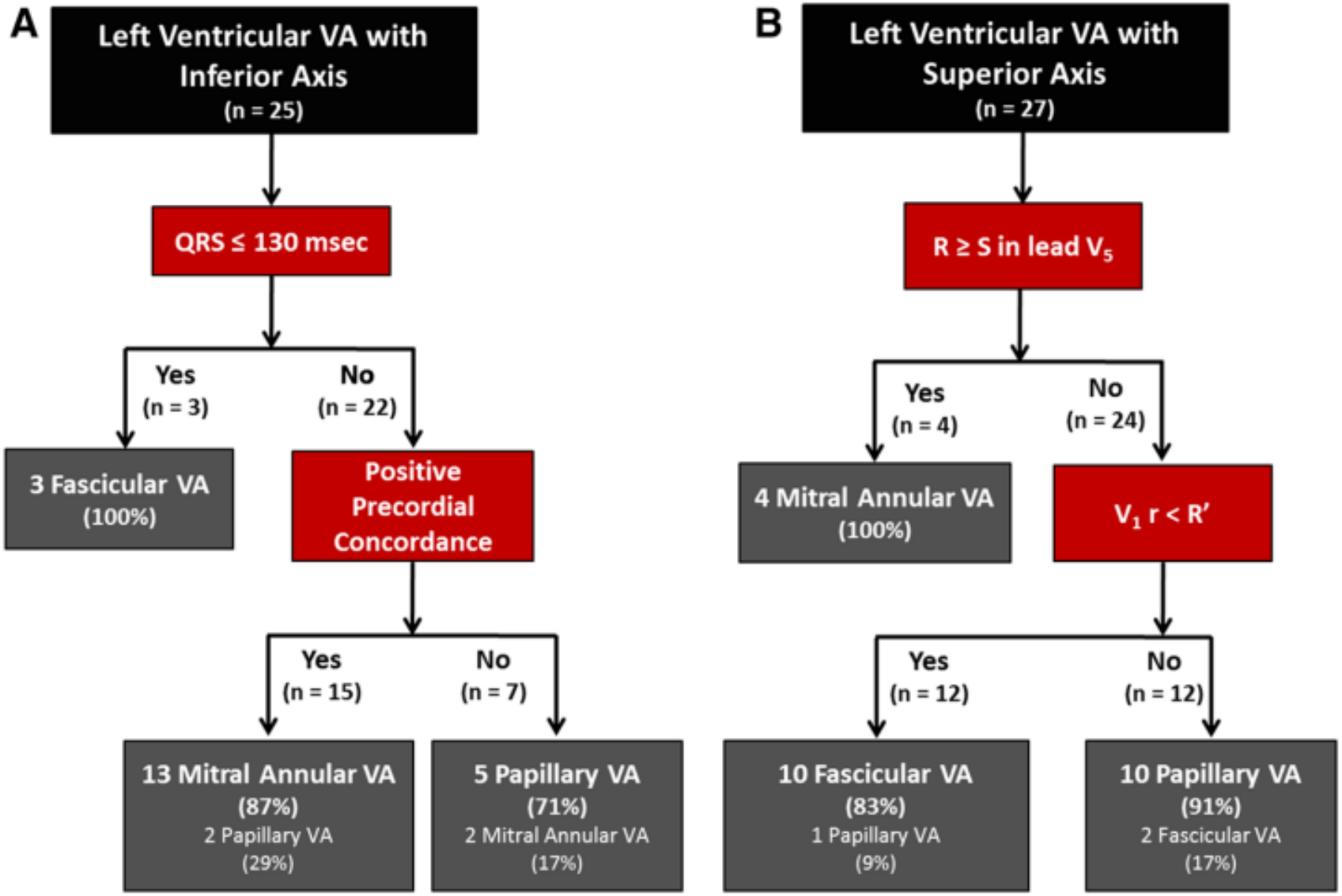

DOI: 10.1161/CIRCEP.114.002619

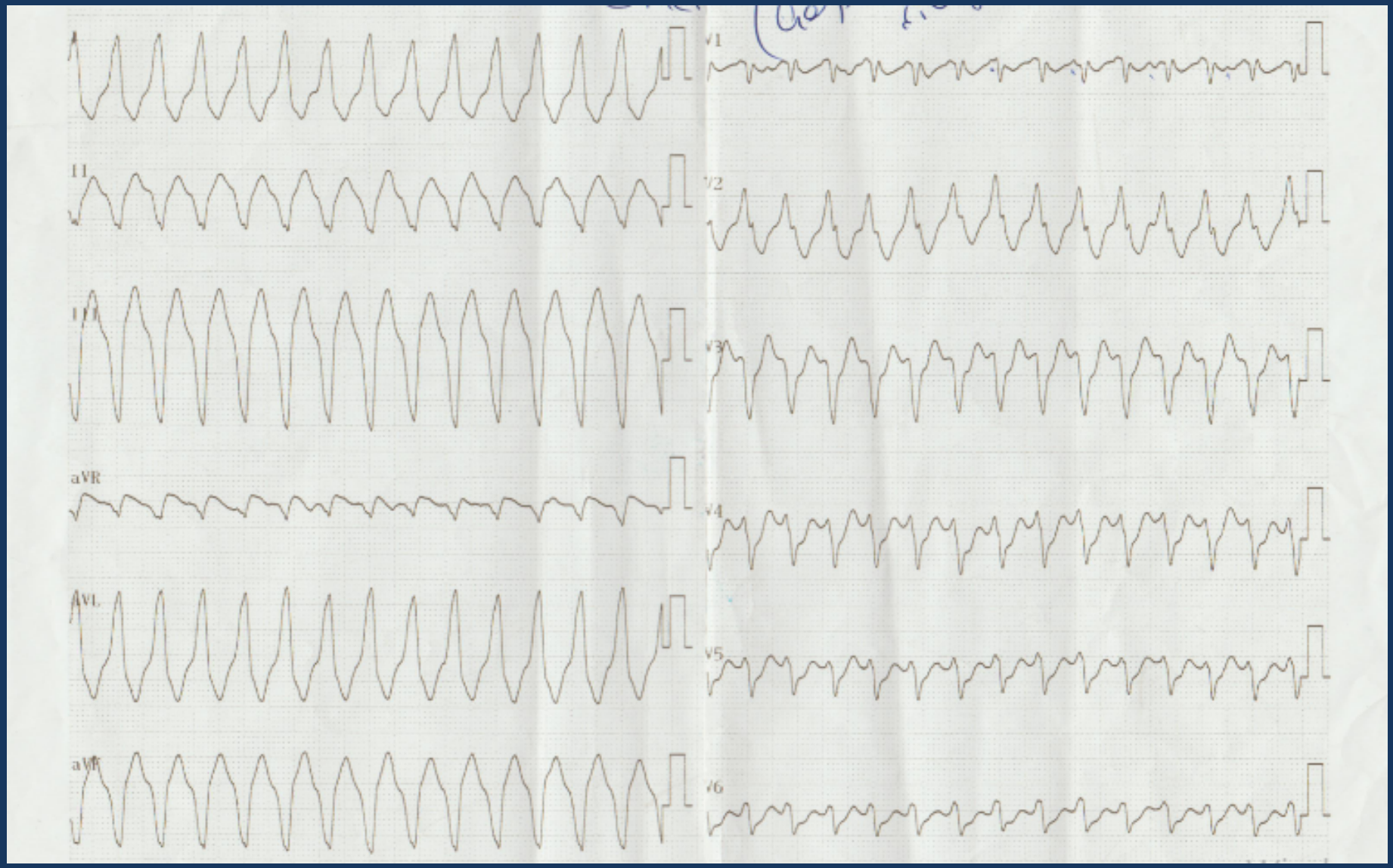
I
II
III
aVR
aVL
aVF
V1
V2
V3
V4
V5
V6

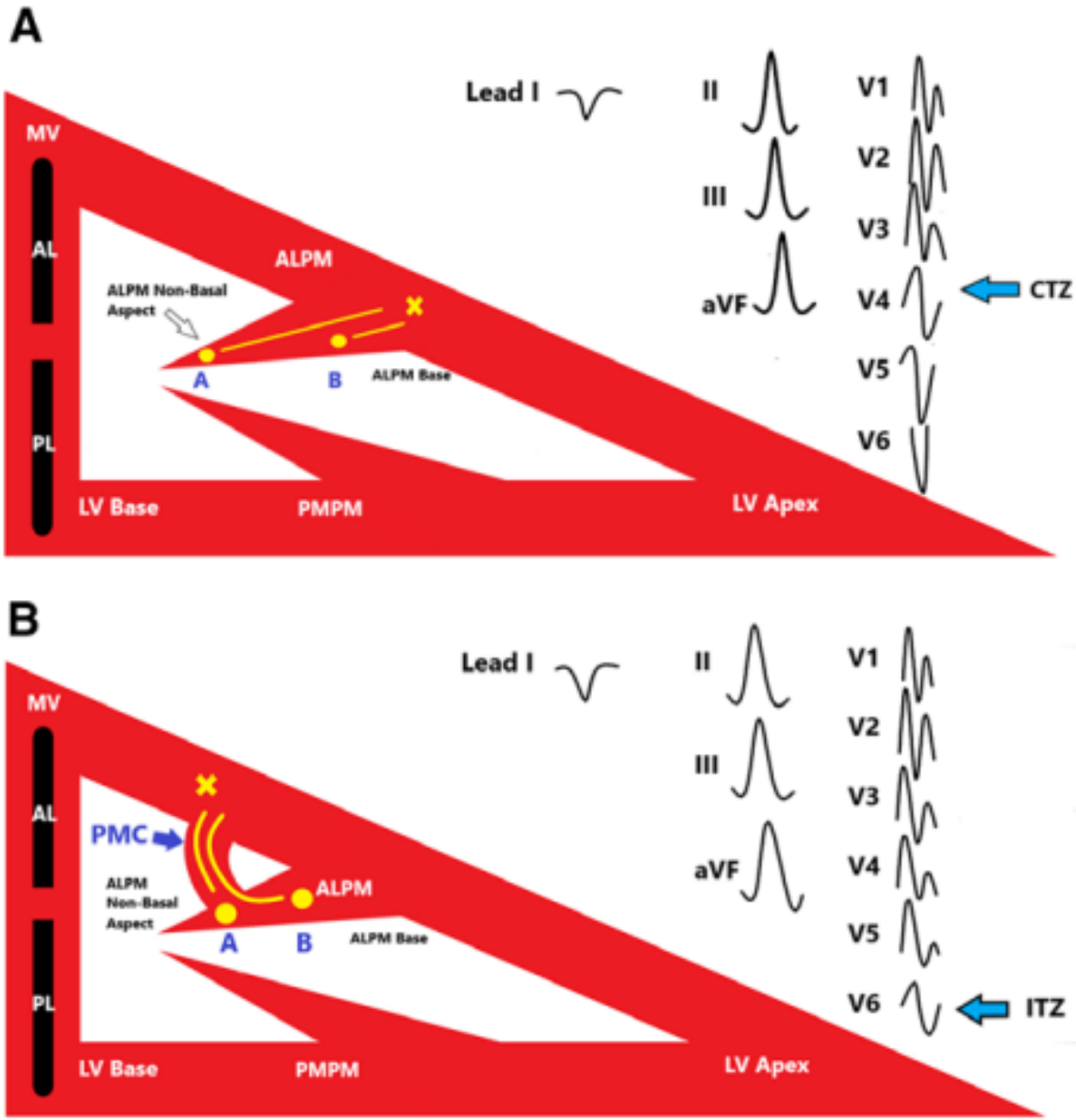
A
Lead I
II
III
aVF
V1
V2
V3
V4
V5
V6
CTZ
MV
AL
PL
ALPM
ALPM Non-Basal Aspect
A
B
ALPM Base
LV Base
PMPM
LV Apex
B
Lead I
II
III
aVF
V1
V2
V3
V4
V5
V6
ITZ
MV
AL
PL
PMC
ALPM
ALPM Non-Basal Aspect
A
B
ALPM Base
LV Base
PMPM
LV Apex

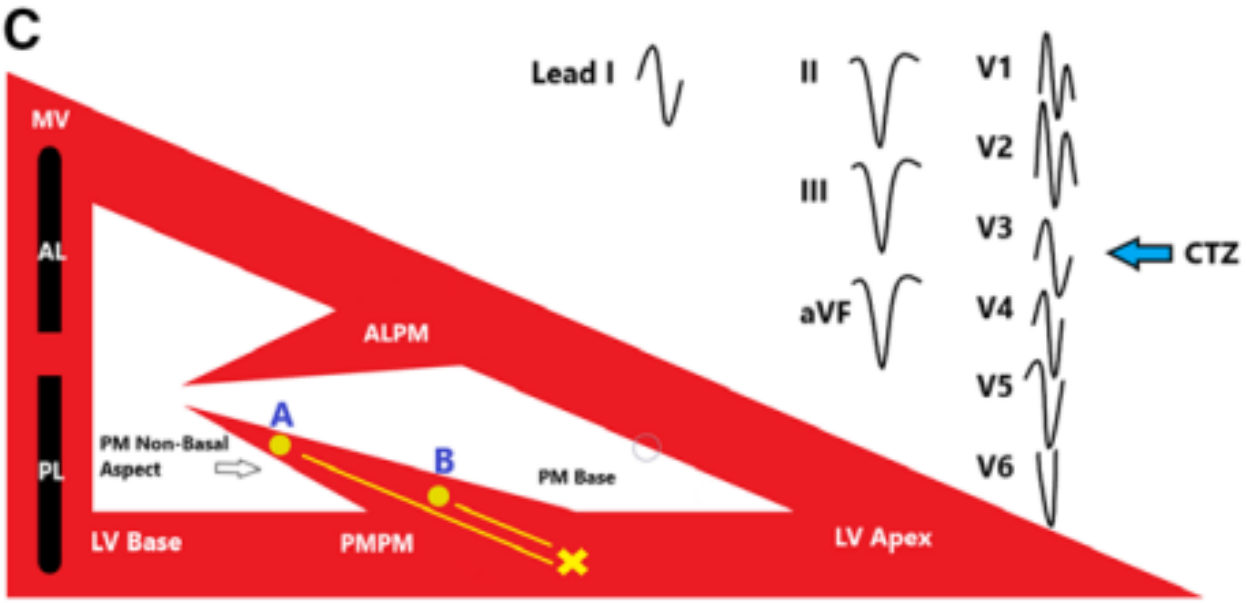
C
Lead I
II
III
aVF
V1
V2
V3
V4
V5
V6
CTZ
MV
AL
PL
ALPM
A
B
PM Non-Basal Aspect
PM Base
LV Base
PMPM
LV Apex

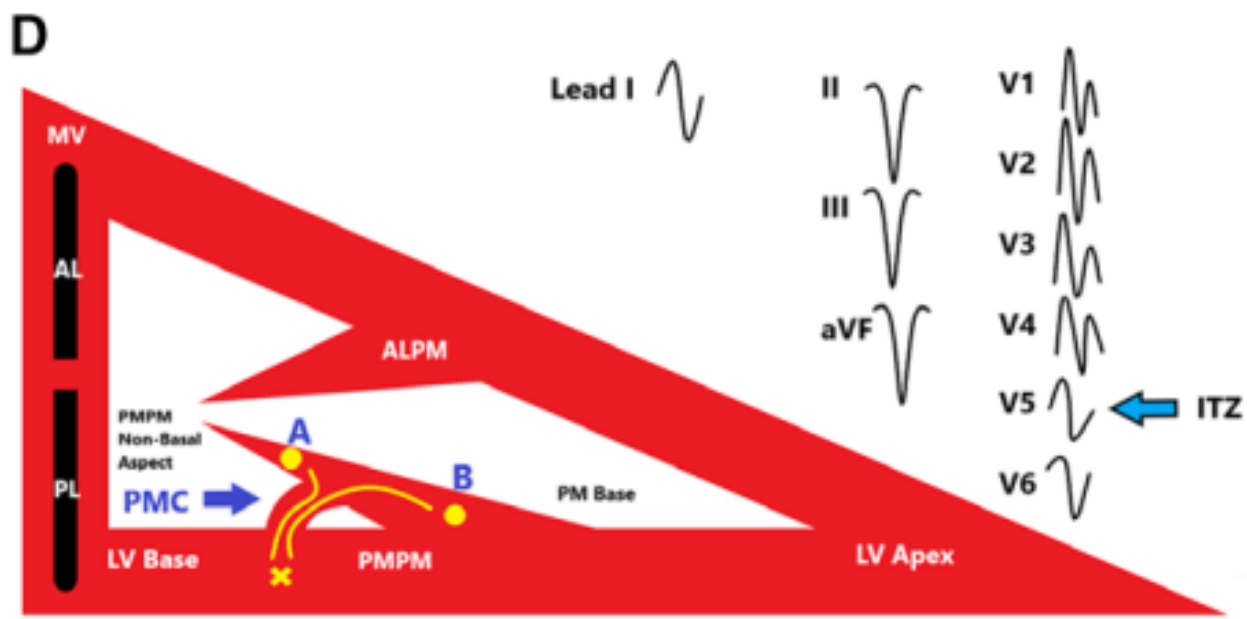
D
Lead I
II
III
aVF
V1
V2
V3
V4
V5
V6
ITZ
MV
AL
PL
ALPM
PMPM Non-Basal Aspect
PMC
A
B
PM Base
LV Base
PMPM
LV Apex

Solda ‘’yalancı tendon’’

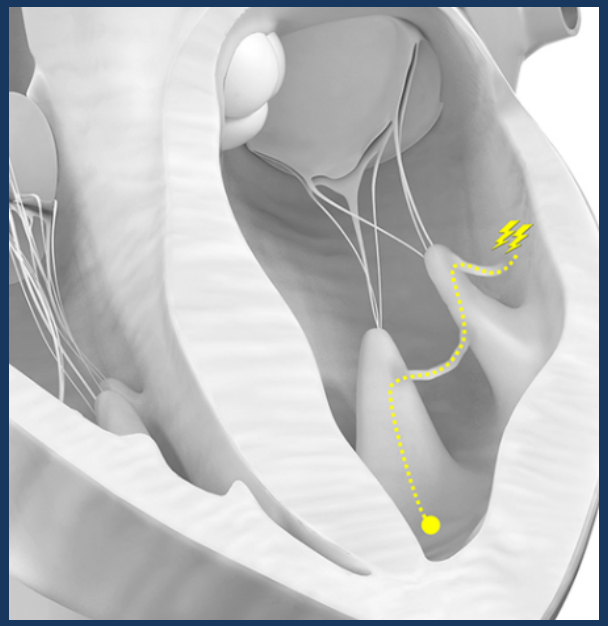

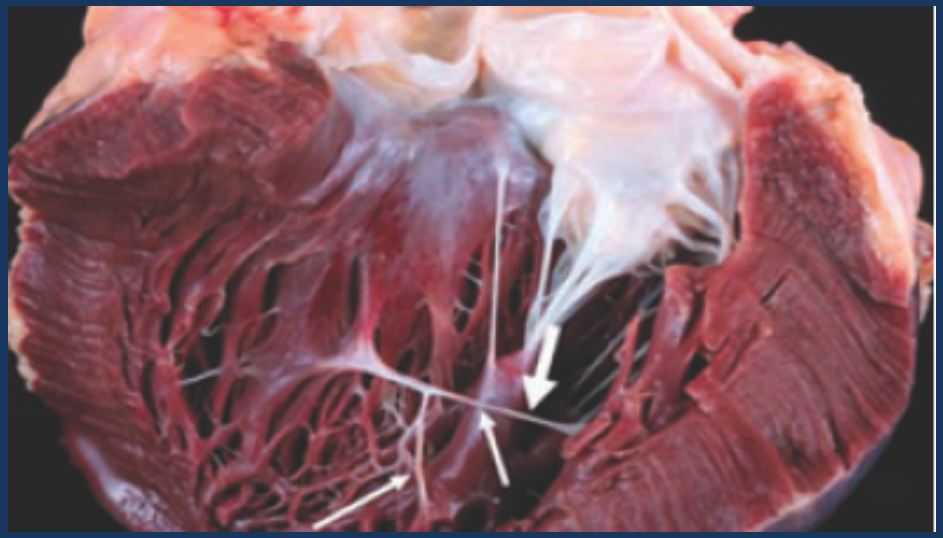

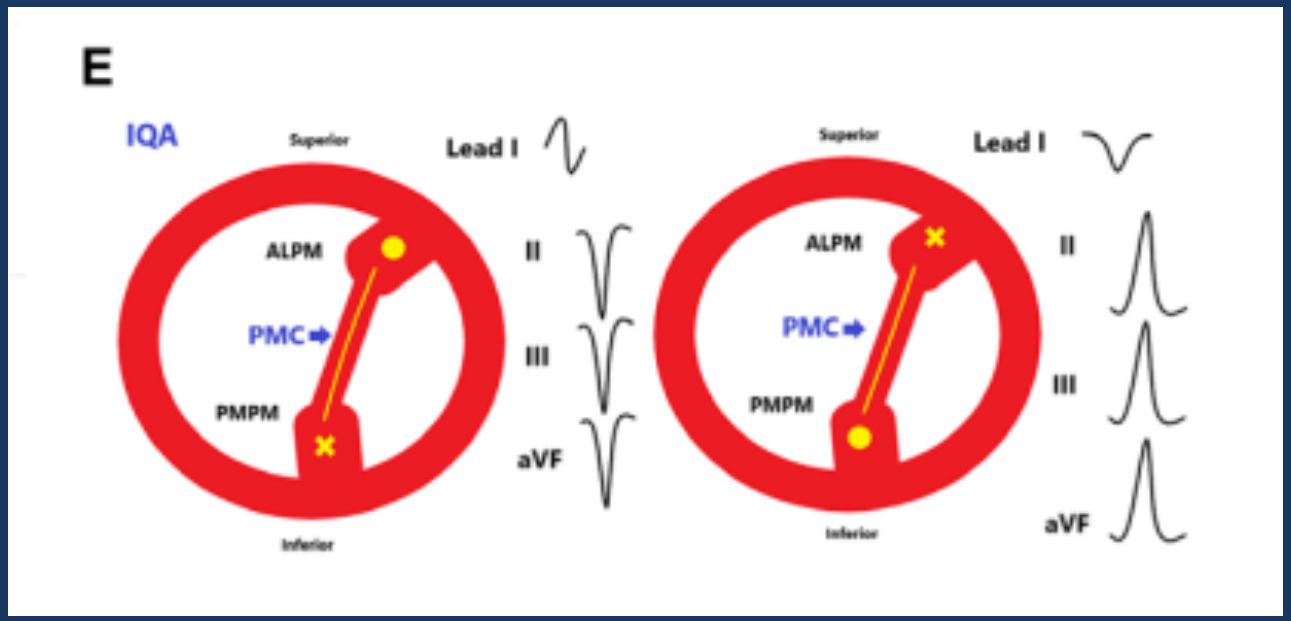

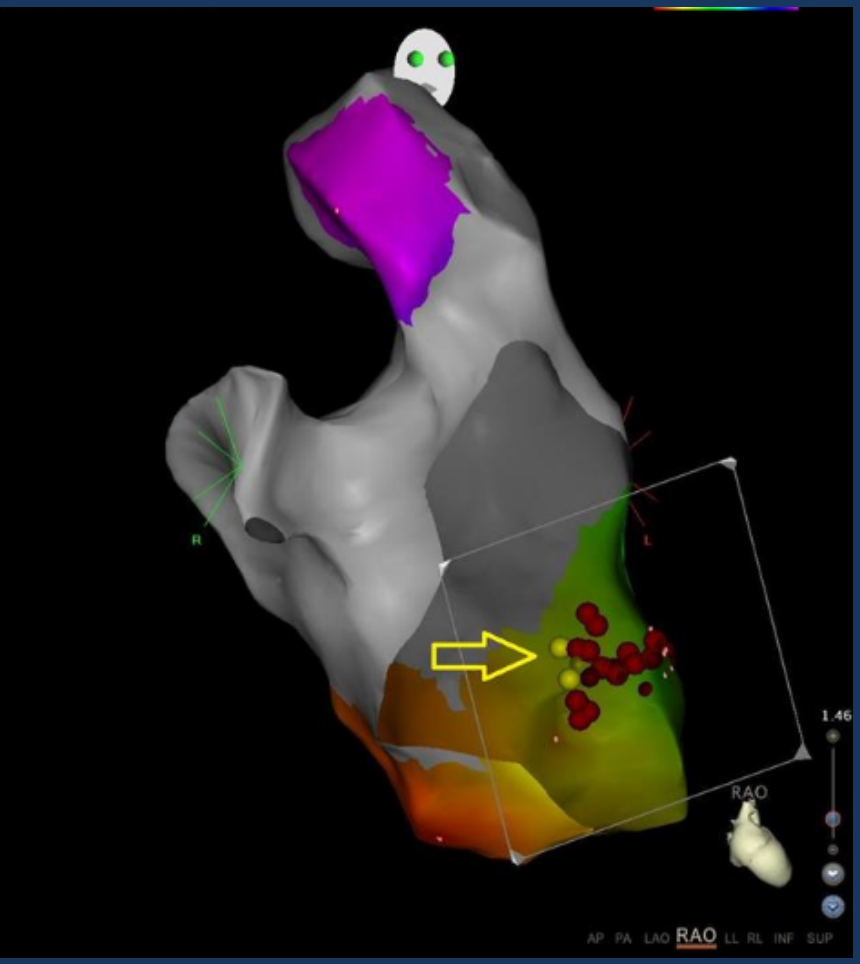
R
L
1.46
RAO
AP PA LAO RAO LL RL INF SUP


I
II
III
aVR
aVL
aVF
V1
V2
V3
V4
V5
V6
1
2
3

Sağda "moderatör band"

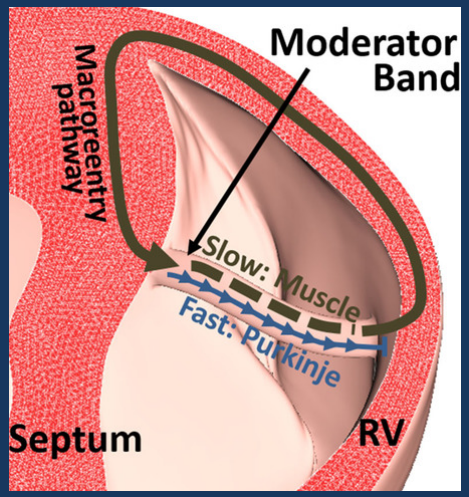

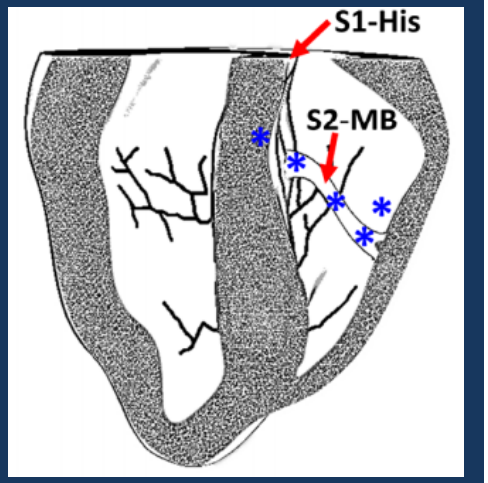

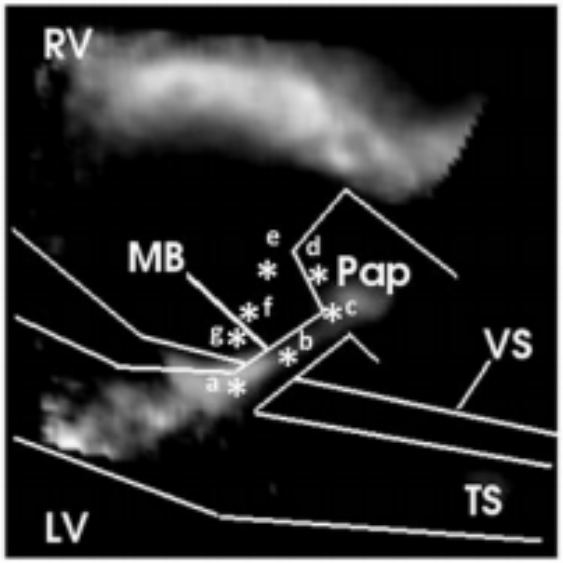

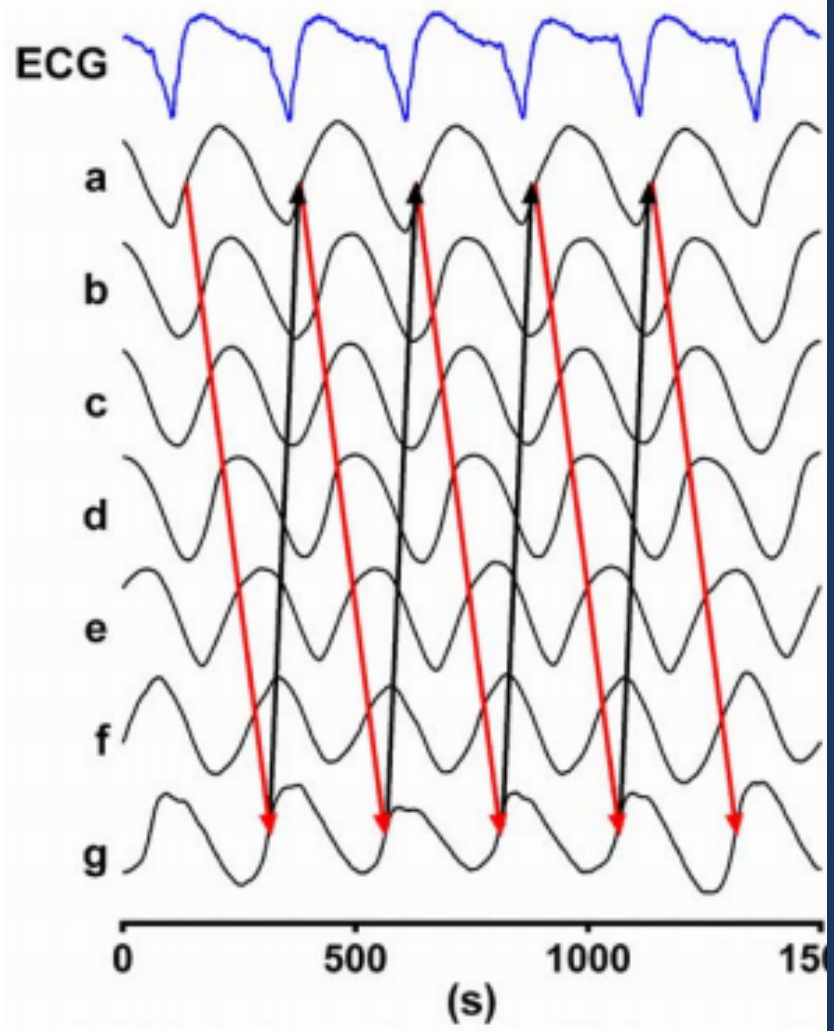

II/III inferior lead discordance

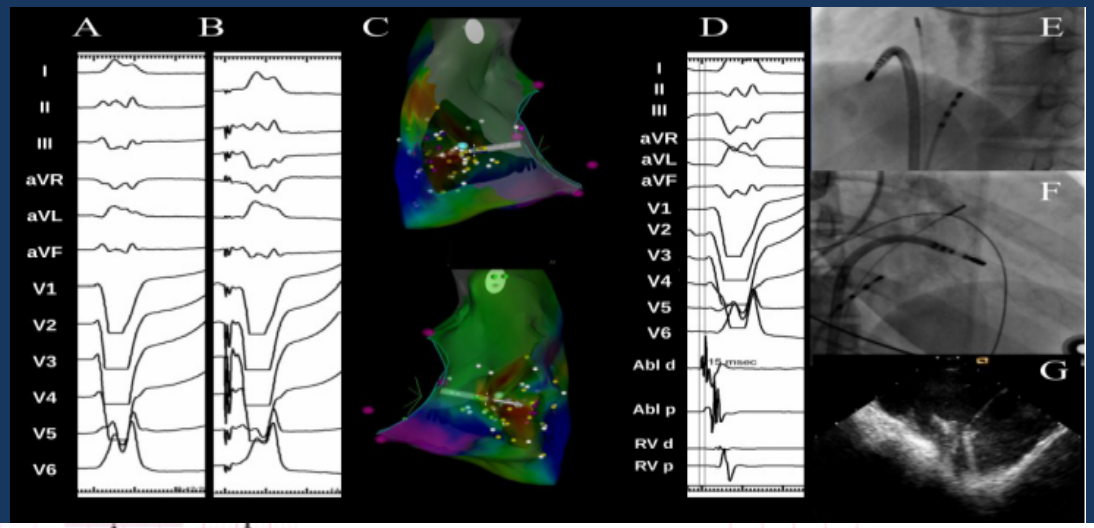

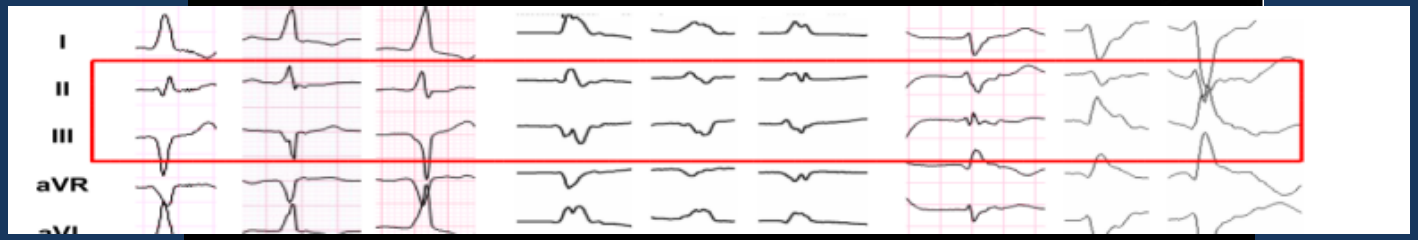

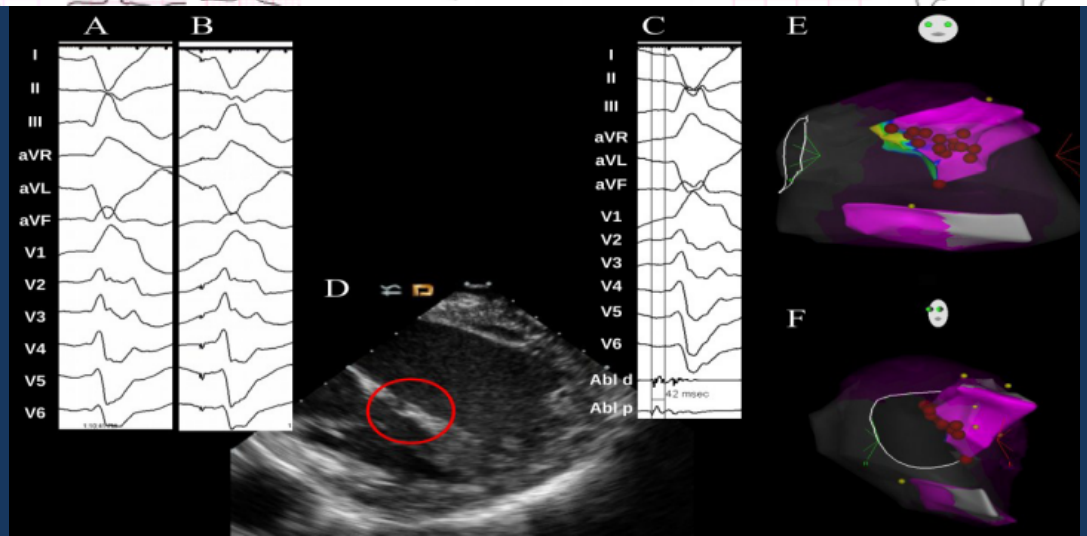

II/III Negatif/pozitif

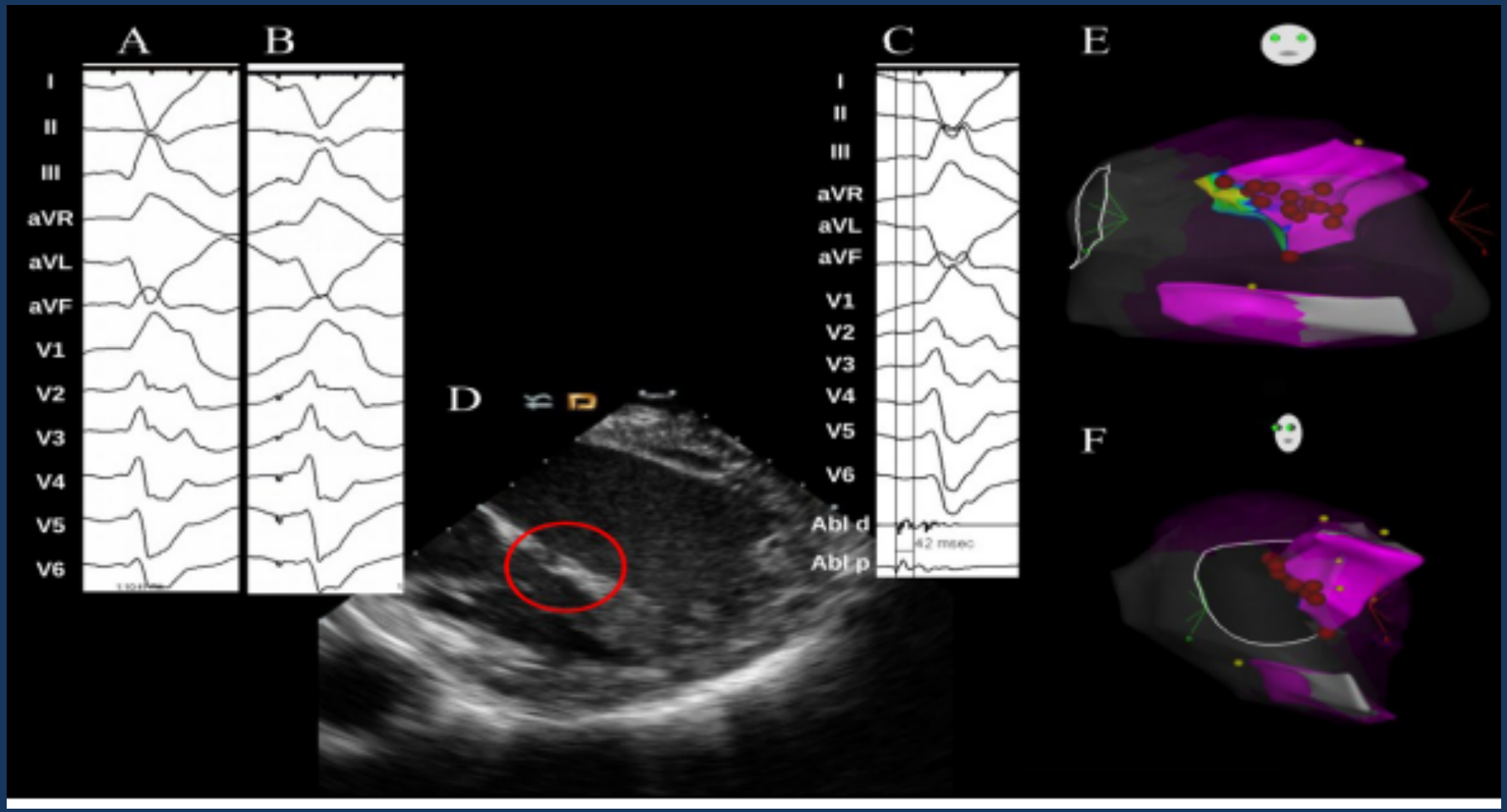

10.1111/jce.13287.

II/III Pozitif/negatif

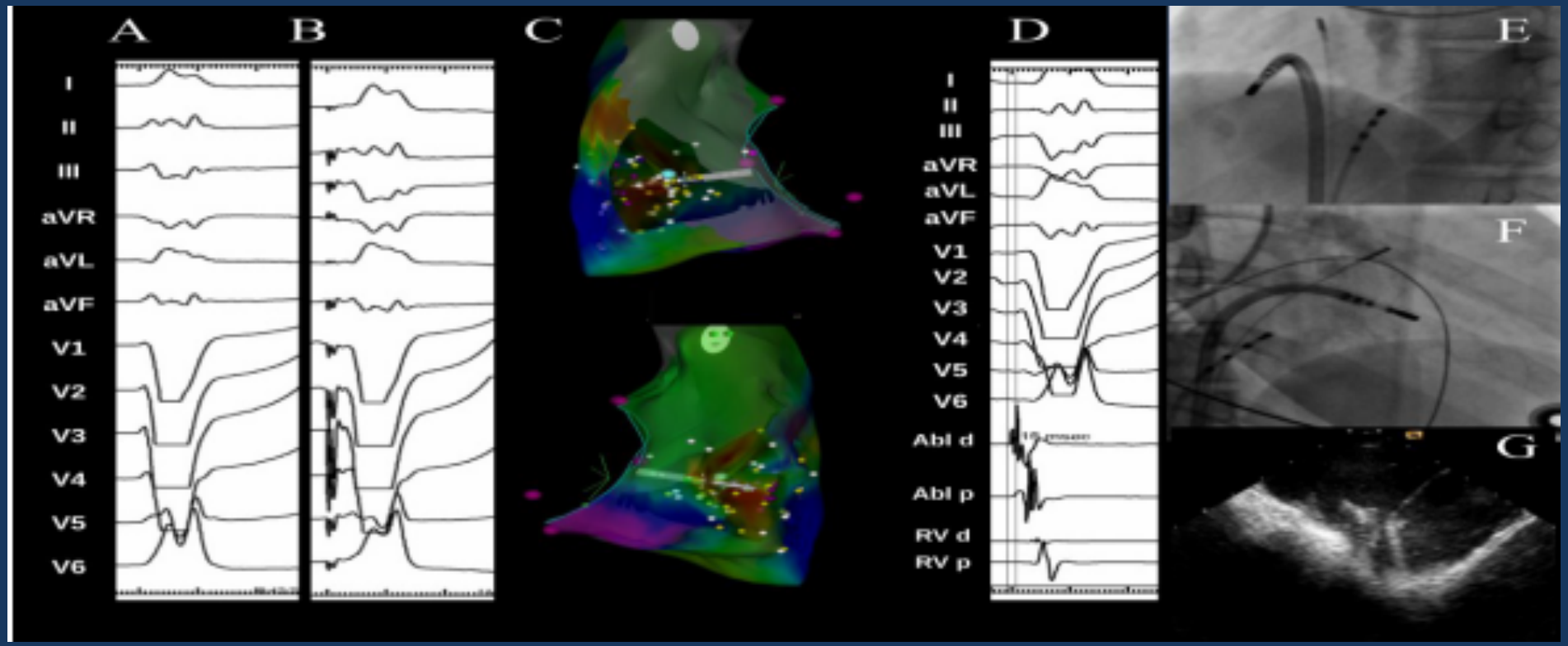

10.1111/jce.13287.

Catheter ablation of premature ventricular complexes arising from the left fascicular system

Jinlin Zhang, MD, Cheng Tang, MD, Yonghua Zhang, MD, Xi Su, MD

Fascicular Ventricular Tachycardia Originating From Papillary Muscles

Purkinje Network Involvement in the Reentrant Circuit

Yuki Komatsu, MD; Akihiko Nogami, MD; Kenji Kurosaki, MD; Itsuro Morishima, MD;


University of Minnesota/© Medtronic, Inc

the "cypress tree" papillary muscle root



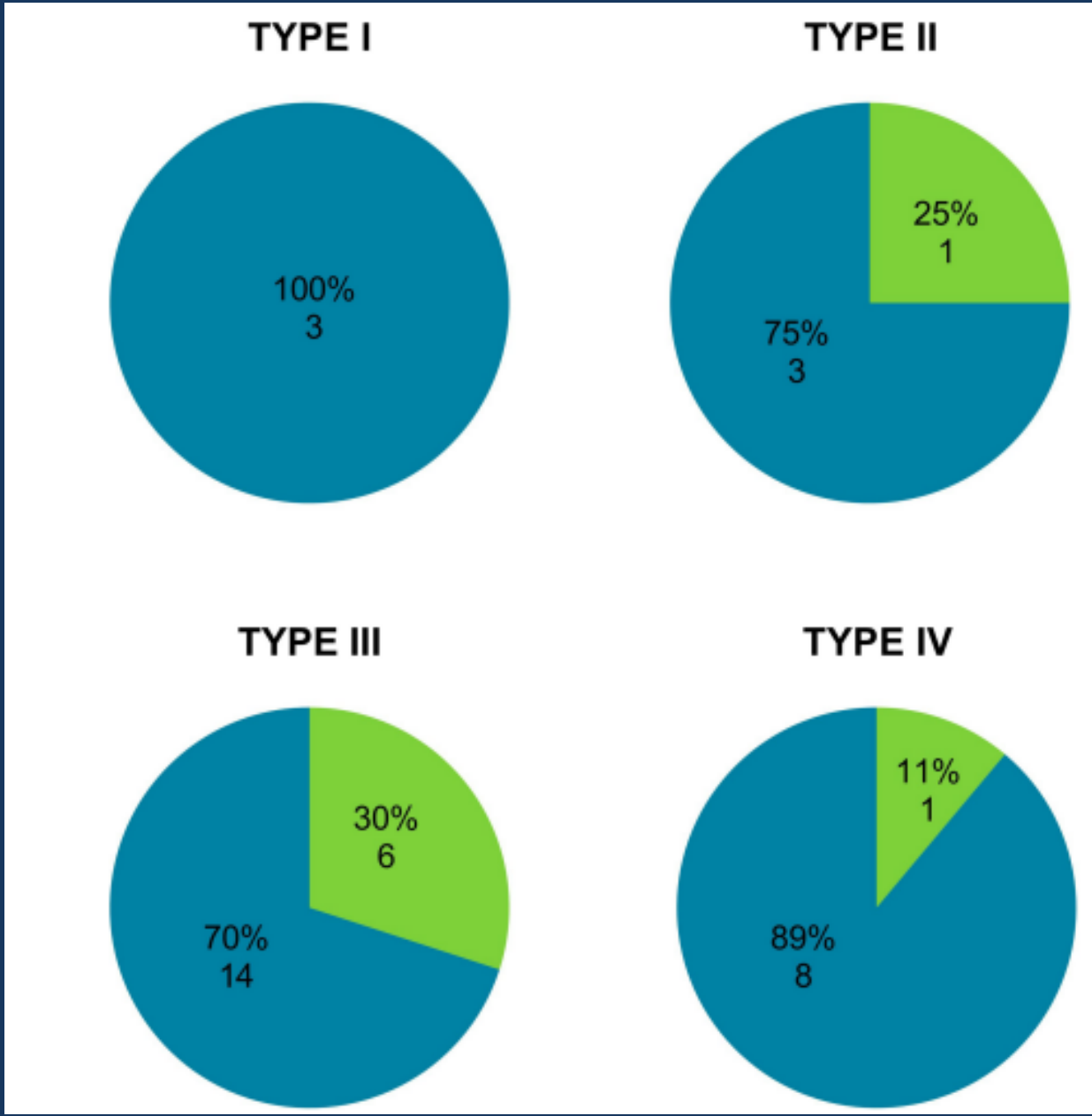

/10.1371/journal.pone.0205786

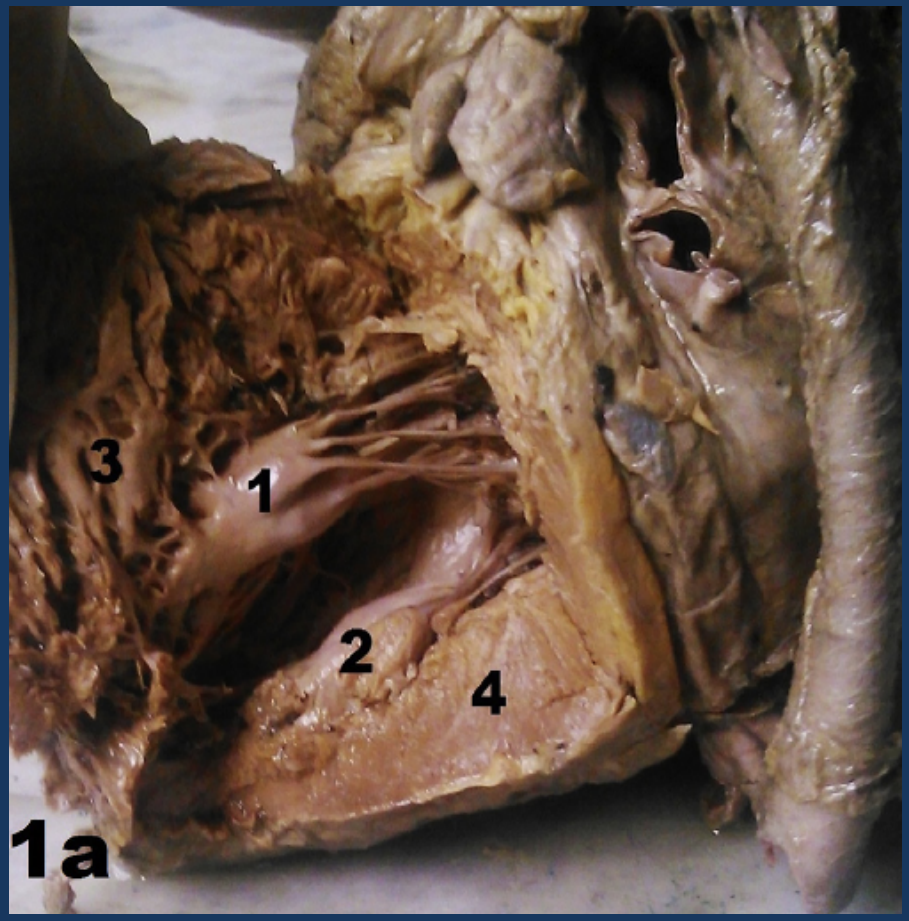

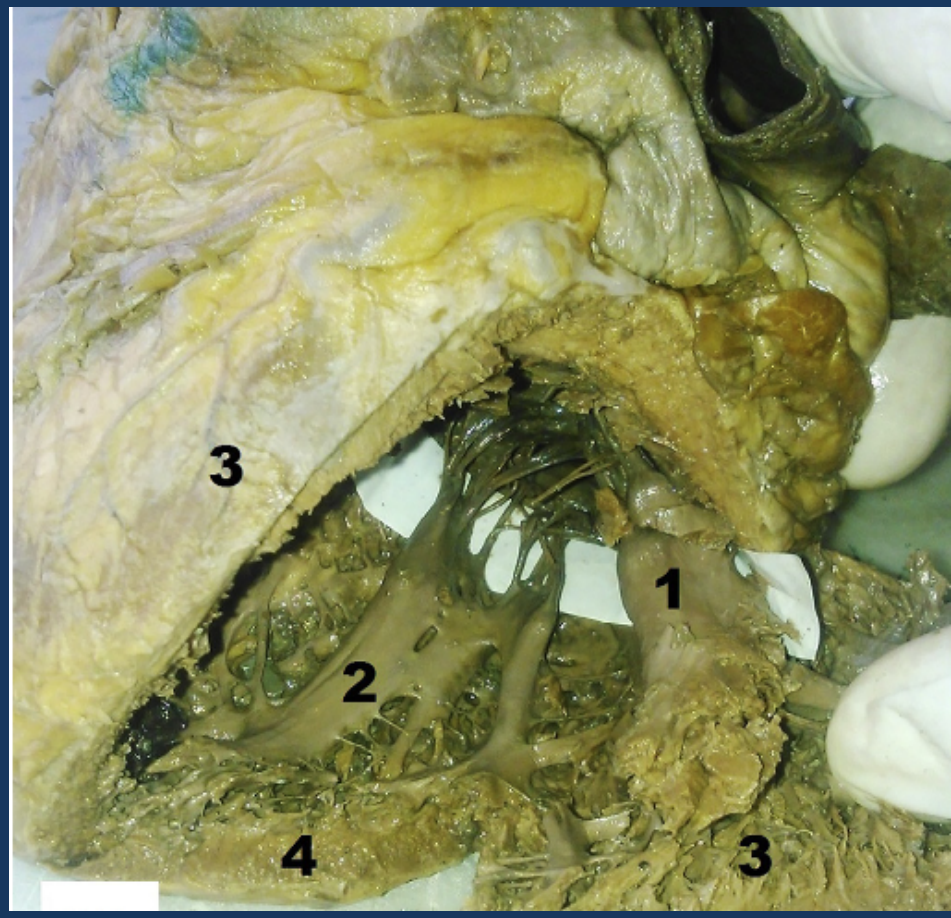

https://doi.org/10.1016/j.ihj.2017.12.003

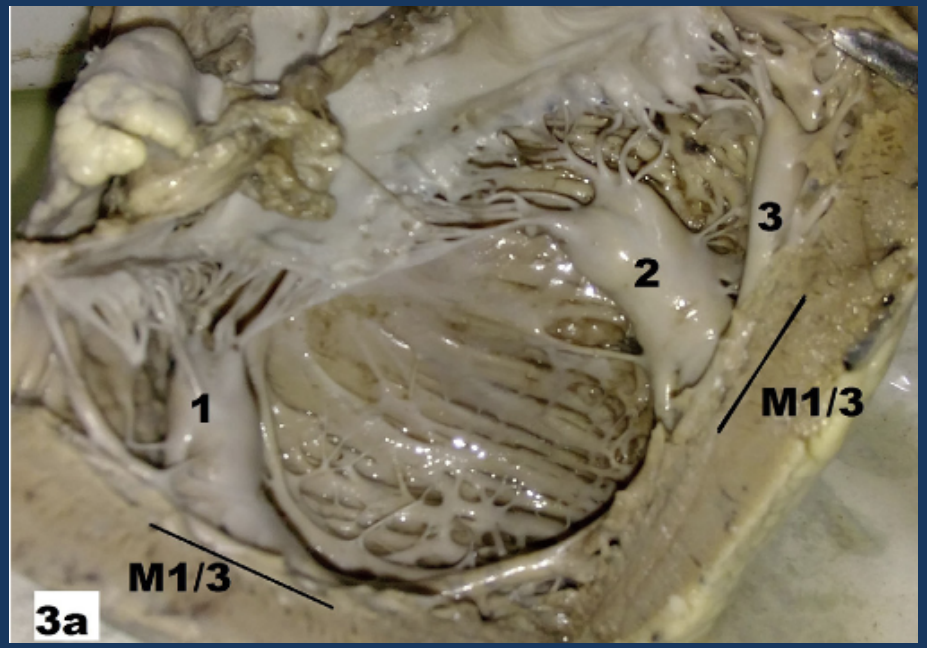

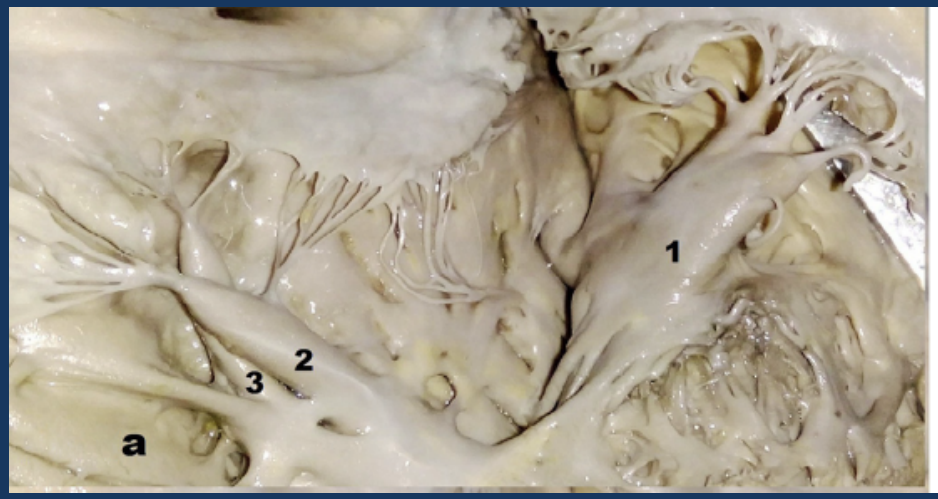

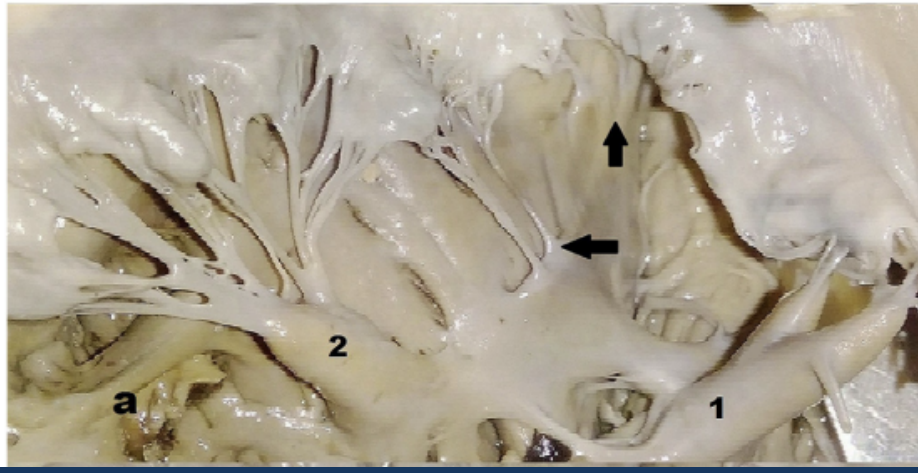

https://doi.org/10.1016/j.ihj.2017.12.003

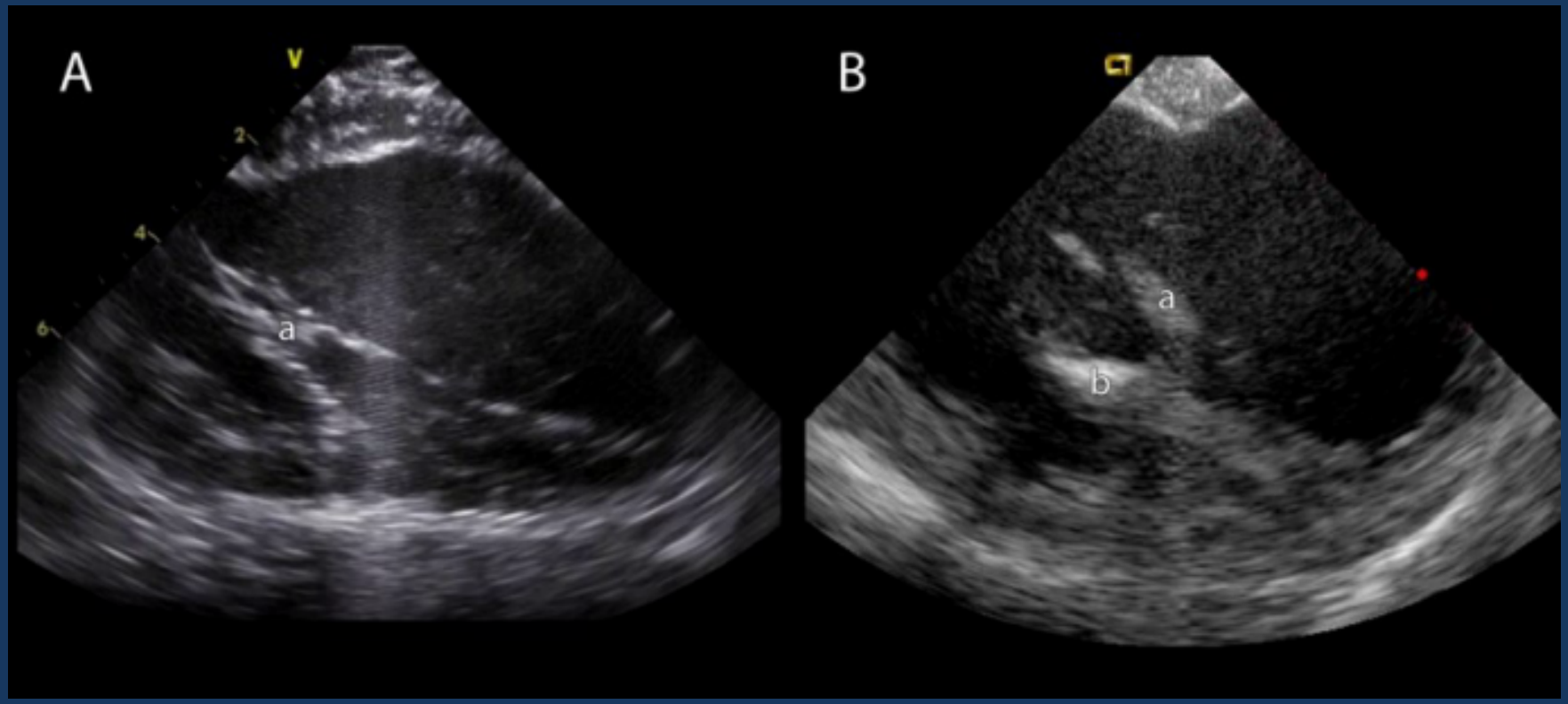
A
V
2
4
6
a
B
a
b

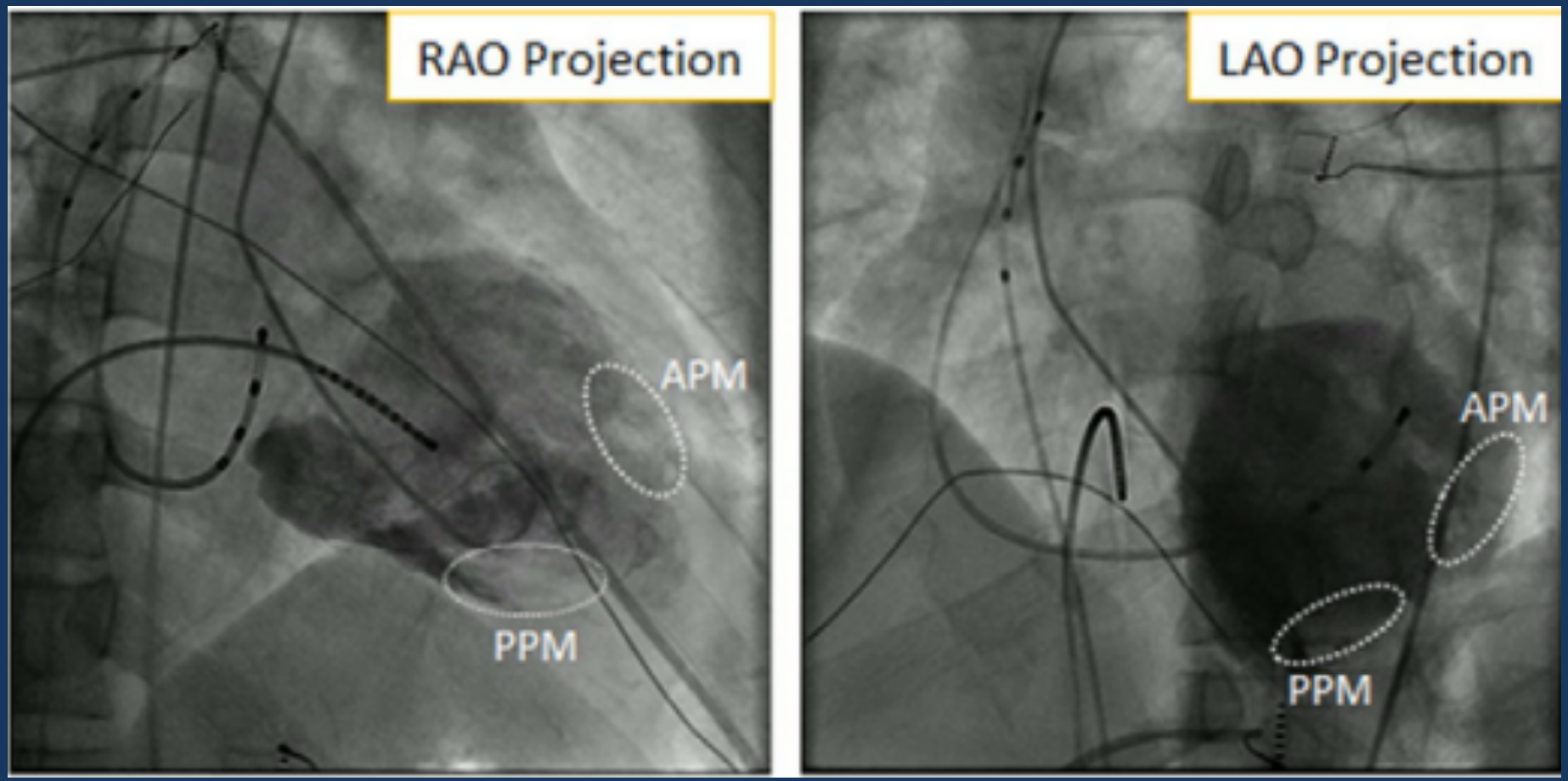
RAO Projection
APM
PPM
LAO Projection
APM
PPM

Kardiyak MRI

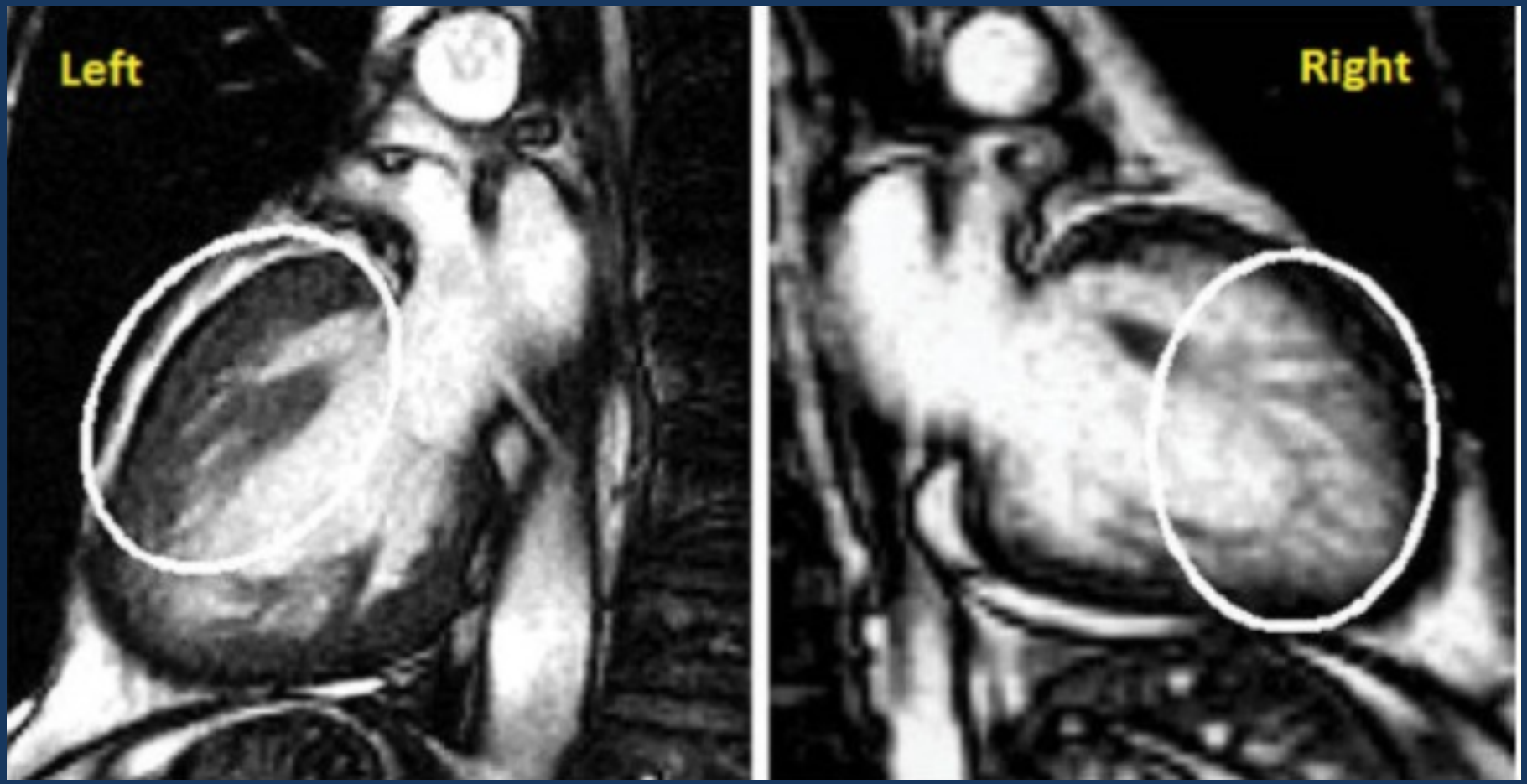

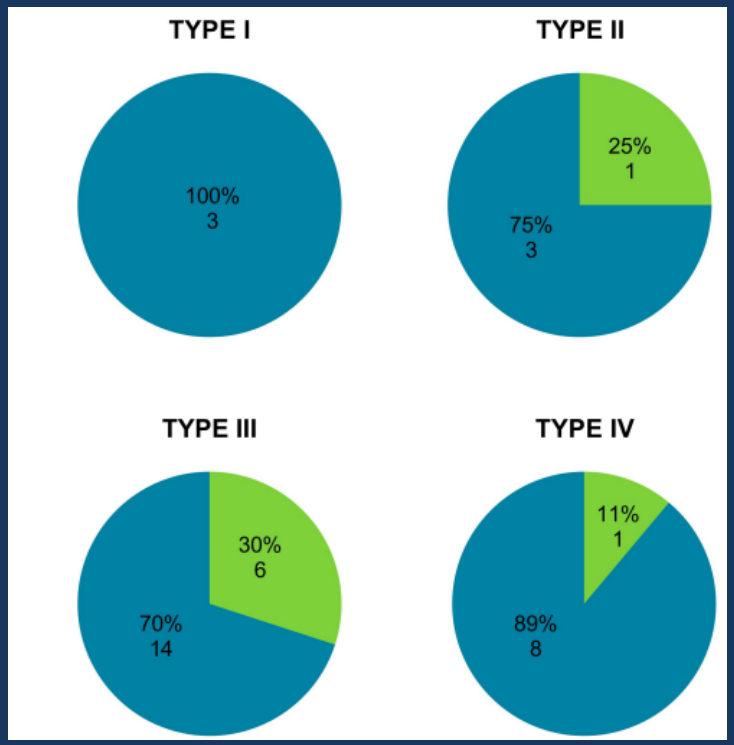

/10.1371/journal.pone.0205786

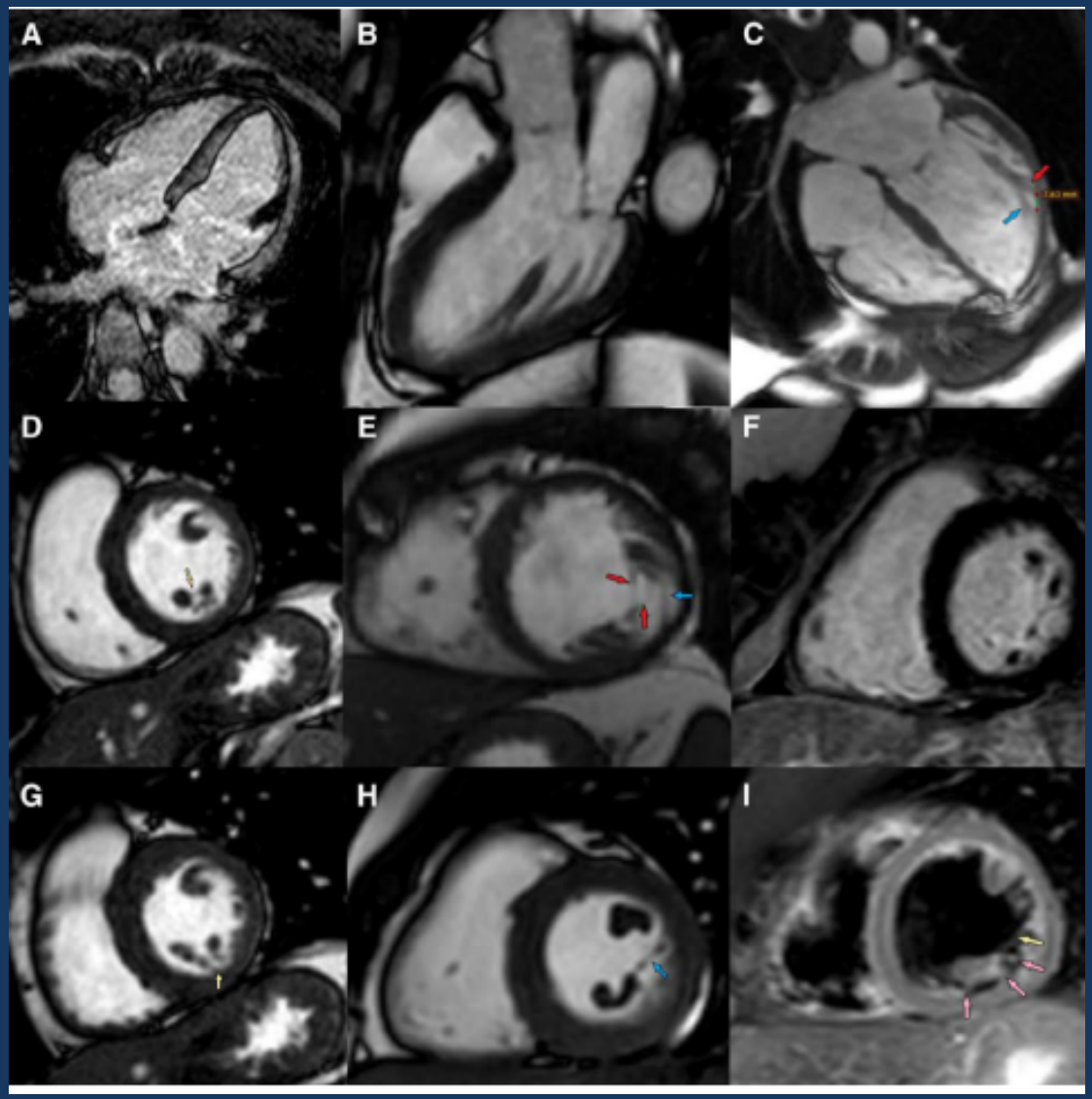

. DOI: 10.1161/CIRCEP.118.007004

A

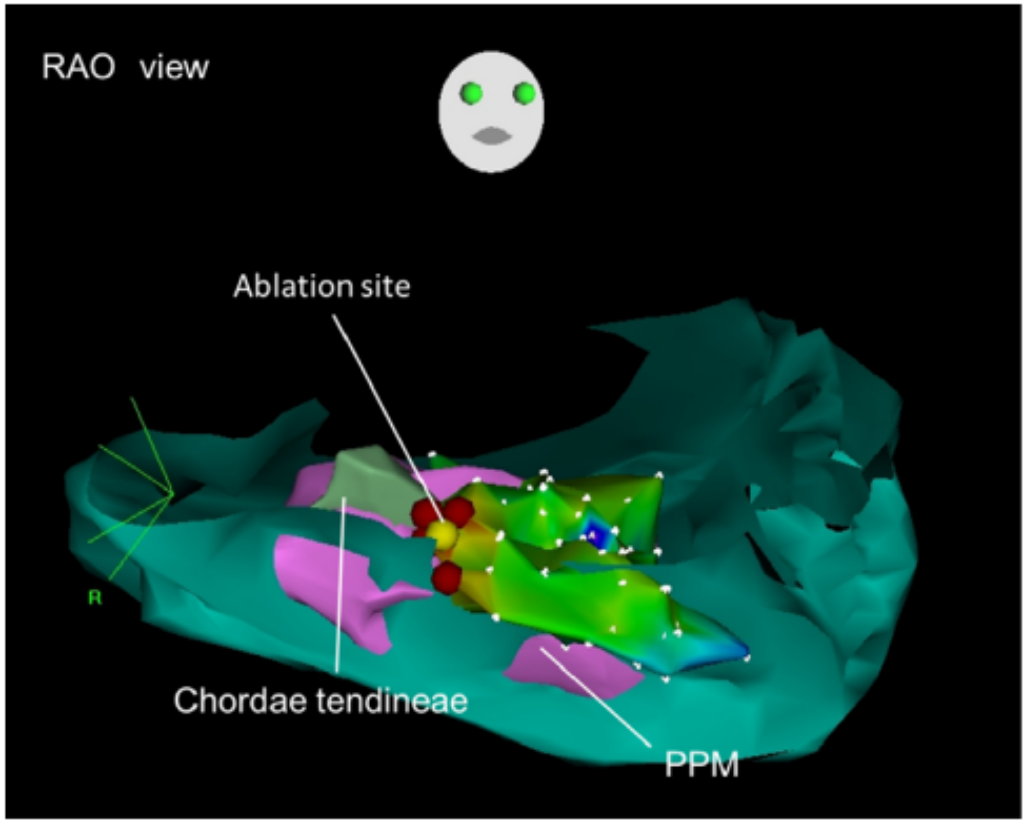
RAO view
Ablation site
Chordae tendineae
PPM

B

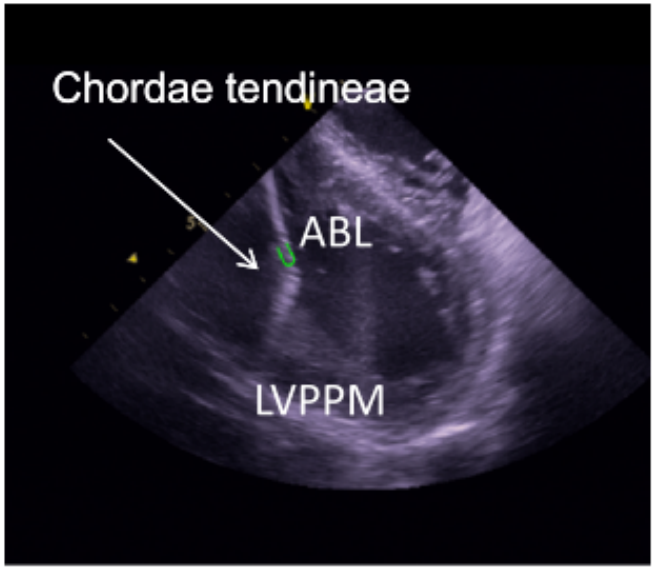
Chordae tendineae
ABL
LVPPM

C

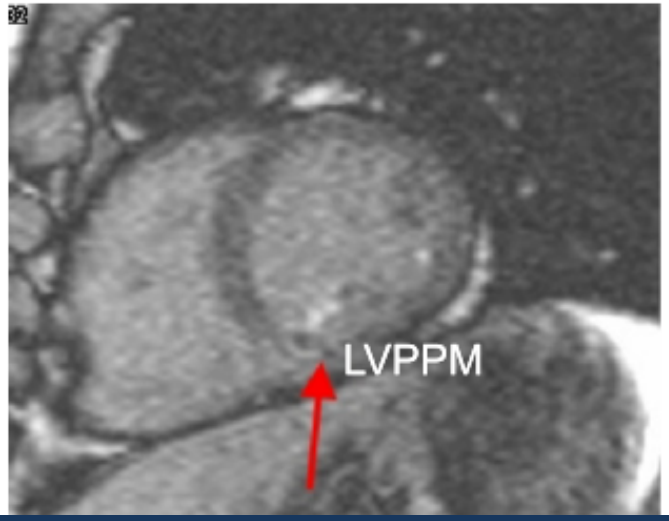
LVPPM

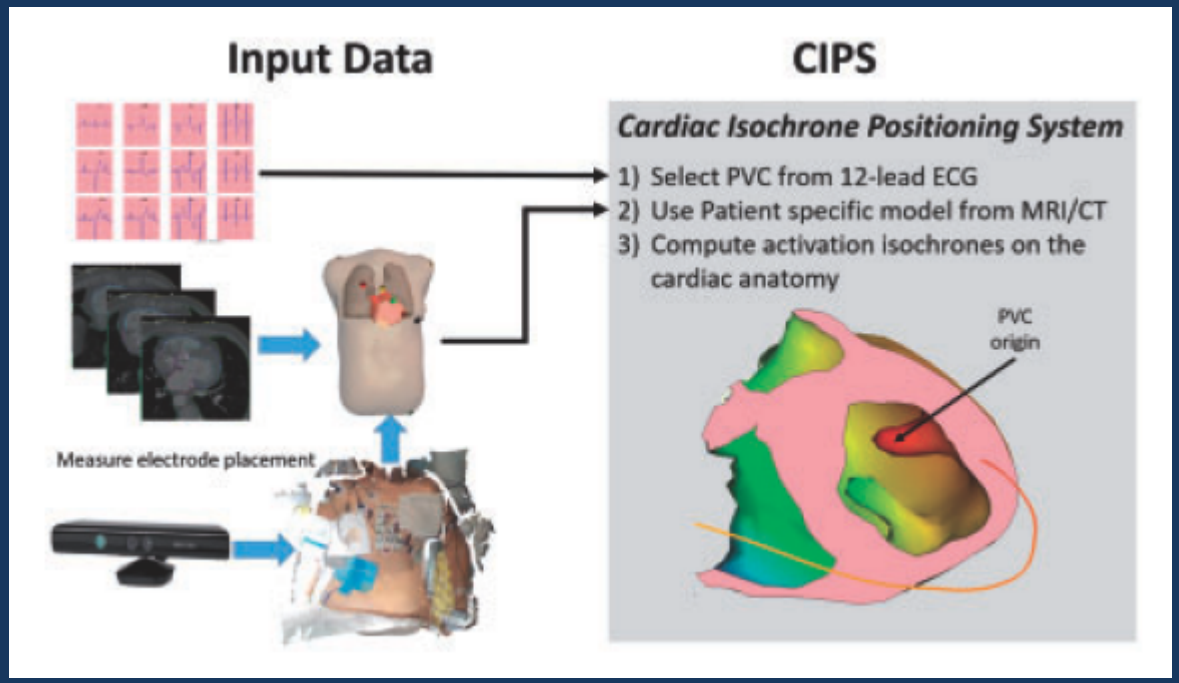

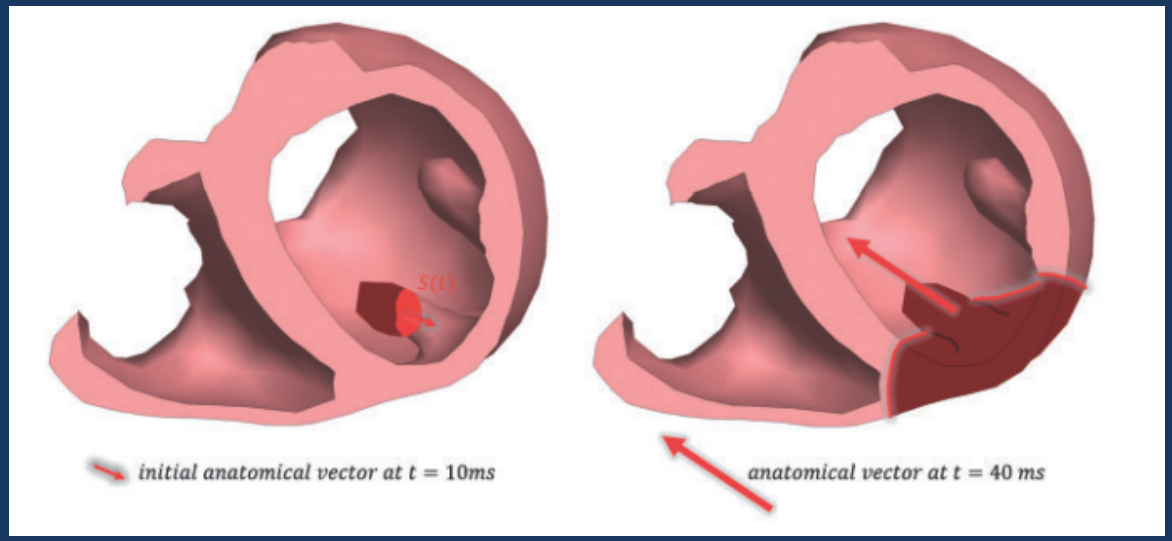

doi:10.1093/europace/euw347

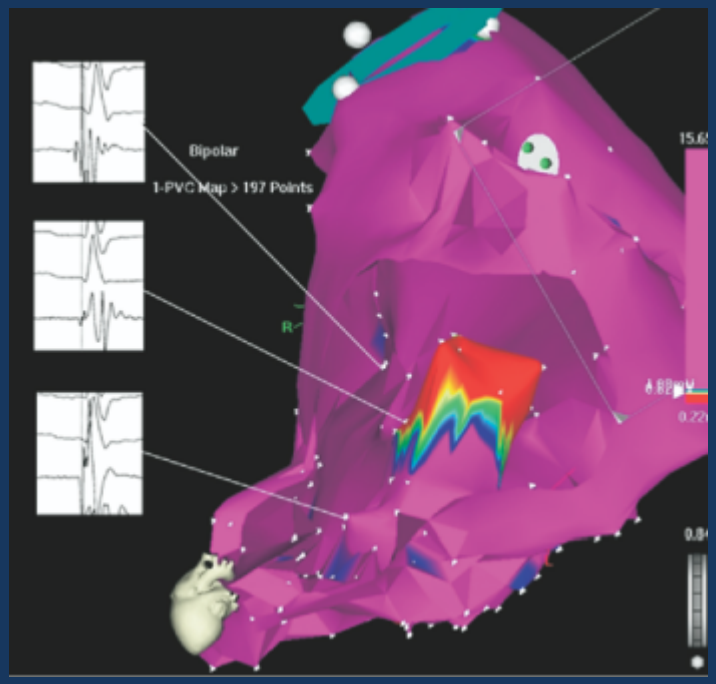
Bipolar
1-PVC Map > 197 Points
R

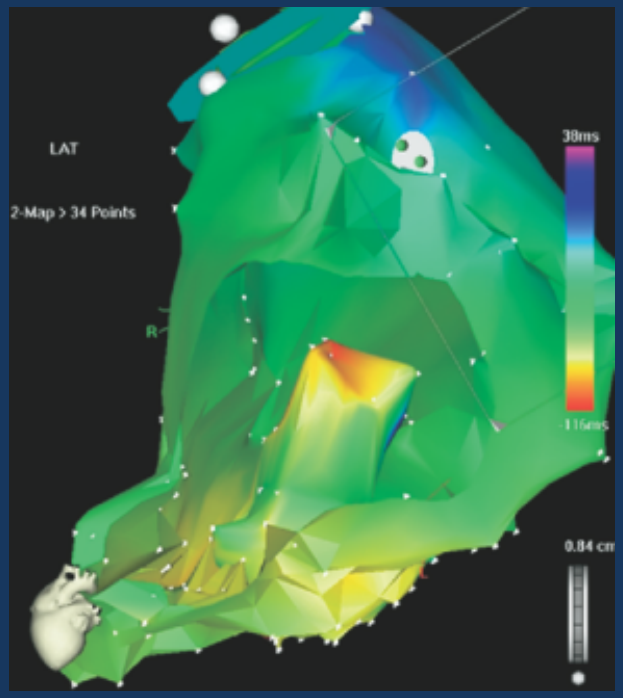
LAT
2-Map > 34 Points
R
38ms
-116ms
0.84 cm

ICE

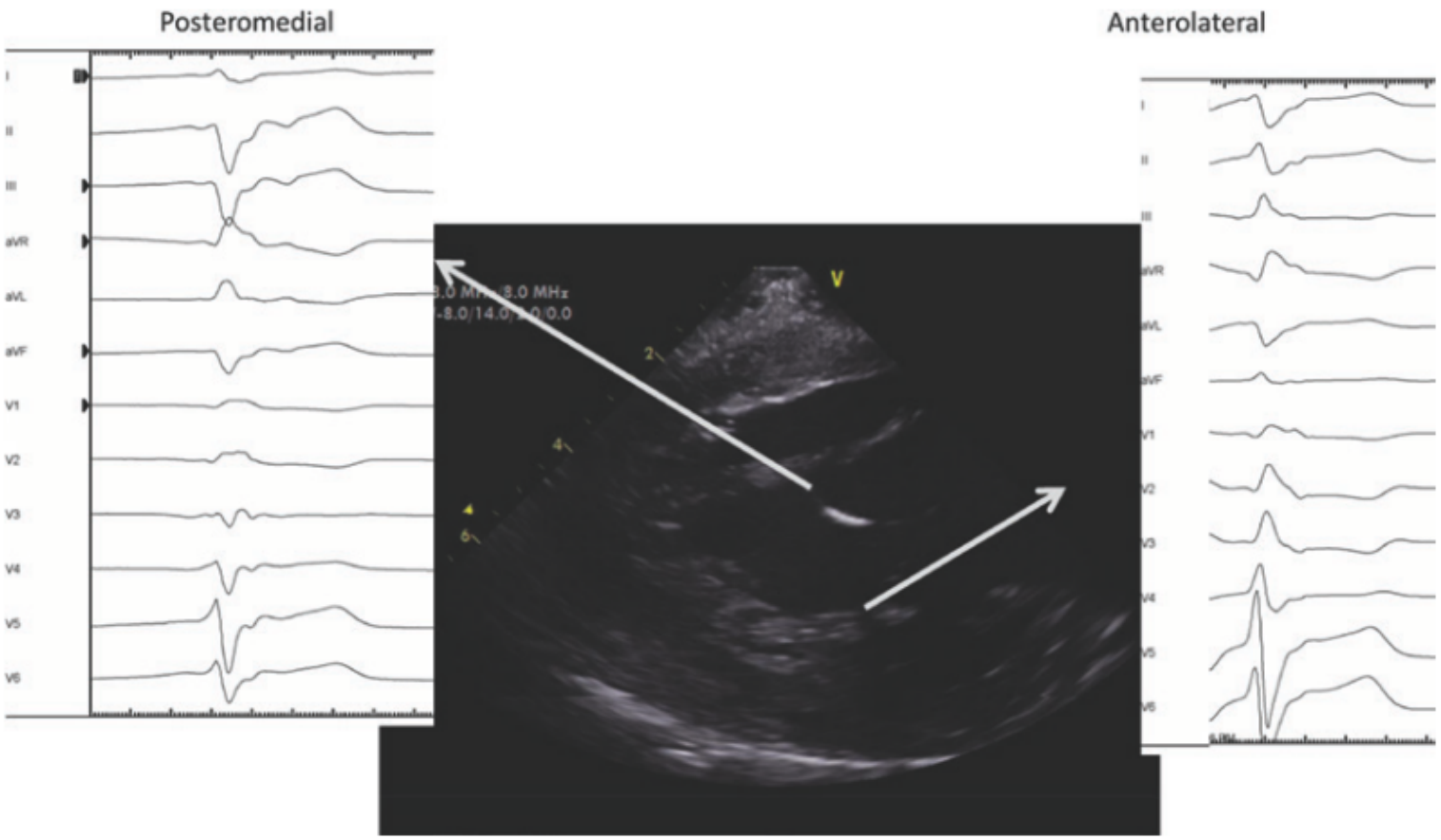
Posteromedial
Anterolateral
I
II
III
aVR
aVL
aVF
V1
V2
V3
V4
V5
V6
V

ICE : “kontakt”

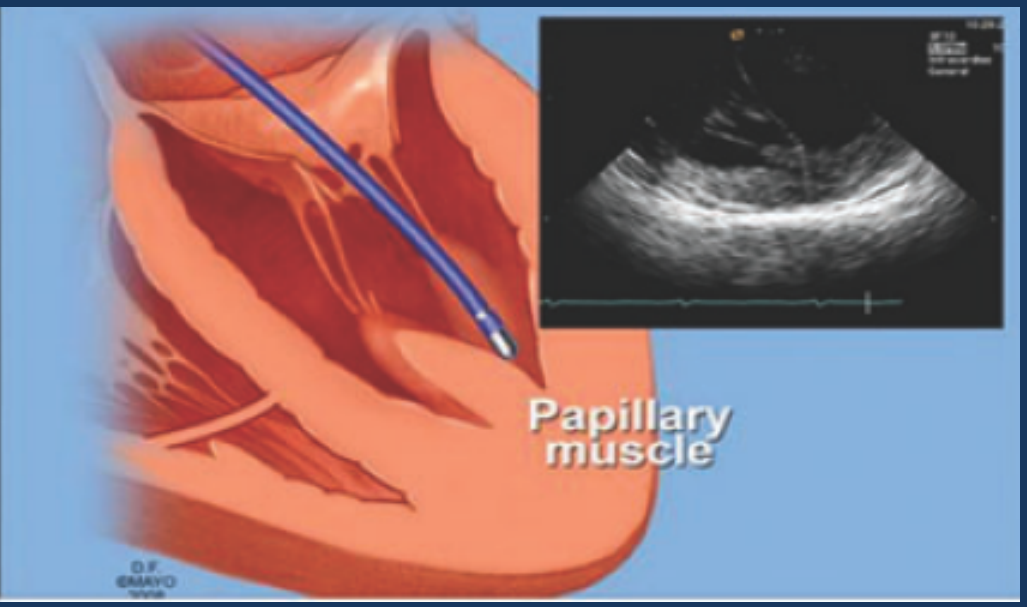

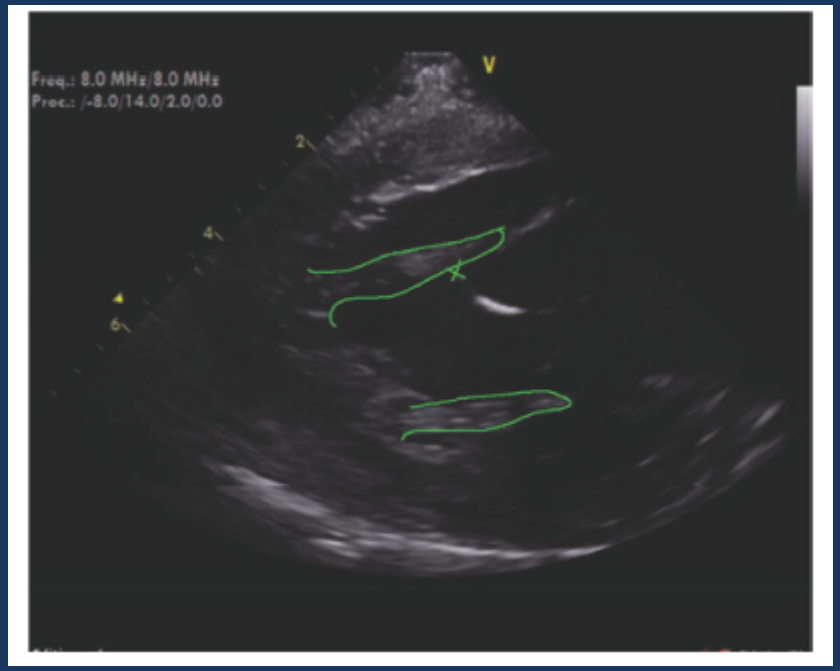

ICE pop oluşumu

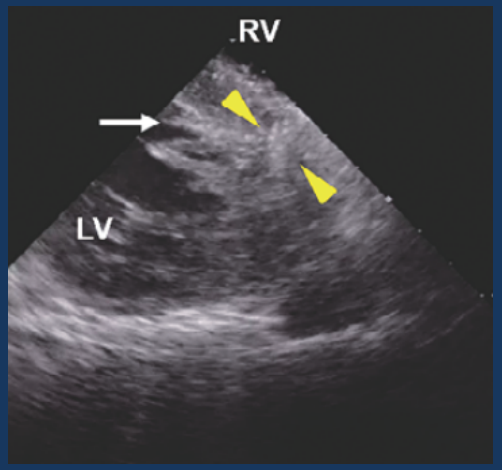

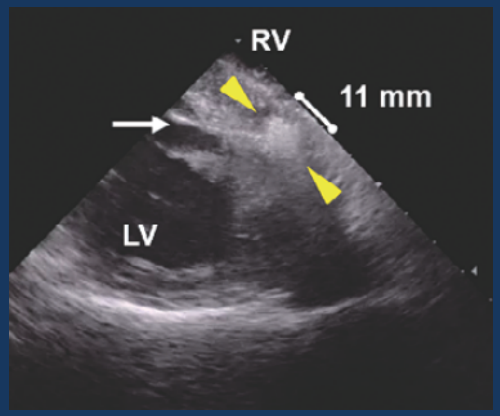

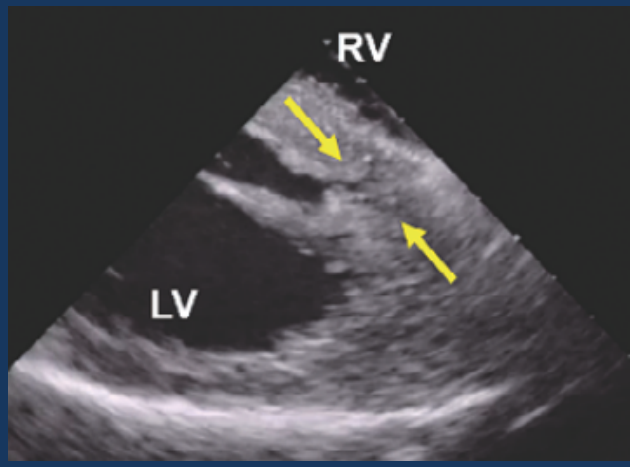

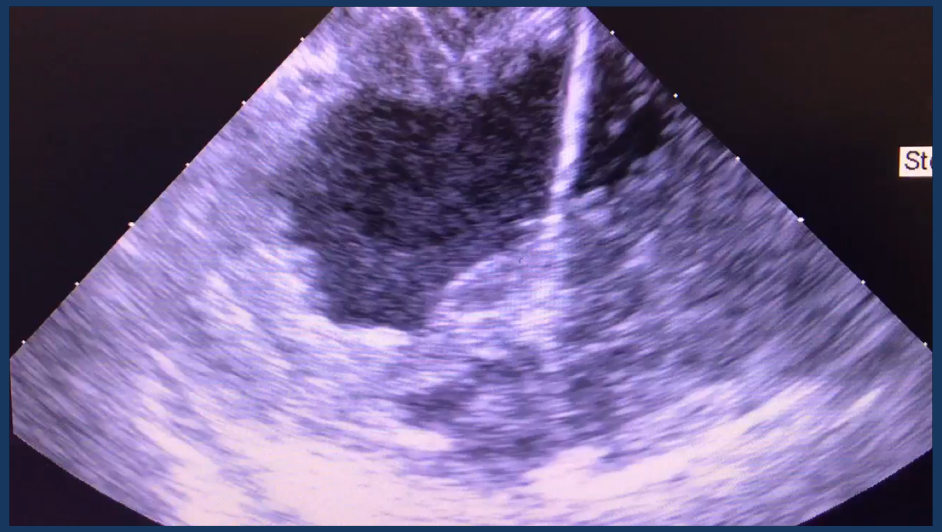

ICE 3D destekli

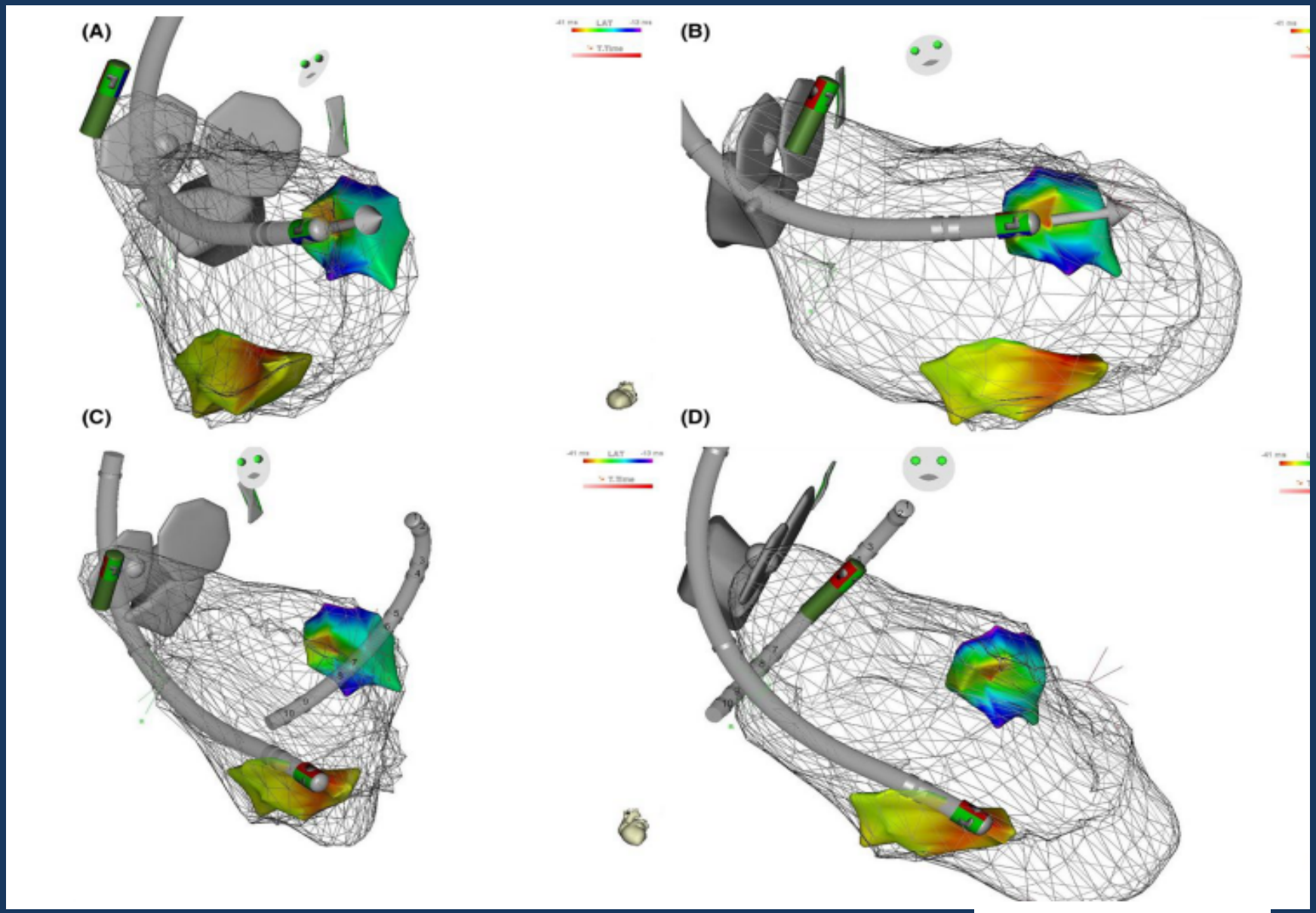

DOI: 10.1002/joa3.12137

CartoSound destekli

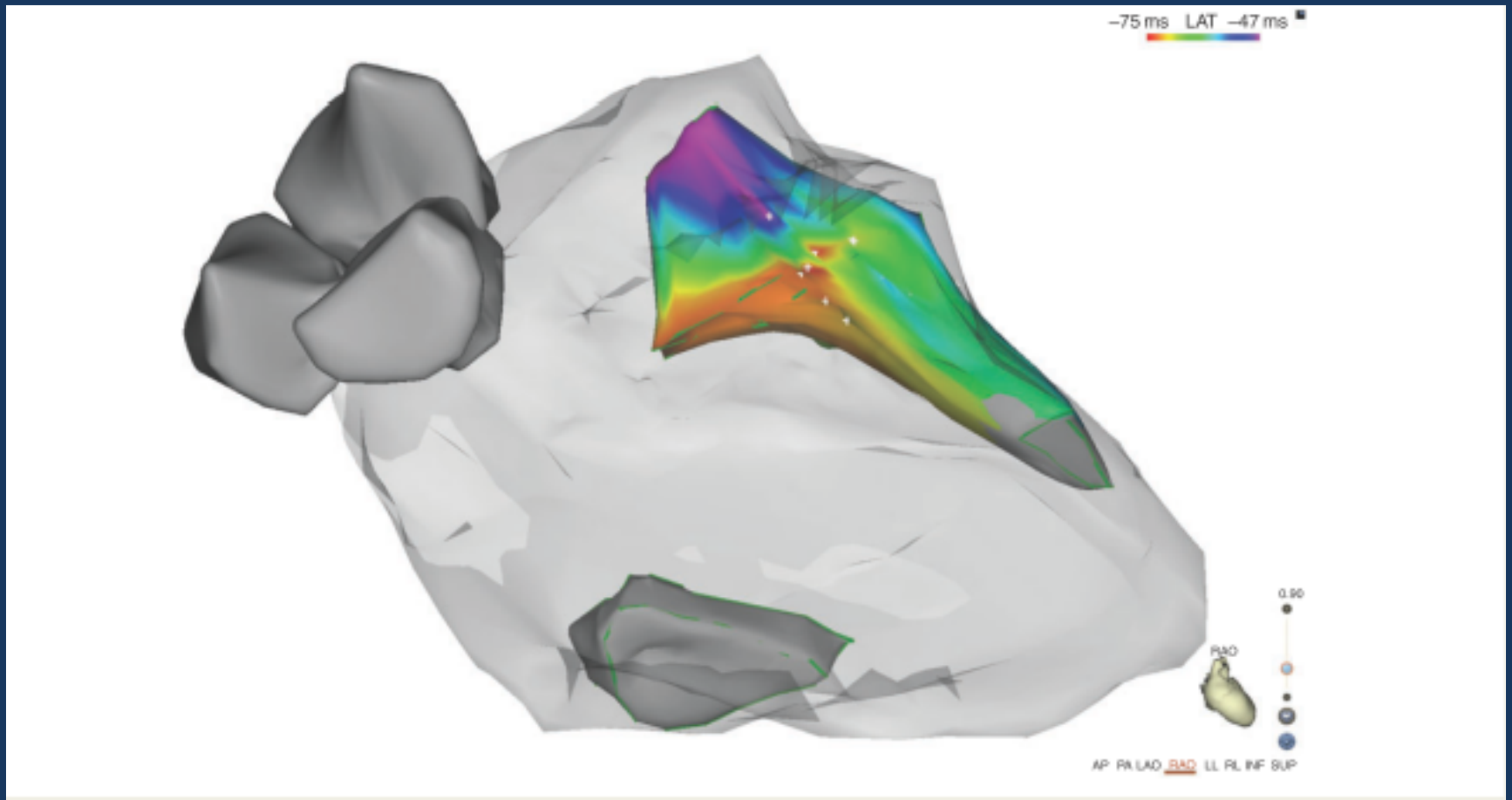
−75 ms LAT −47 ms
0.90
RAO
AP PA LAO RAO LL RL INF SUP

MDCT destekli

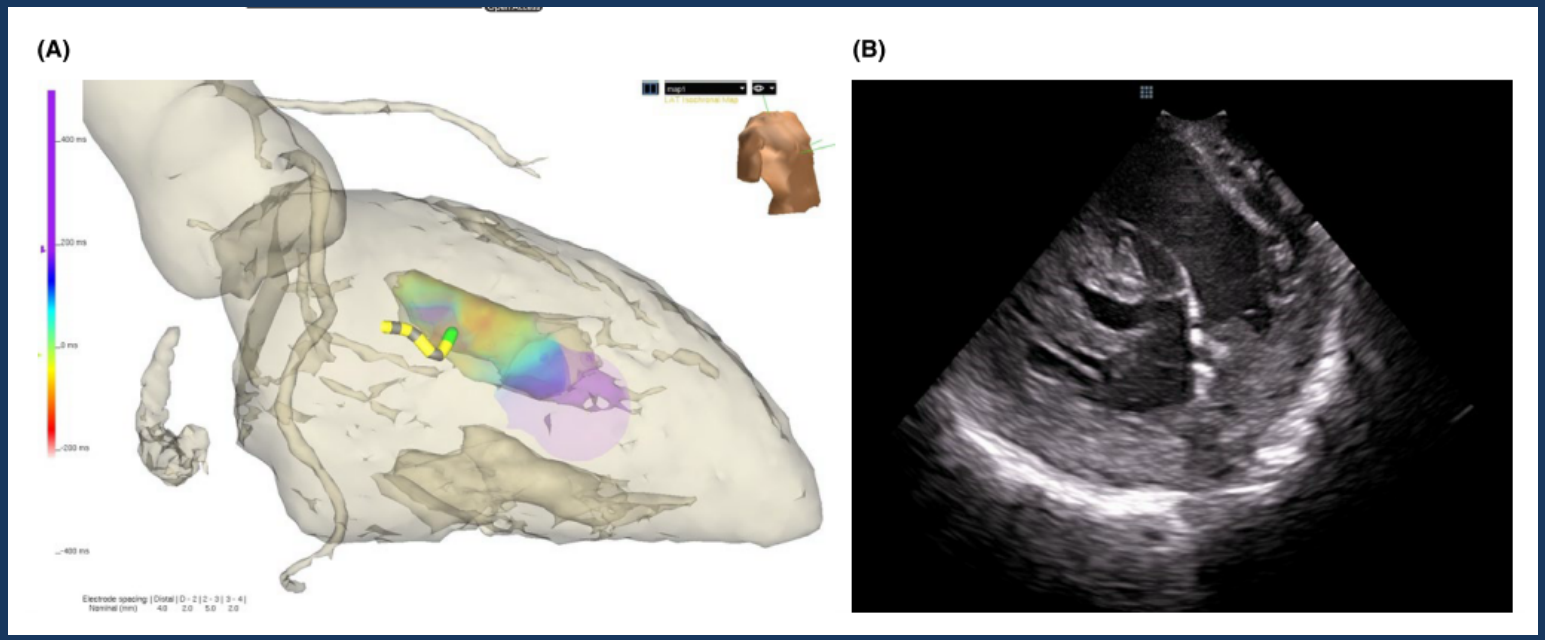

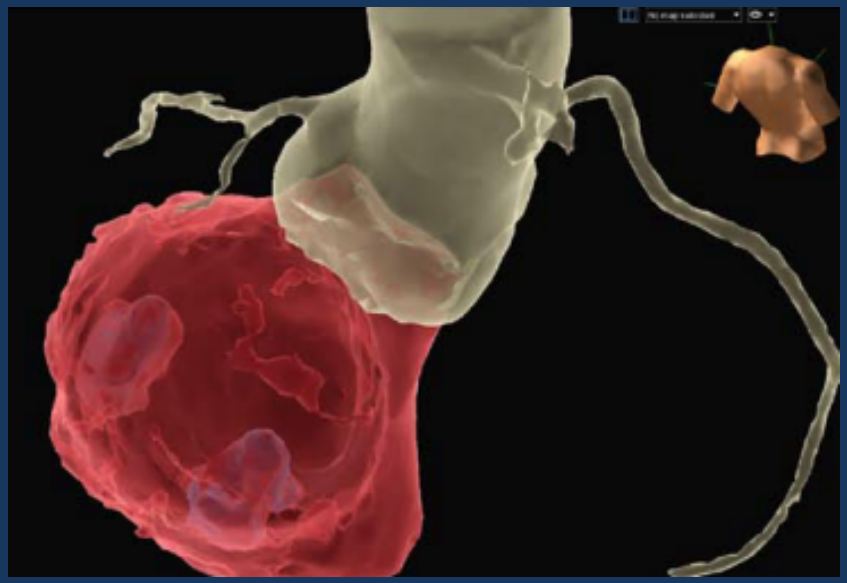

ICE : 28.5% den 70-90%

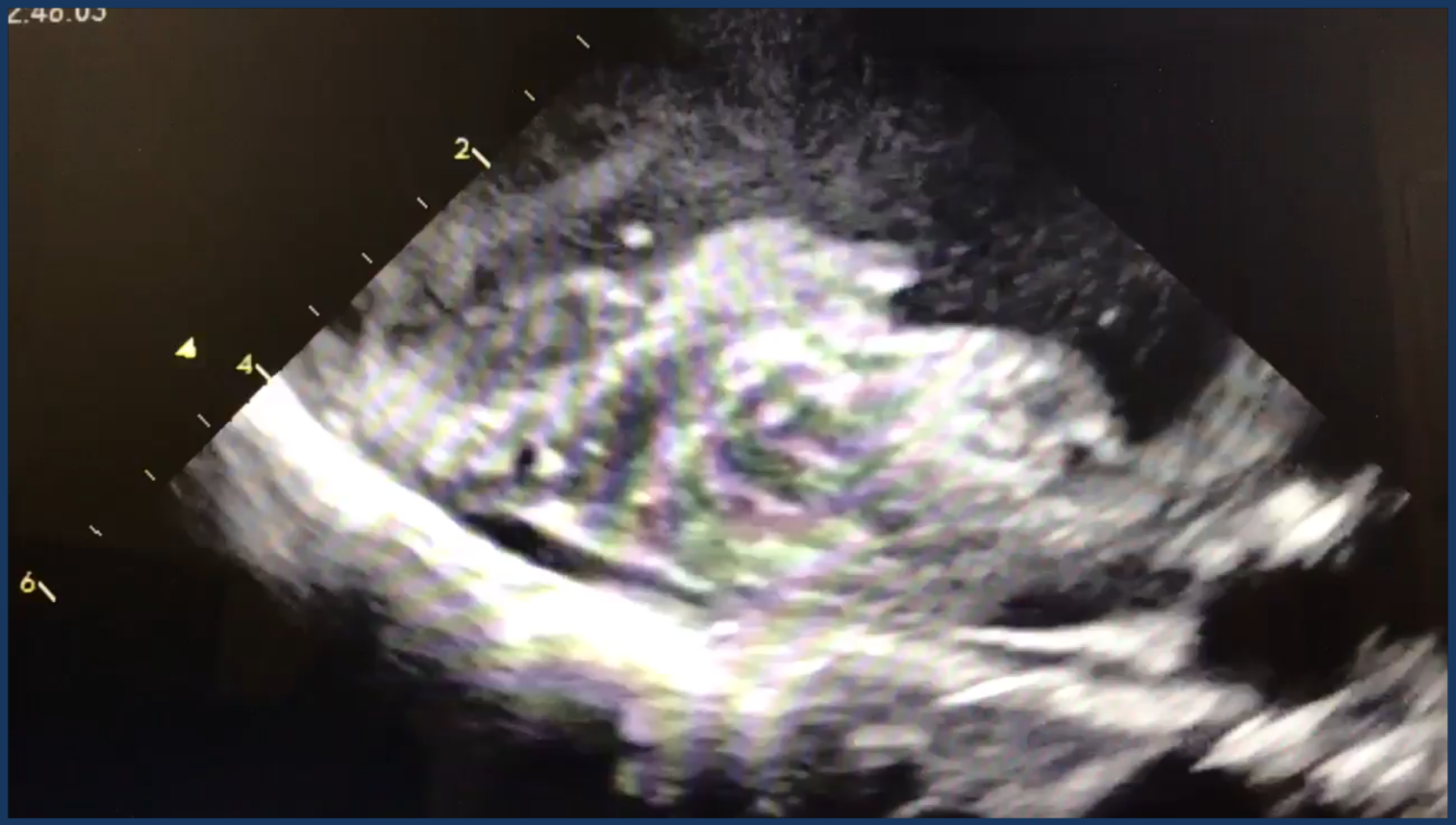


684
-87
Loc
2.15
146
CL
LAT (ms)
Bi (mV)
Imp (Ω)
- 19 ms
5 ohm
Imp
10 ohm
Moderator
Band
Septal
PM
Ant. PM
Post. PM
RAO
Pace map 98.7%
I
II
III
aVR
aVL
aVF
VI
V2
V3
V4
V5
V6

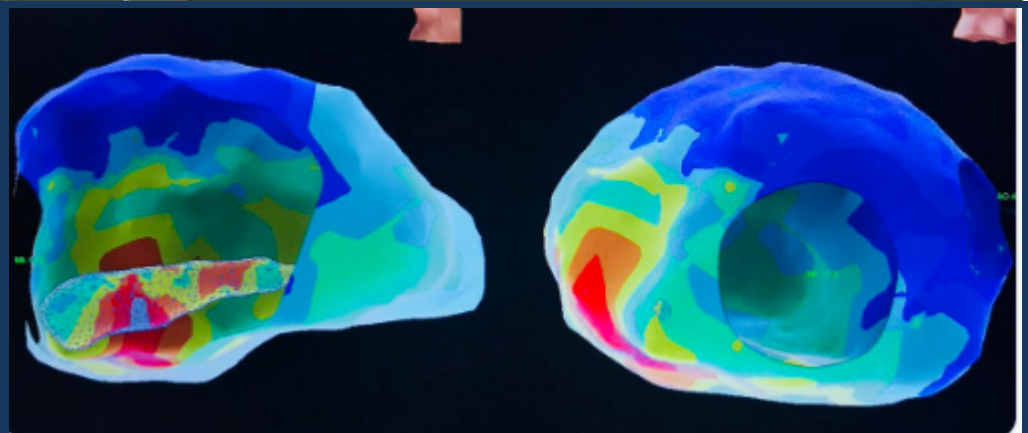

Circumferential ablation

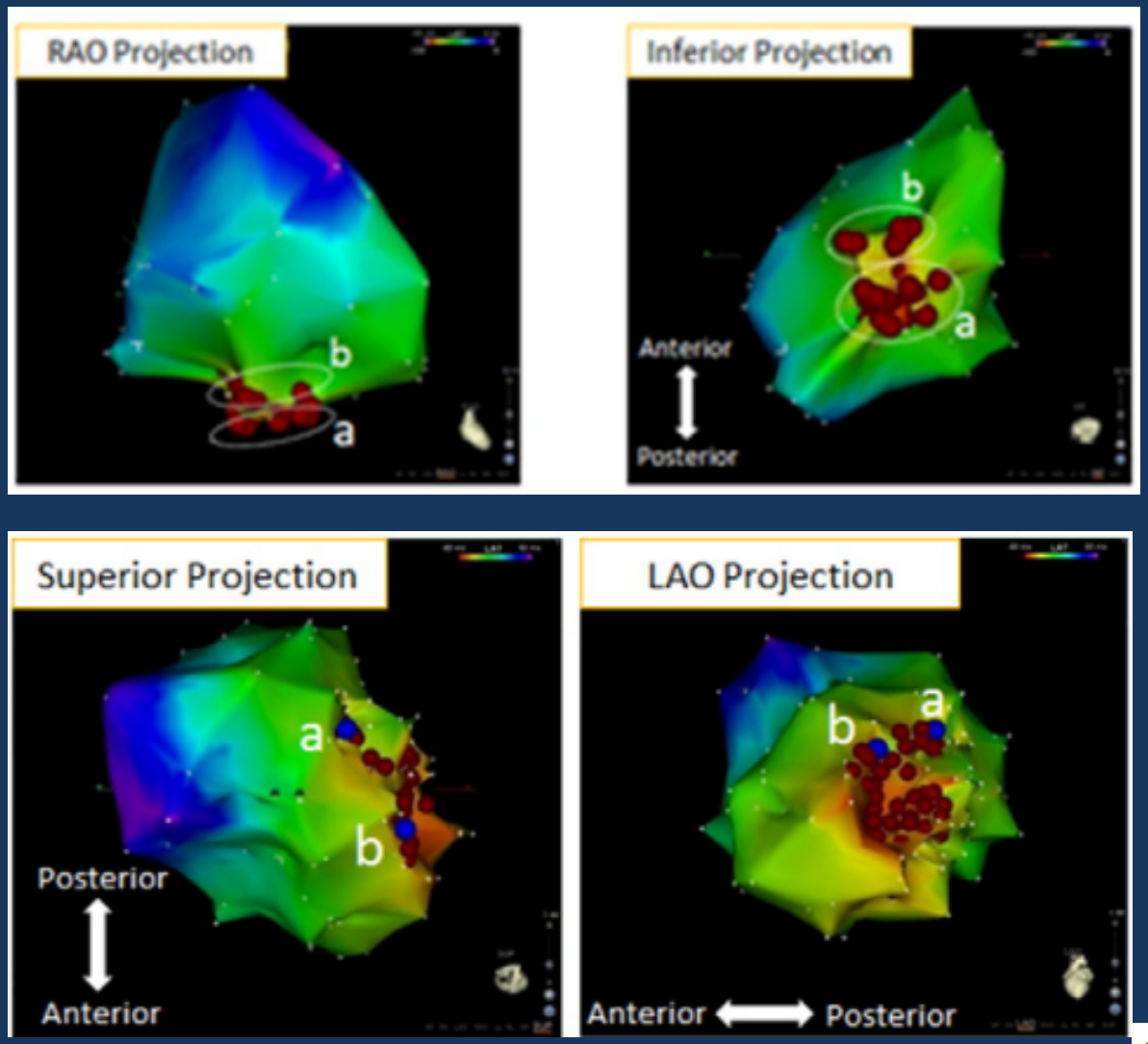

. doi: 10.1016/j.ijcard.2016.06.151.

DOI: 10.1002/joa3.12137

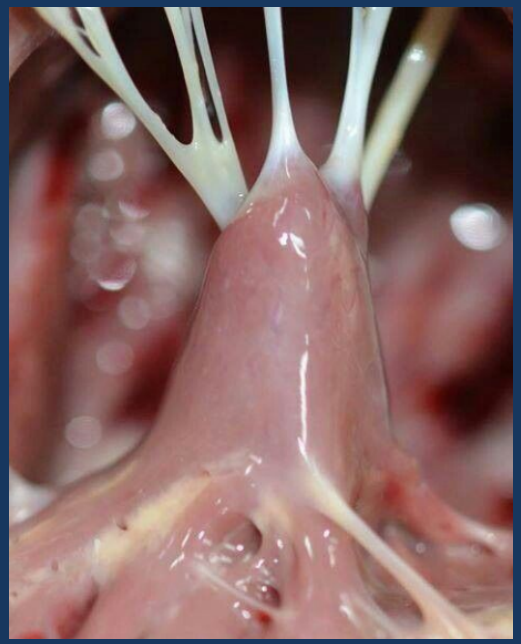

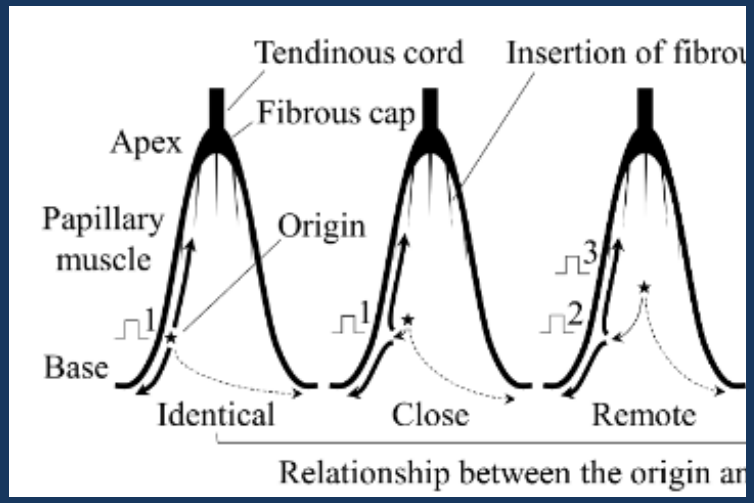
Tendinous cord
Insertion of fibrou
Fibrous cap
Apex
Papillary muscle
Origin
1
1
3
2
Base
Identical
Close
Remote
Relationship between the origin ar

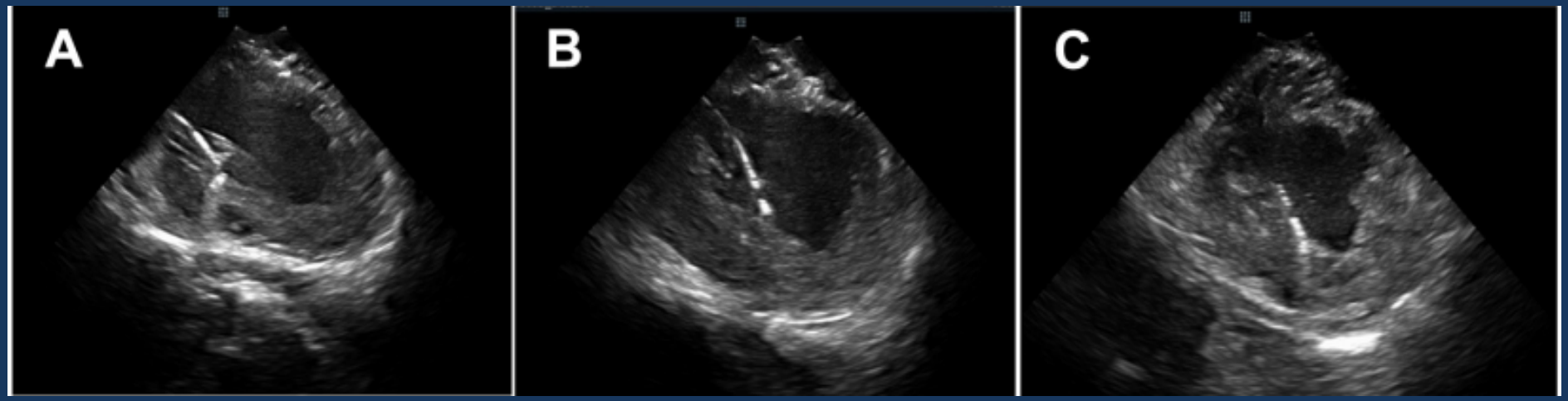
A
B
C

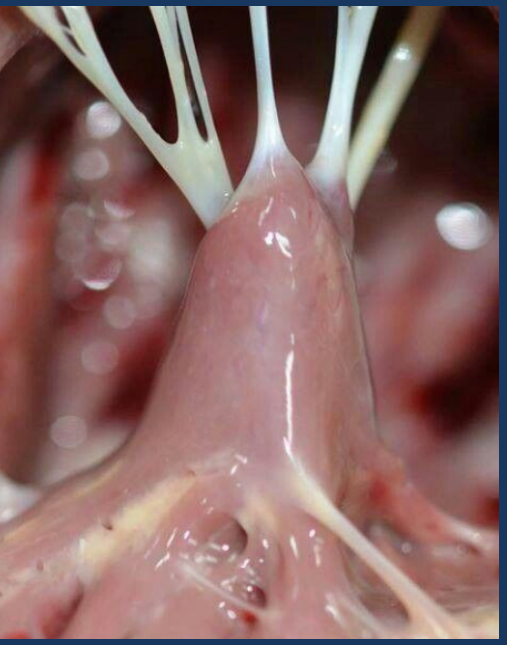

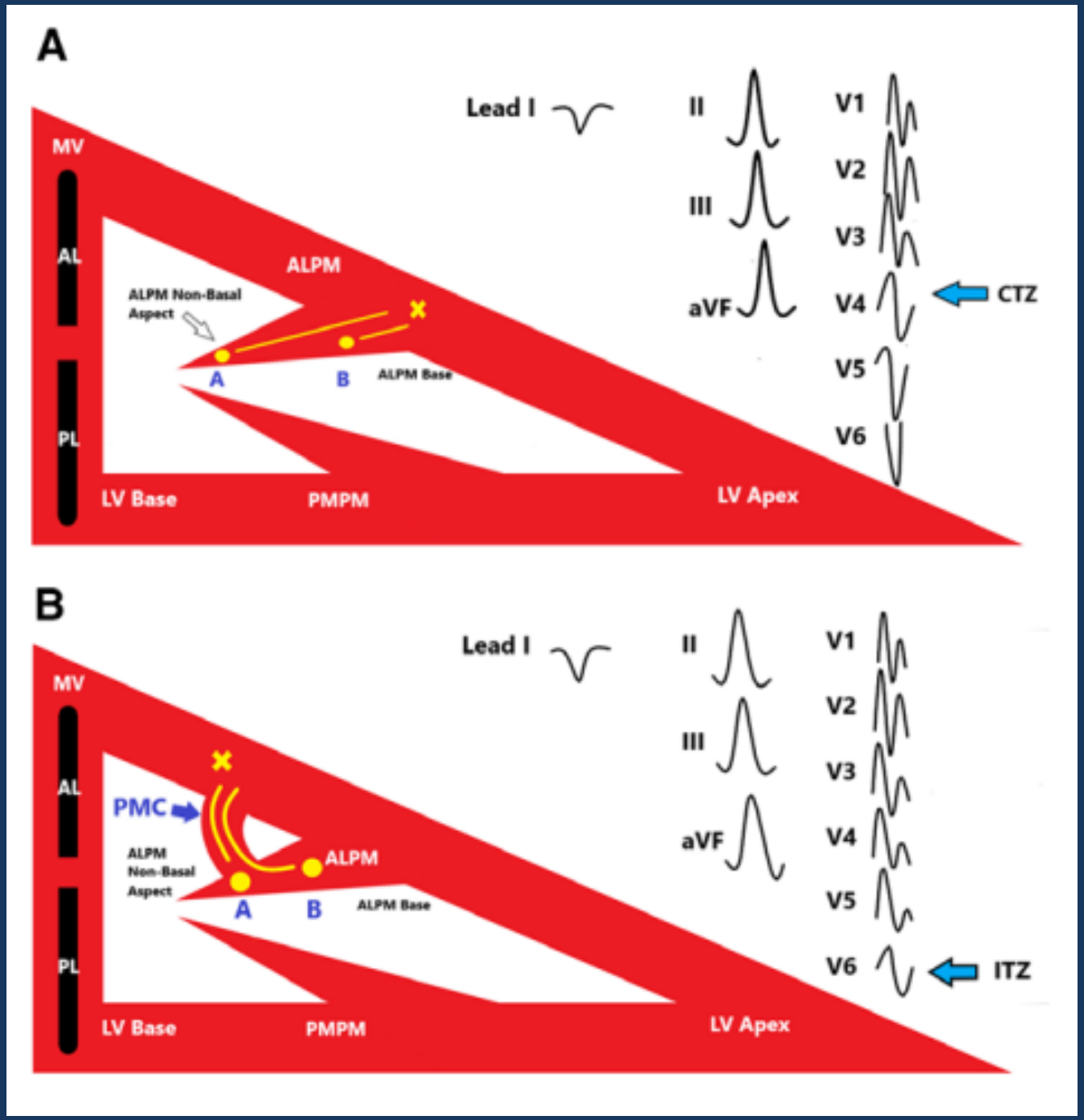
A
Lead I
II
III
aVF
V1
V2
V3
V4
V5
V6
CTZ
MV
AL
PL
ALPM
ALPM Non-Basal Aspect
A
B
ALPM Base
LV Base
PMPM
LV Apex
B
Lead I
II
III
aVF
V1
V2
V3
V4
V5
V6
ITZ
MV
AL
PL
PMC
ALPM Non-Basal Aspect
ALPM
A
B
ALPM Base
LV Base
PMPM
LV Apex

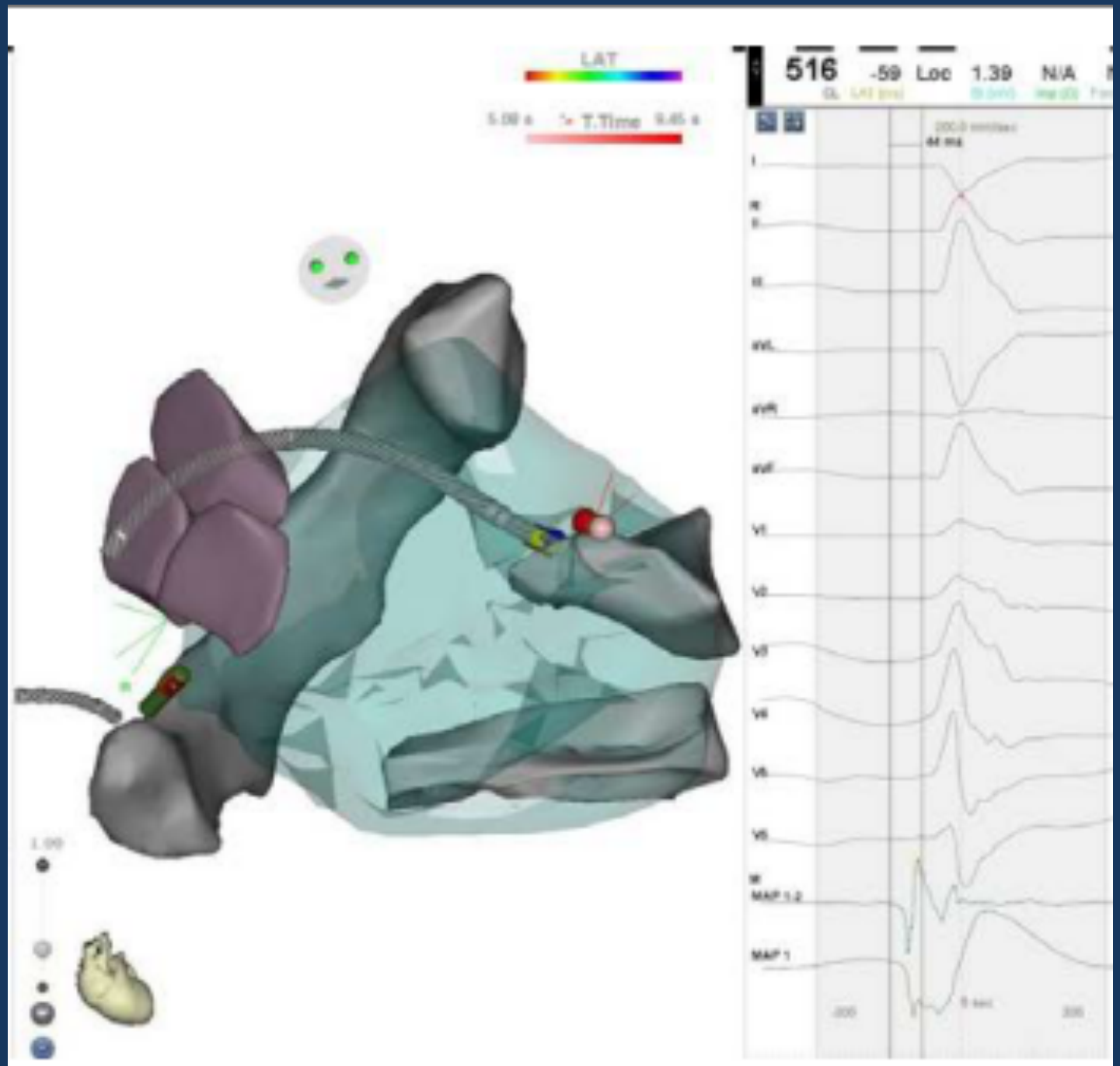
LAT
T.Time
516
-59
Loc
1.39
N/A
44 ms
I
II
III
aVL
aVR
aVF
V1
V2
V3
V4
V5
V6
MAP 1-2
MAP 1

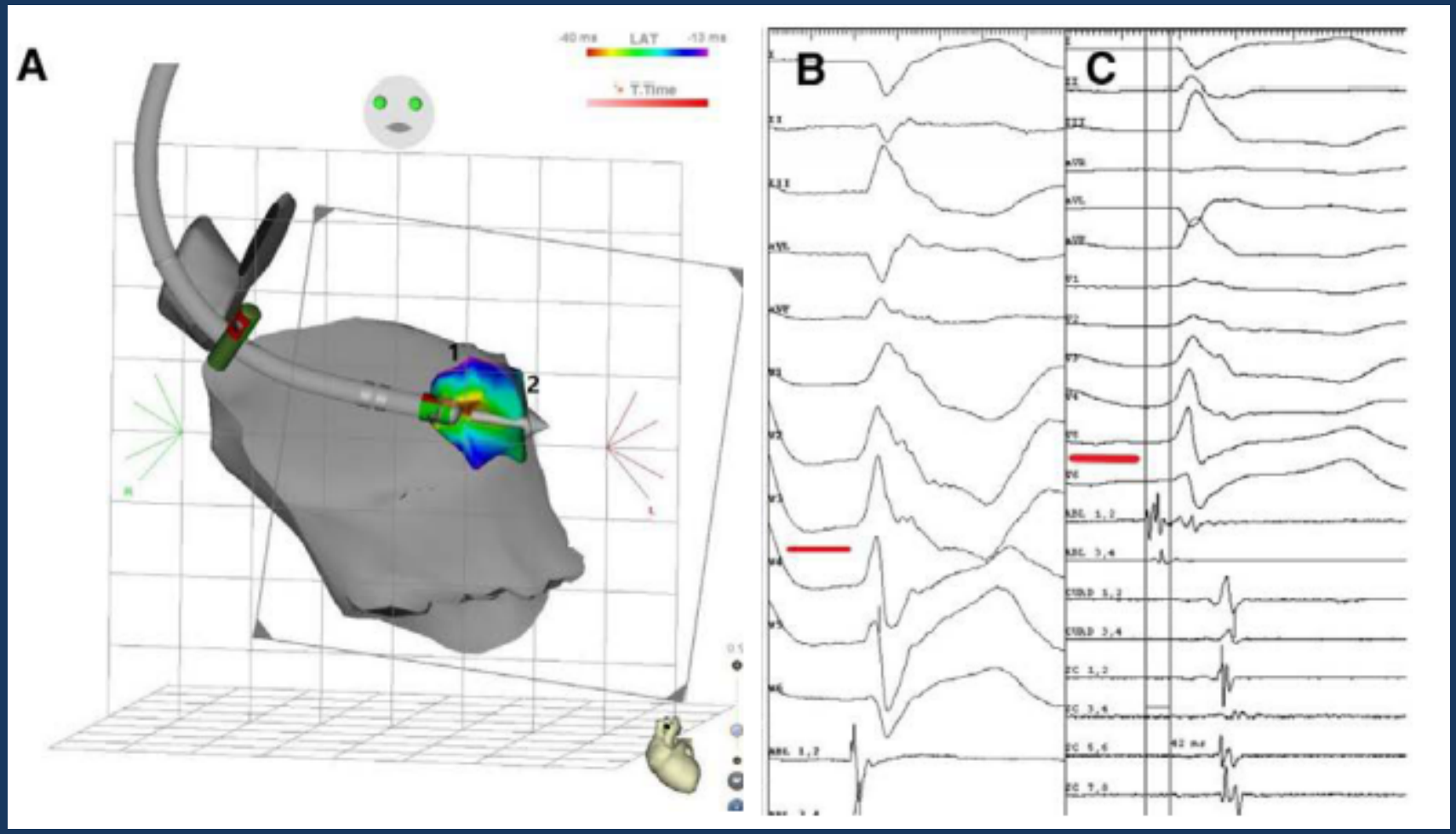
A
-40 ms
LAT
-13 ms
T.Time
1
2
B
C

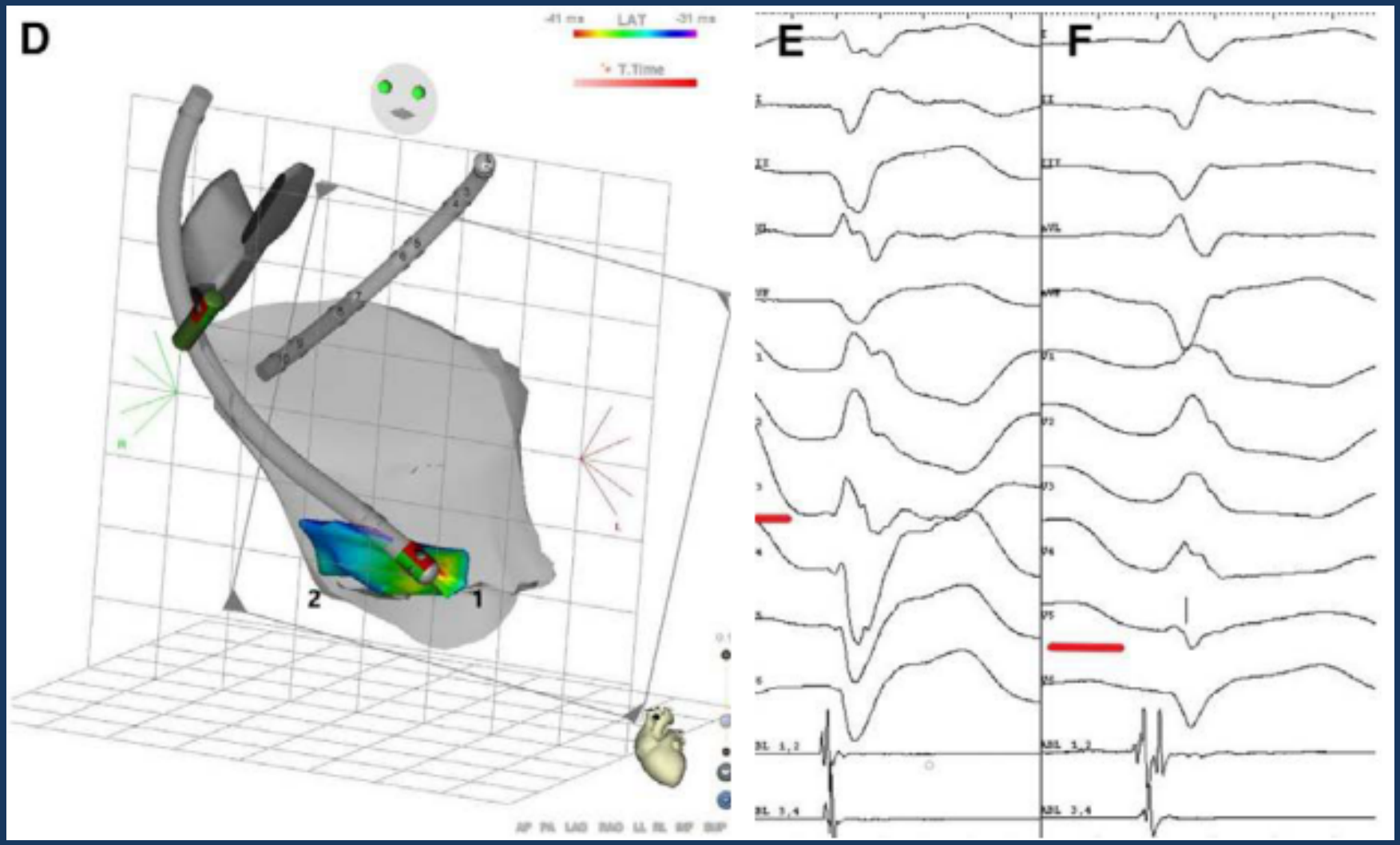
D
-41 ms
LAT
-31 ms
T.Time
2
1
AP PA LAO RAO LL RL RP RAP
E
F

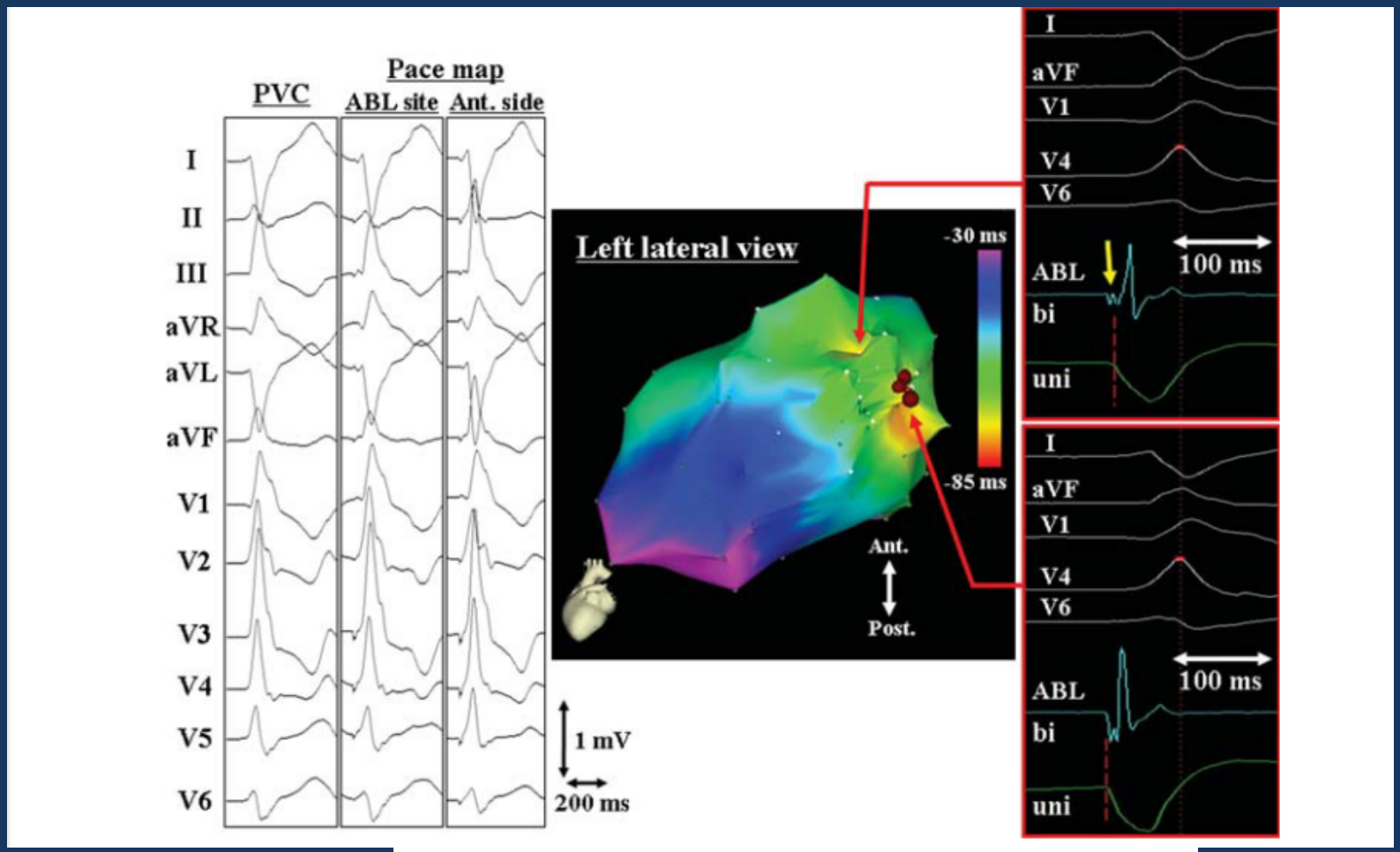
PVC
Pace map
ABL site
Ant. side
I
II
III
aVR
aVL
aVF
V1
V2
V3
V4
V5
V6
1 mV
200 ms
Left lateral view
-30 ms
-85 ms
Ant.
Post.
ABL
bi
uni
100 ms

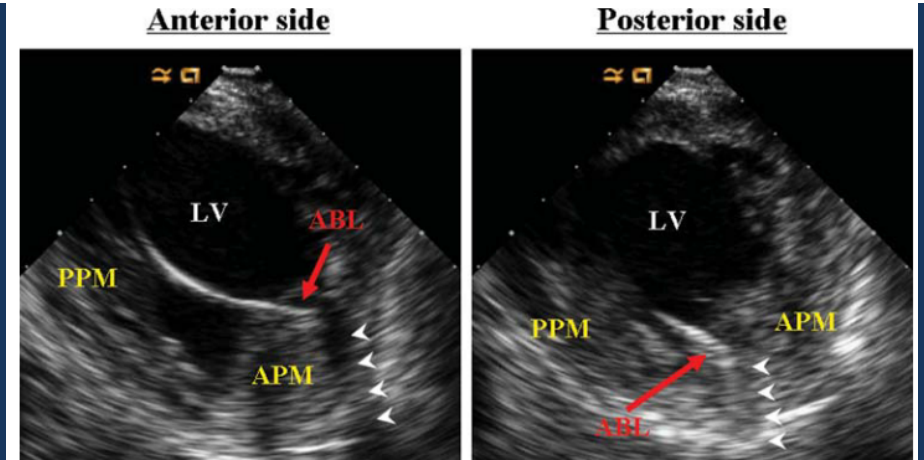
Anterior side
Posterior side
LV
ABL
PPM
APM

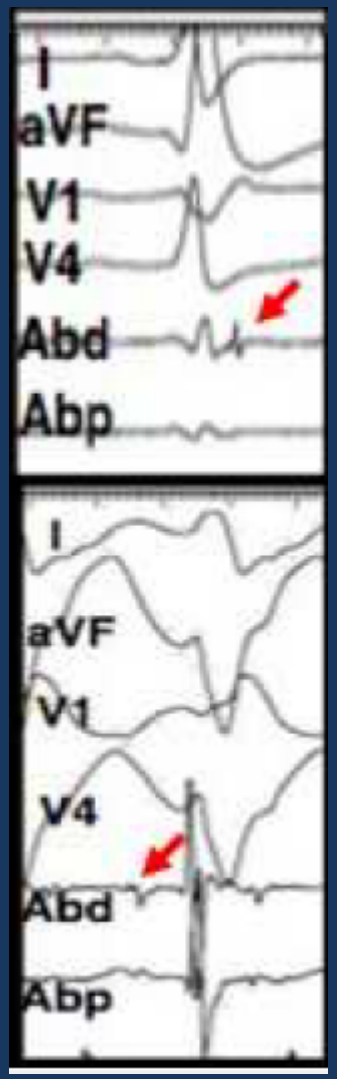

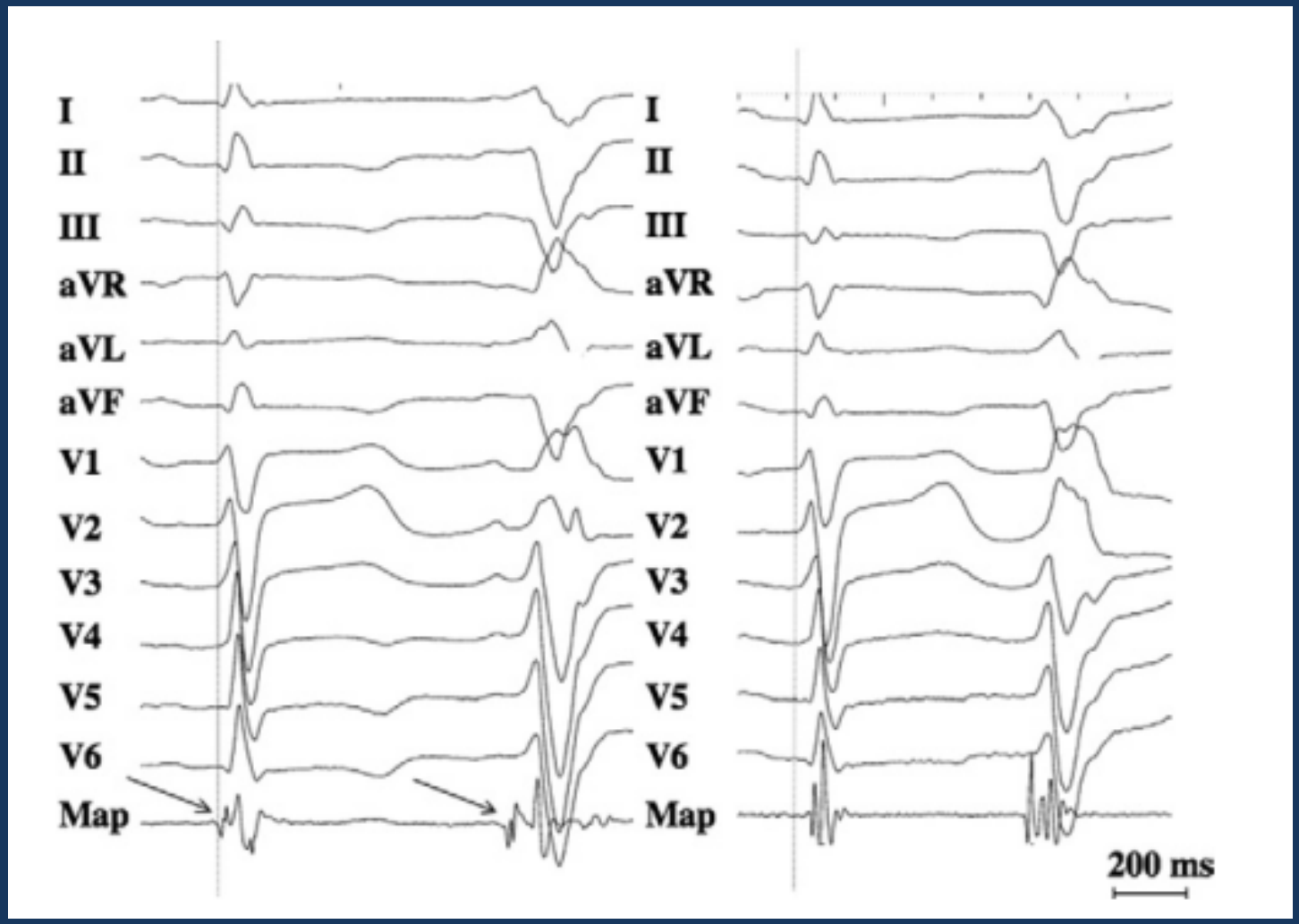

doi:10.1016/j.hrthm.2008.08.032

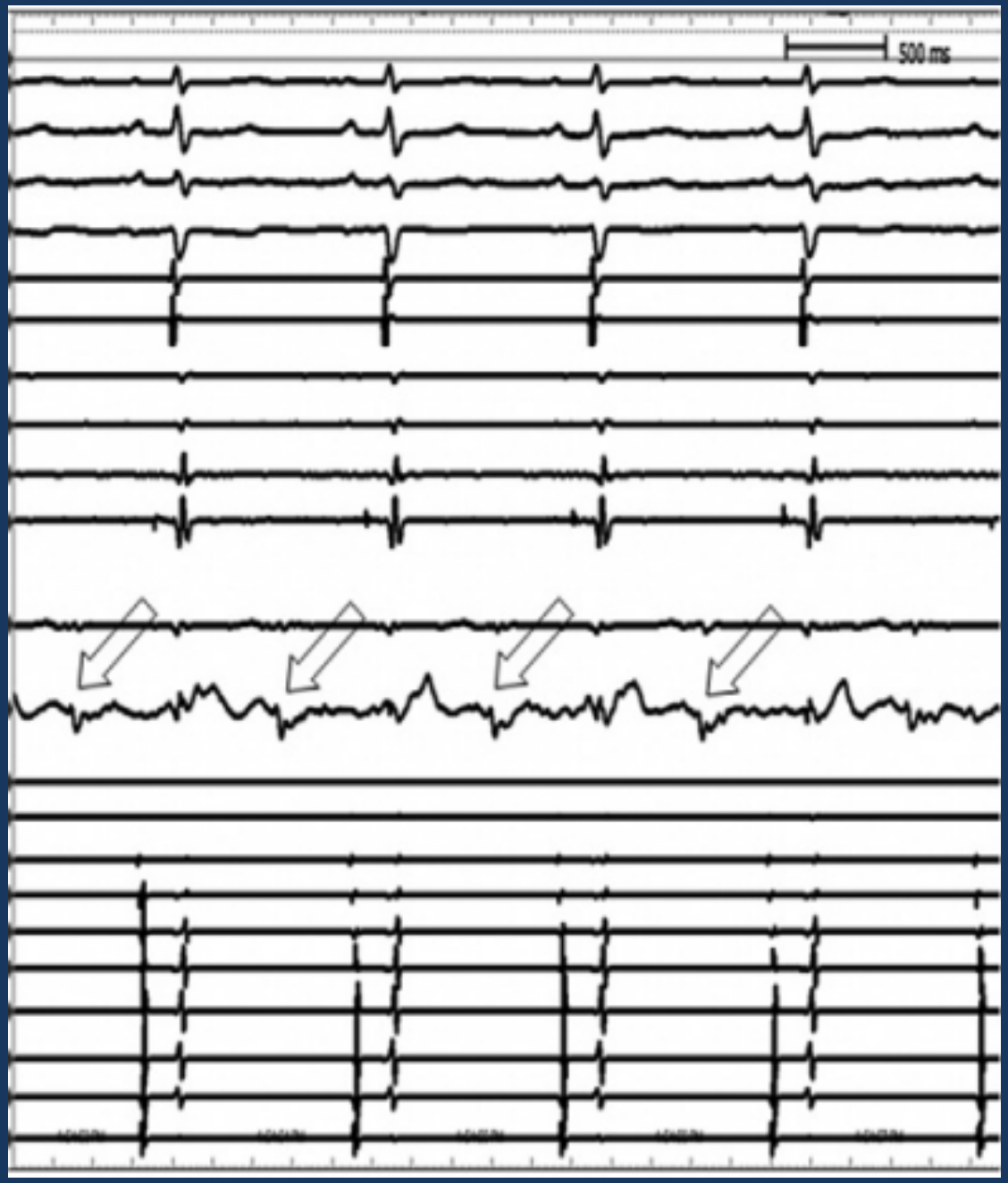
500 ms

Pacemap her zaman güvenilir mi ?

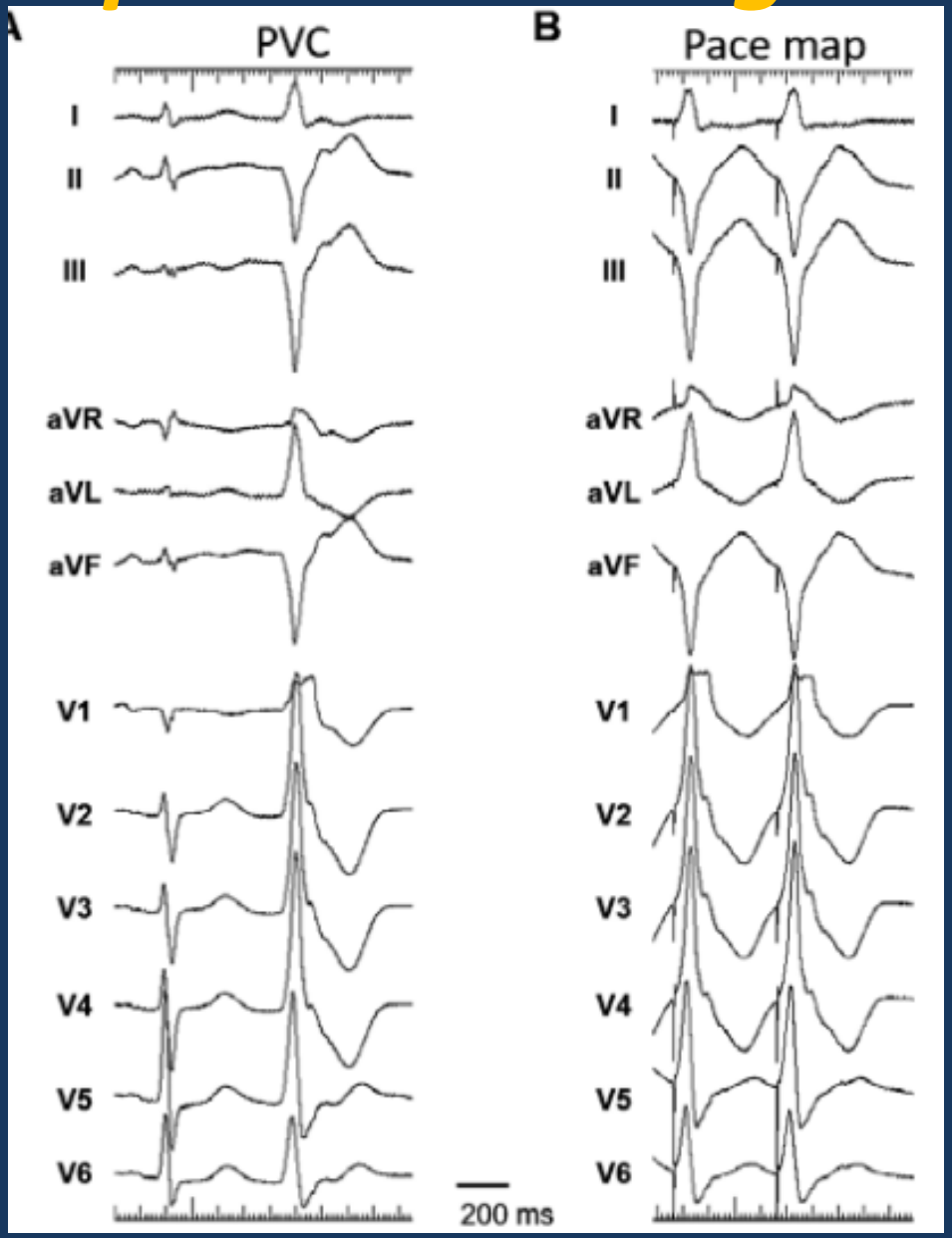

Preferential conduction

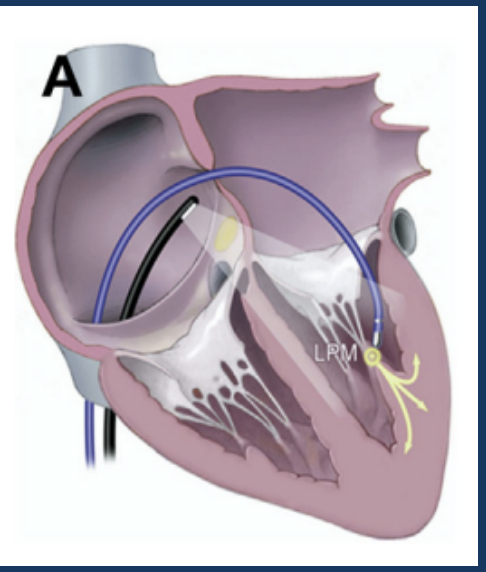

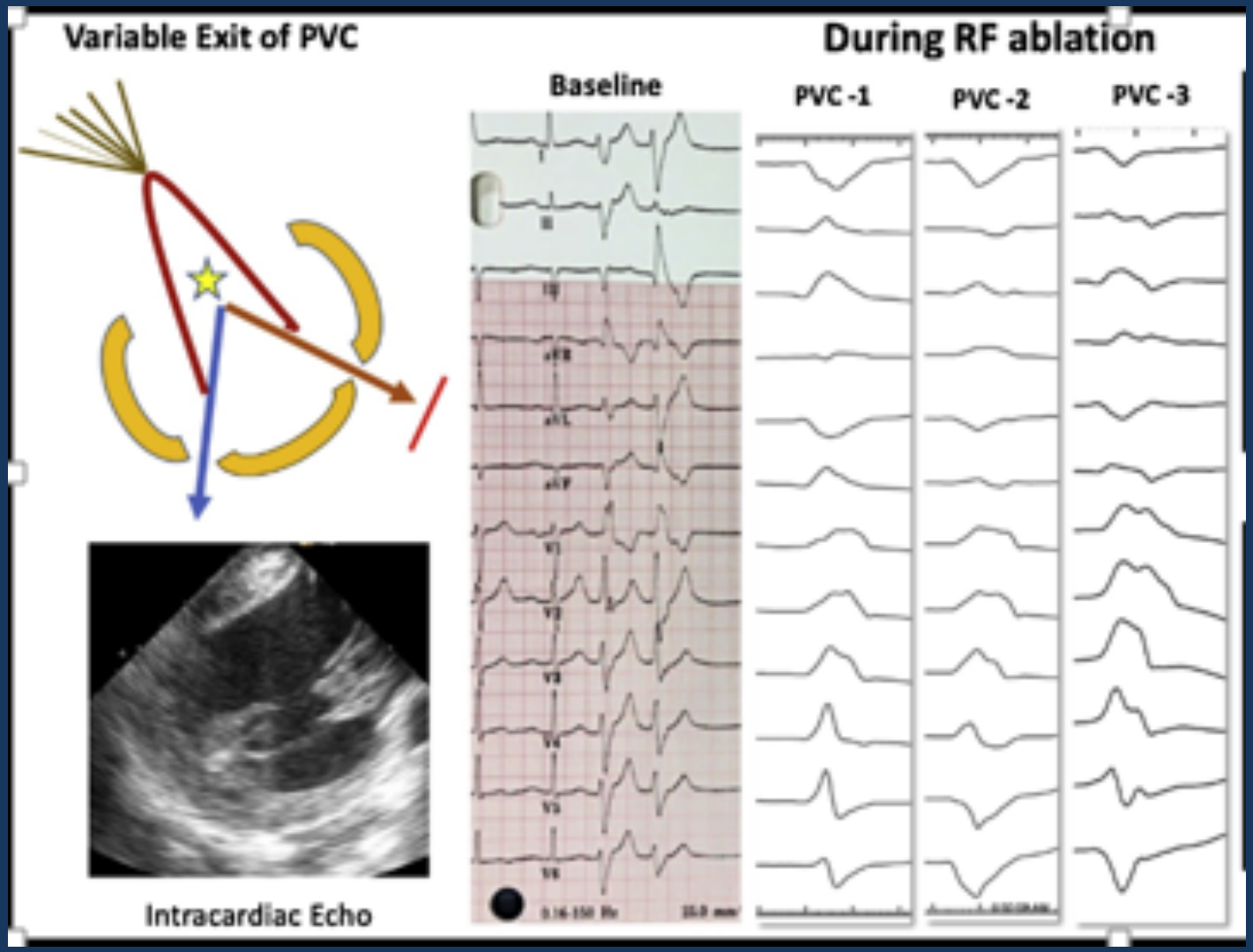

PASO

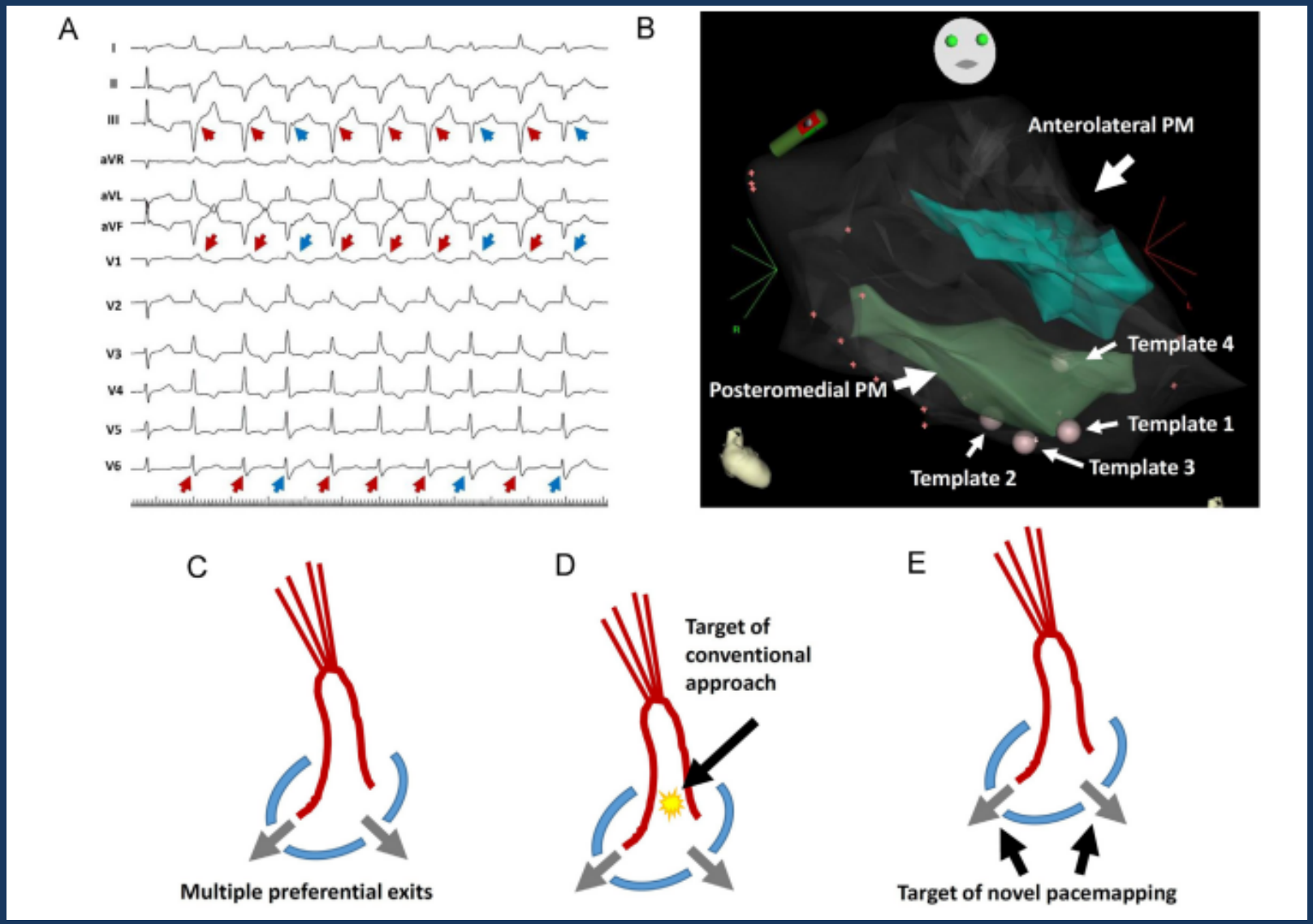

http://dx.doi.org/10.1016/j.hrthm.2016.03.017

latency

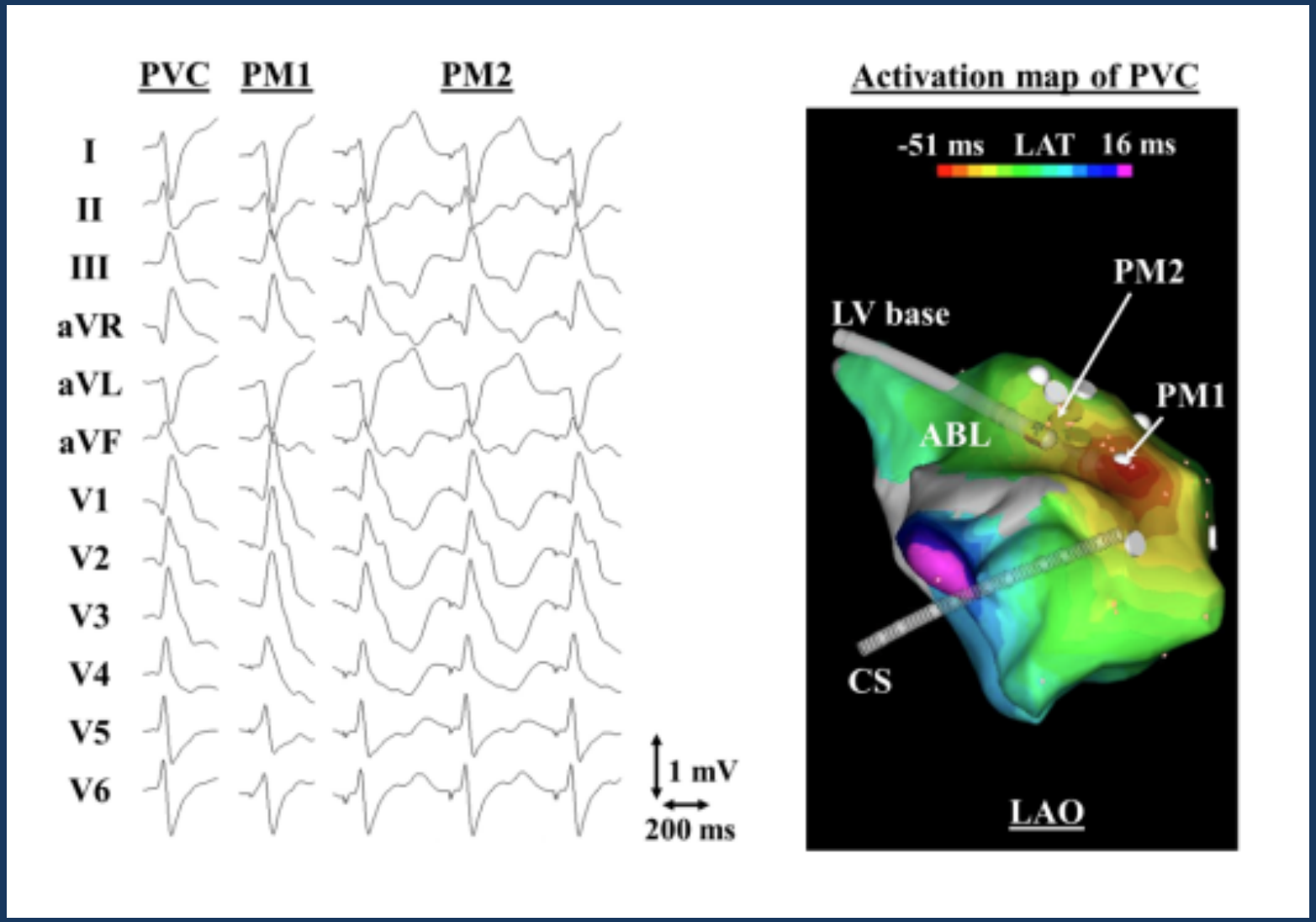

DOI: 10.1111/jce.13487

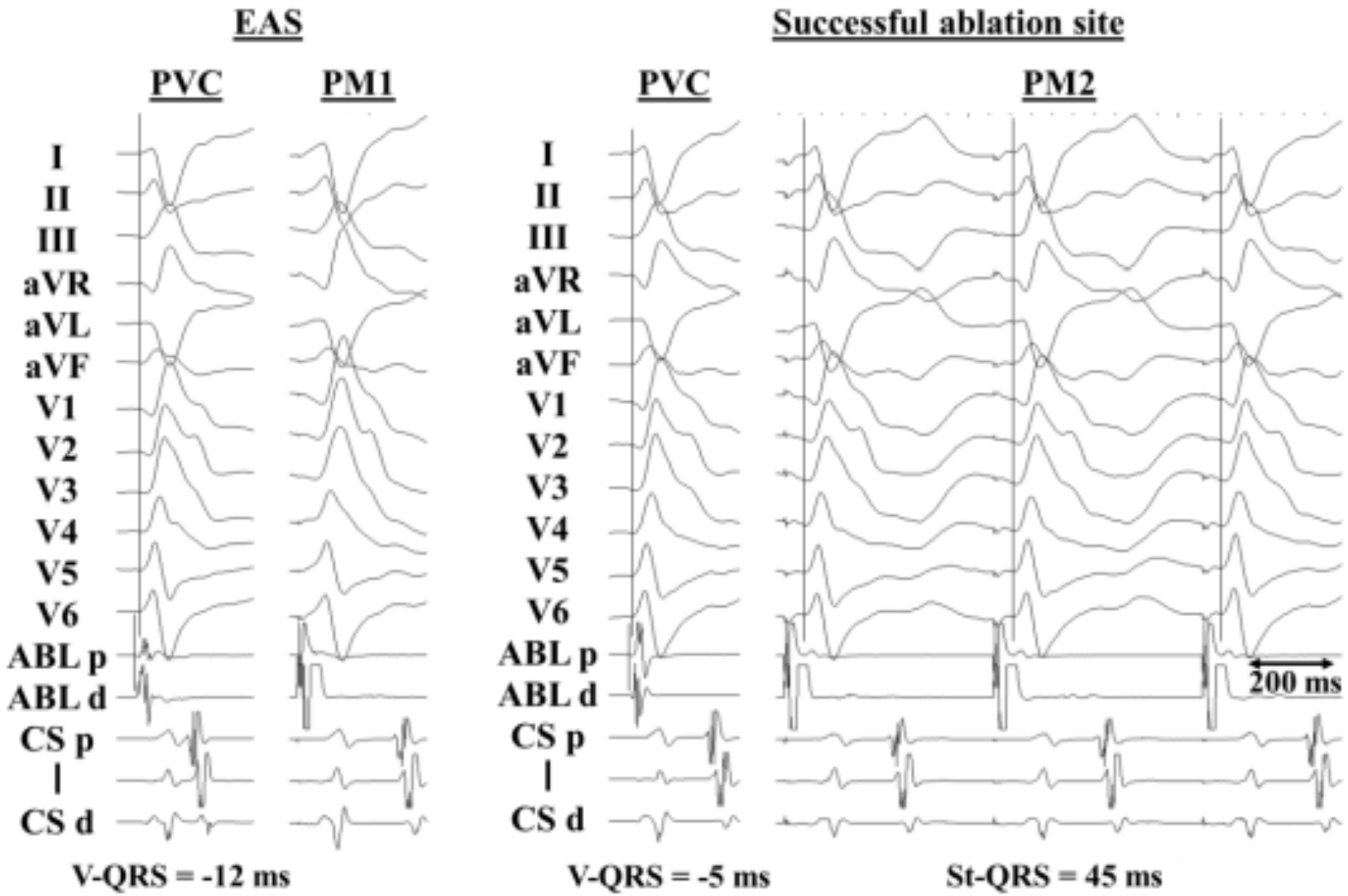
EAS
Successful ablation site
PVC
PM1
PVC
PM2
I
II
III
aVR
aVL
aVF
V1
V2
V3
V4
V5
V6
ABL p
ABL d
CS p
CS d
200 ms
V-QRS = -12 ms
V-QRS = -5 ms
St-QRS = 45 ms

Bipolar ablasyon



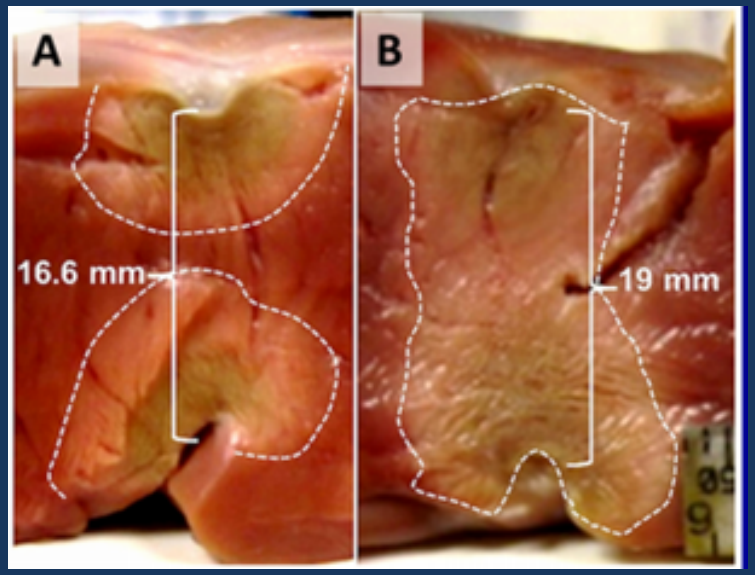

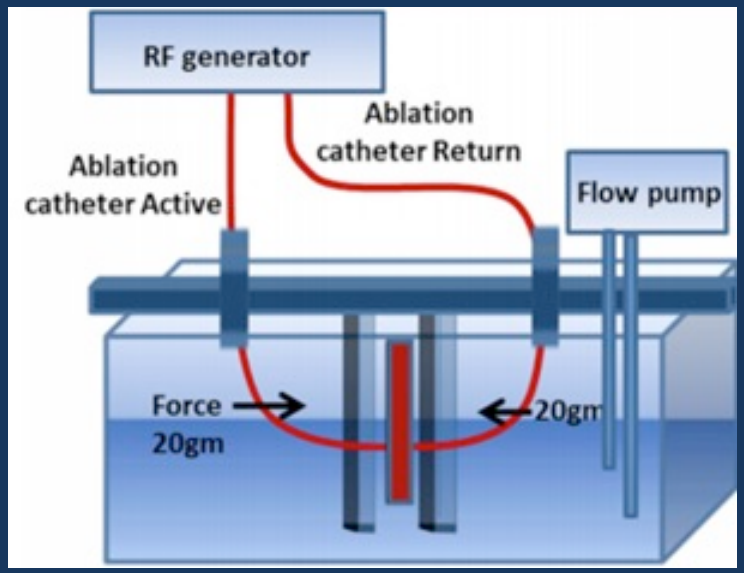


LV
LAO

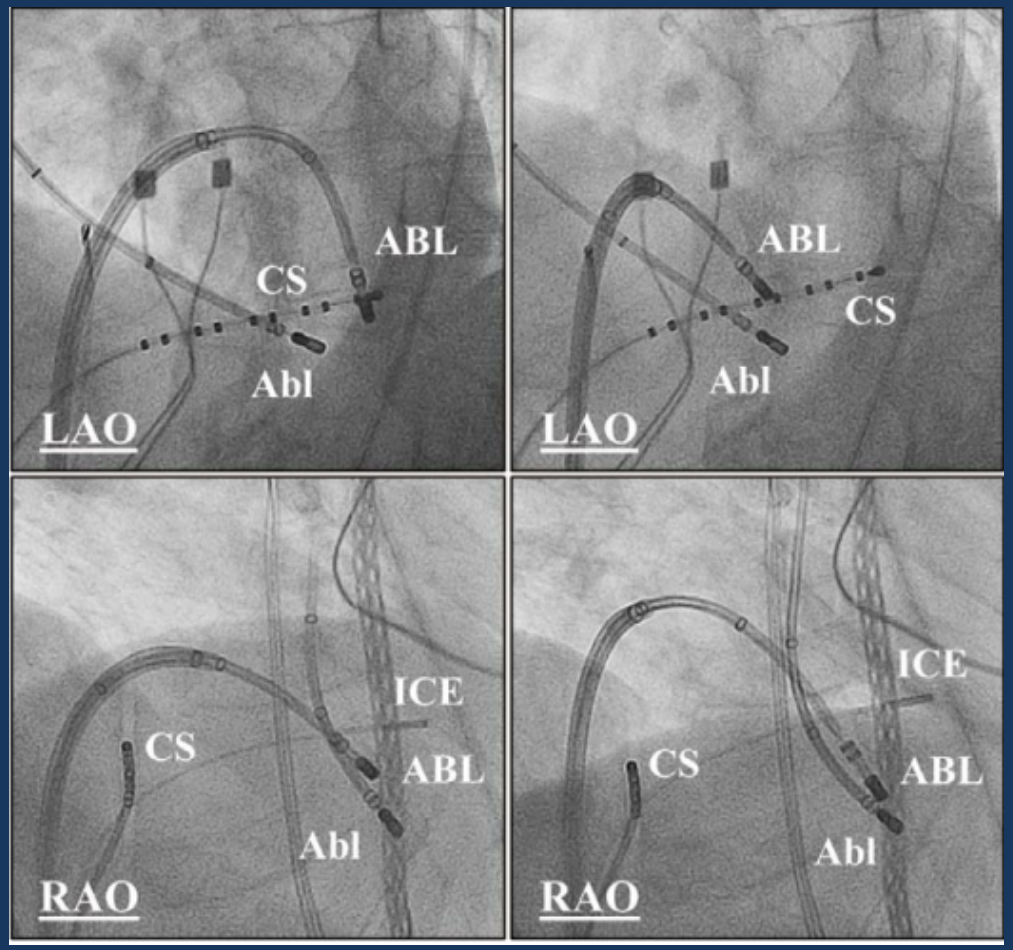
ABL
CS
Abl
LAO
ABL
CS
Abl
LAO
ICE
CS
ABL
Abl
RAO
ICE
CS
ABL
Abl
RAO

Yarı doz Salin

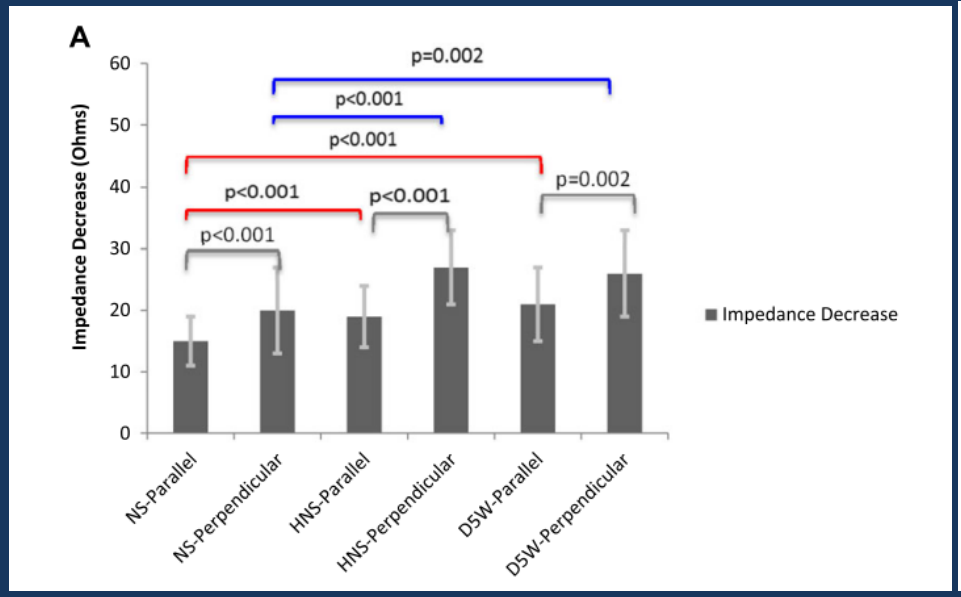

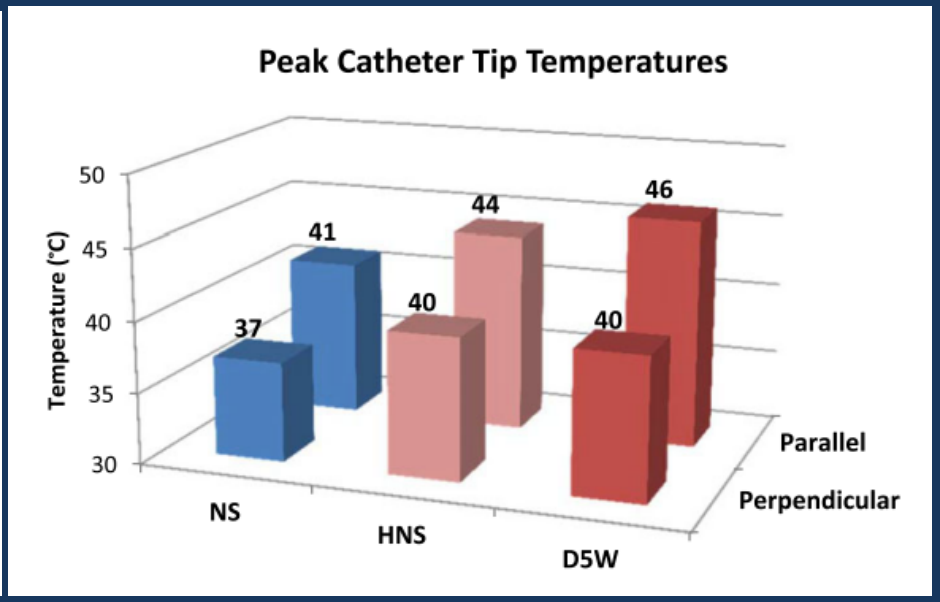

doi: 10.1111/jce.12682

cryoablation

Contact force (+) (-) ?

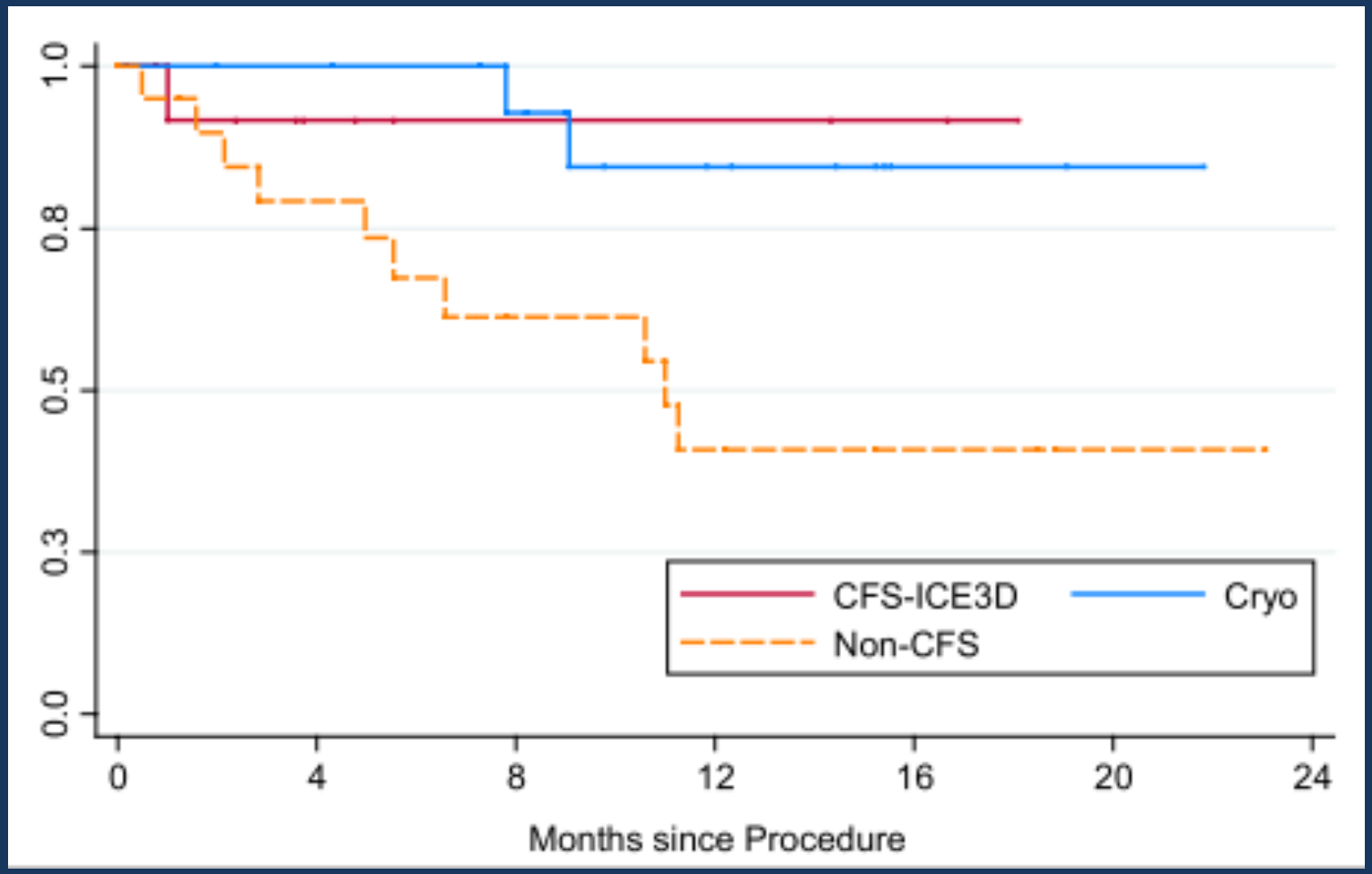

DOI: 10.1002/joa3.12137

Retroaortik ? Transseptal

1 Anterolateral

1 Posteromedial

2 Cryobalon

Yüksek dansiteli haritalama

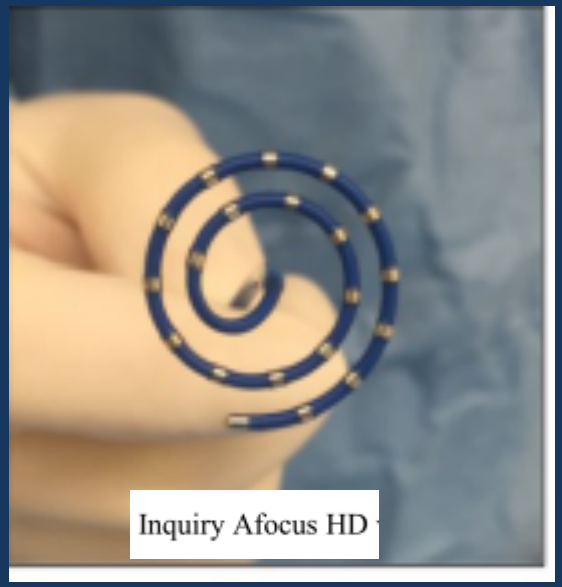

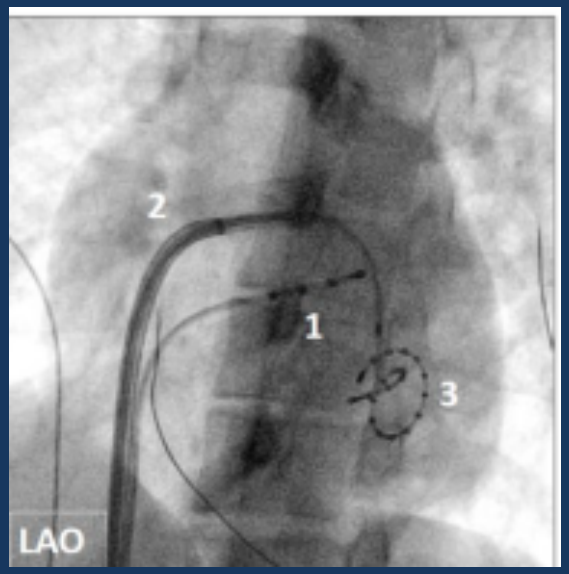

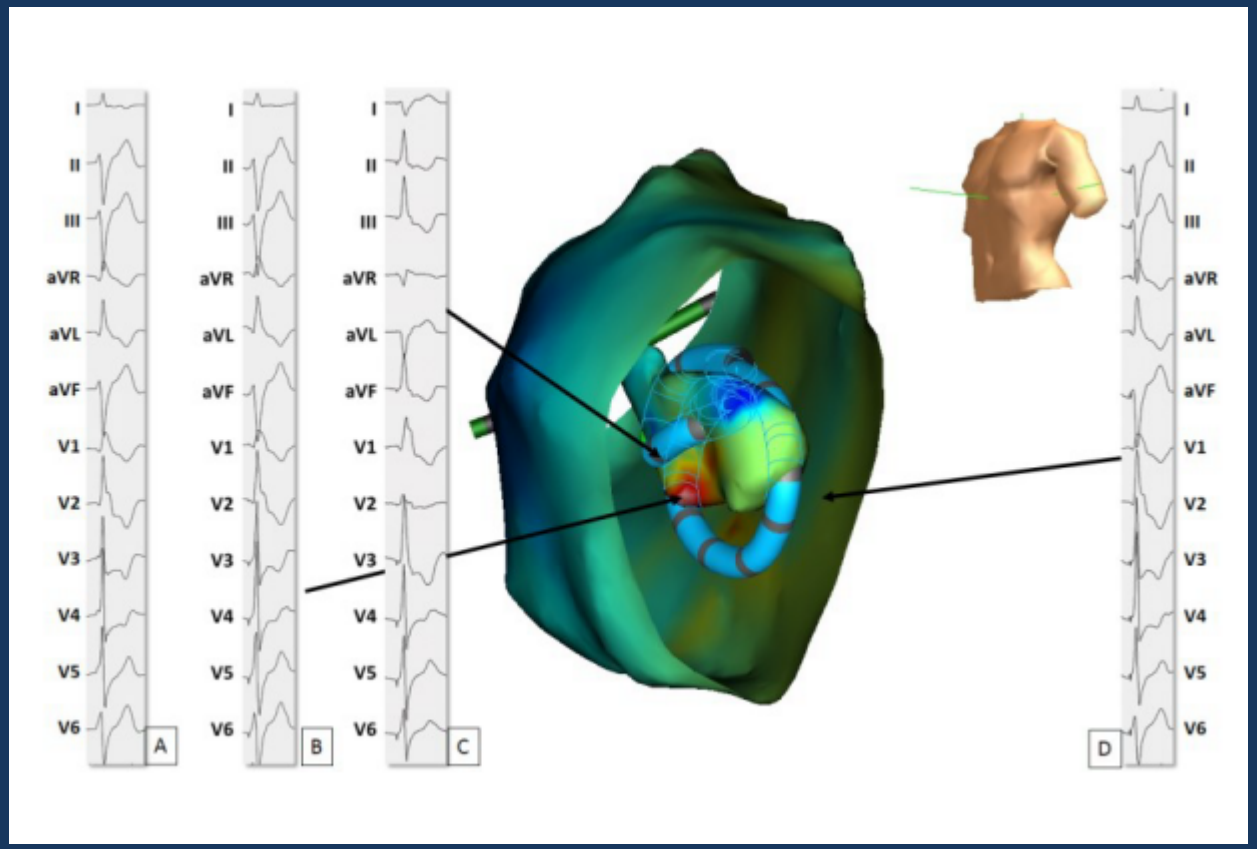

https://doi.org/10.1111/pace.13417

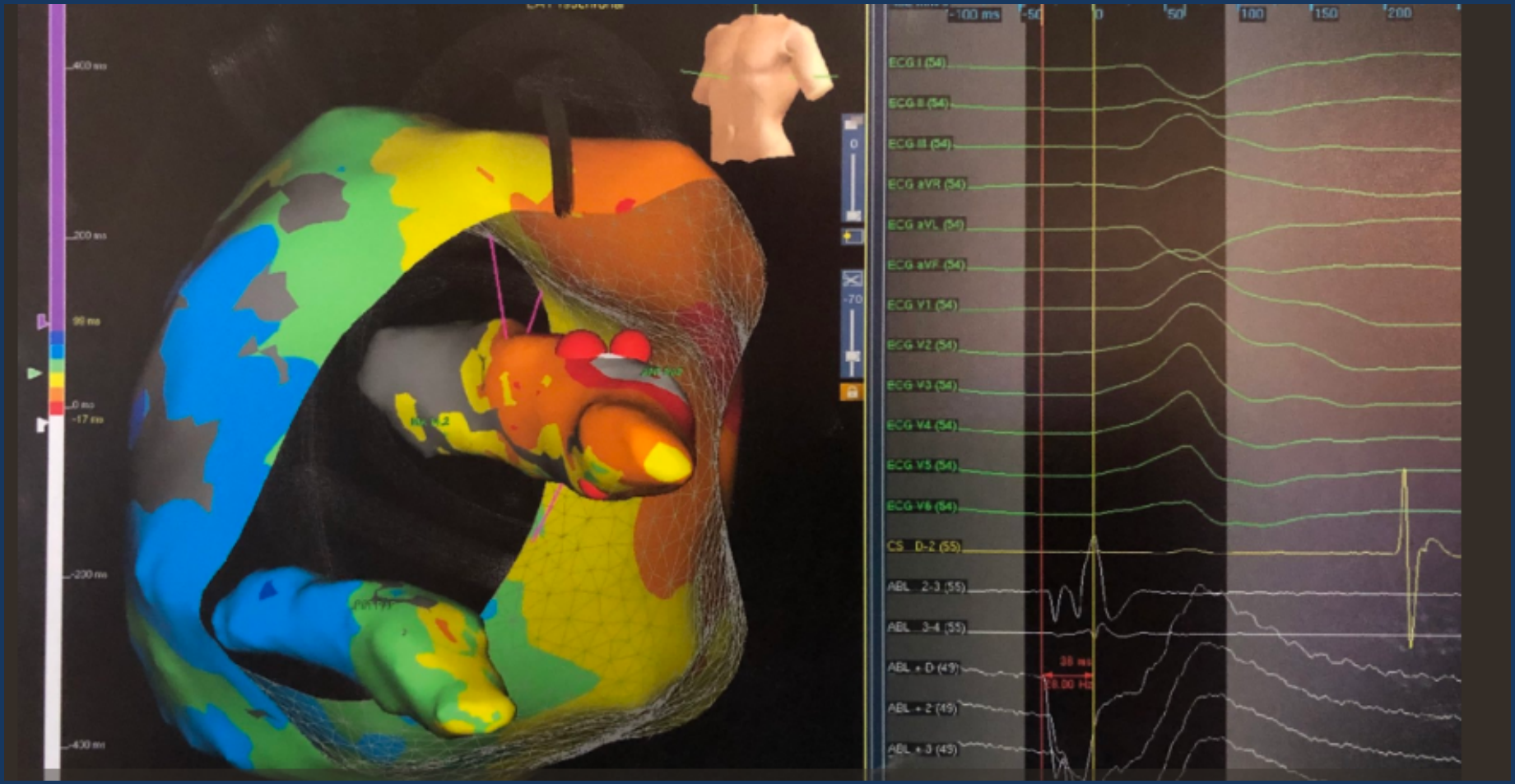
-100 ms
-50
0
50
100
150
200
ECG I (54)
ECG II (54)
ECG III (54)
ECG aVR (54)
ECG aVL (54)
ECG aVF (54)
ECG V1 (54)
ECG V2 (54)
ECG V3 (54)
ECG V4 (54)
ECG V5 (54)
ECG V6 (54)
CS D-2 (55)
ABL 2-3 (55)
ABL 3-4 (55)
ABL + D (49)
ABL + 2 (49)
ABL + 3 (49)
400 ms
200 ms
99 ms
0 ms
-17 ms
-200 ms
-400 ms


LAT Isochronal
400 ms
200 ms
99 ms
0 ms
-17 ms
-200 ms
-400 ms
MA 14.2
PVI PVP
ART PAT
PVI PVP

Robotik haritalama

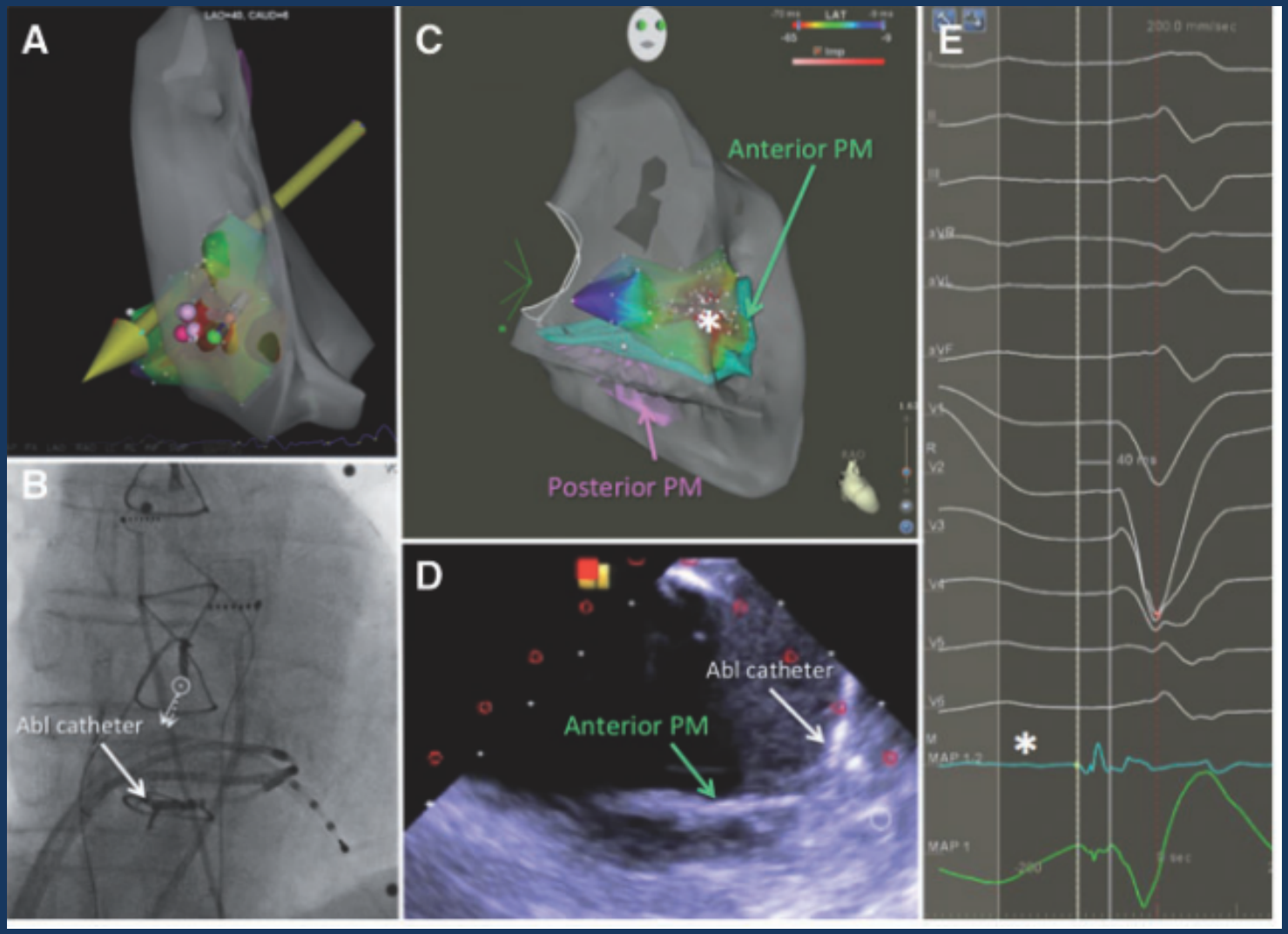

doi:10.1093/europace/eux374

Real time strain ?

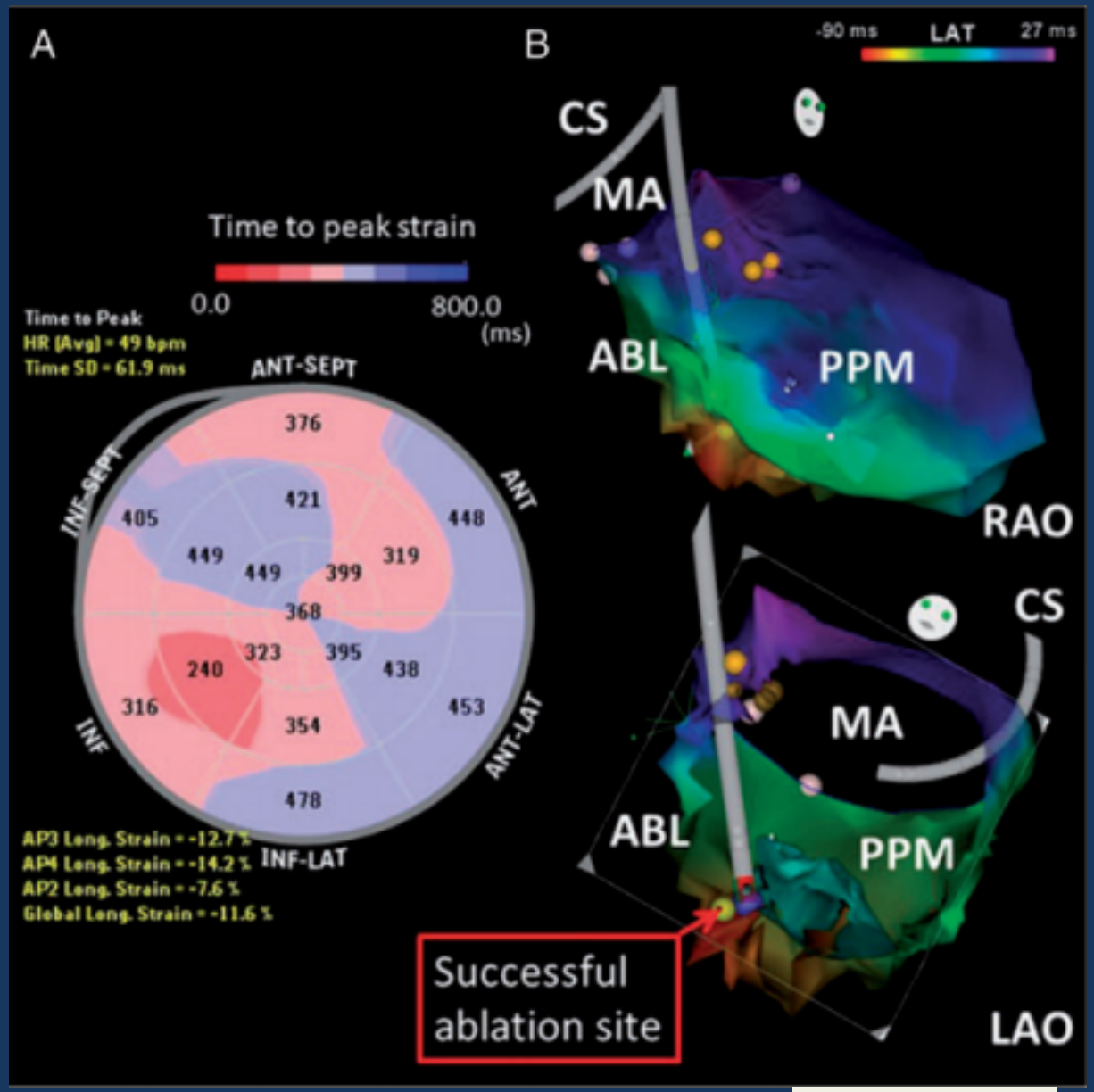

doi:10.1093/europace/euy328

Cerrahi ?

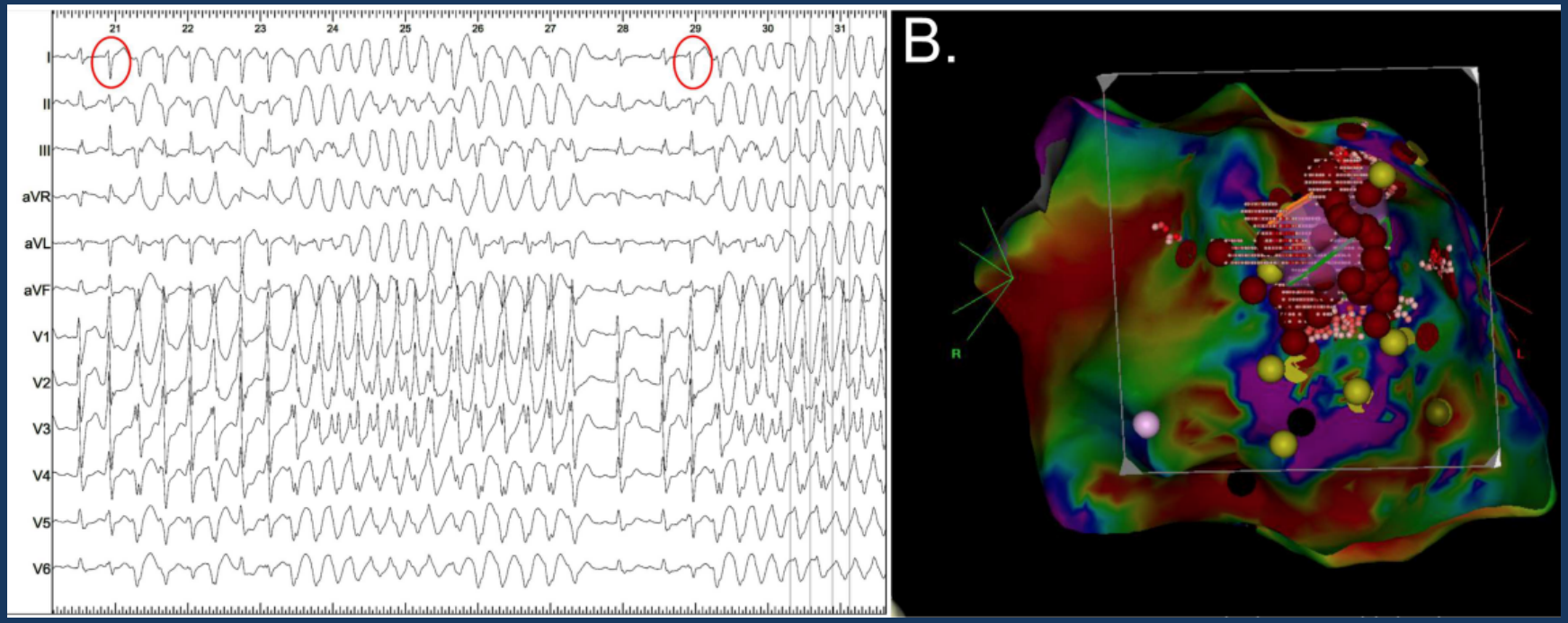
21
22
23
24
25
26
27
28
29
30
31
I
II
III
aVR
aVL
aVF
V1
V2
V3
V4
V5
V6
B.
R
L

Mitral yetersizlik : 2 vaka

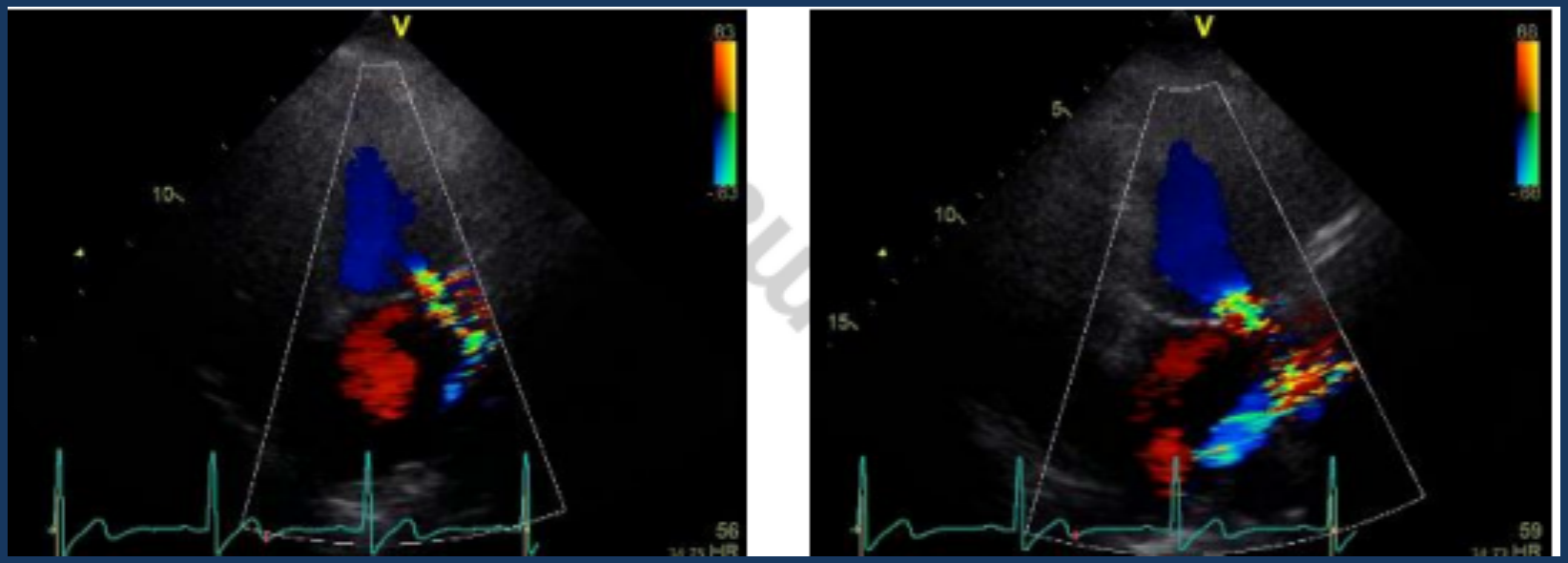

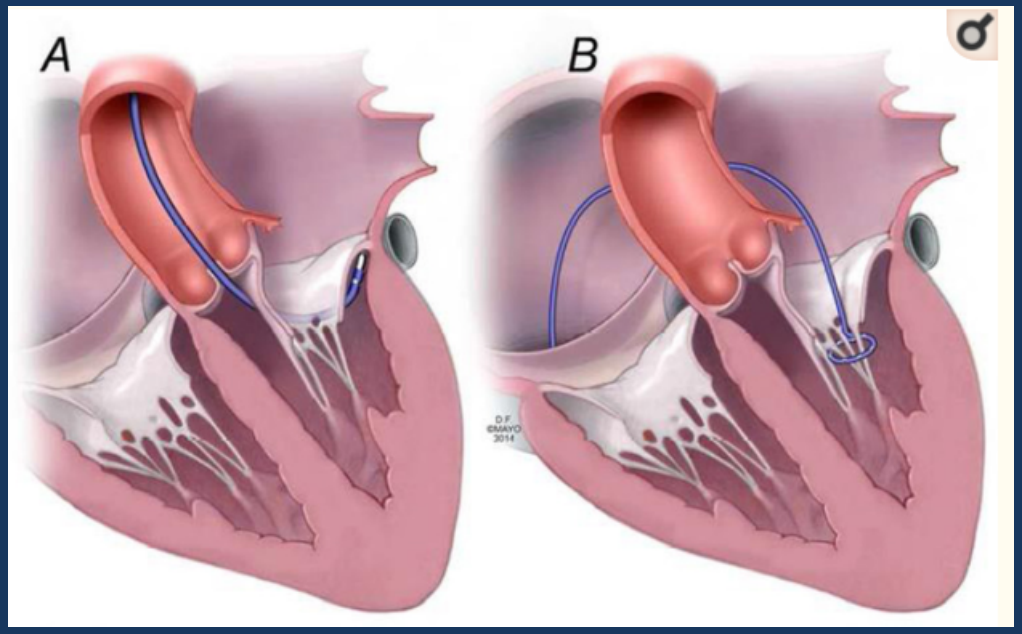

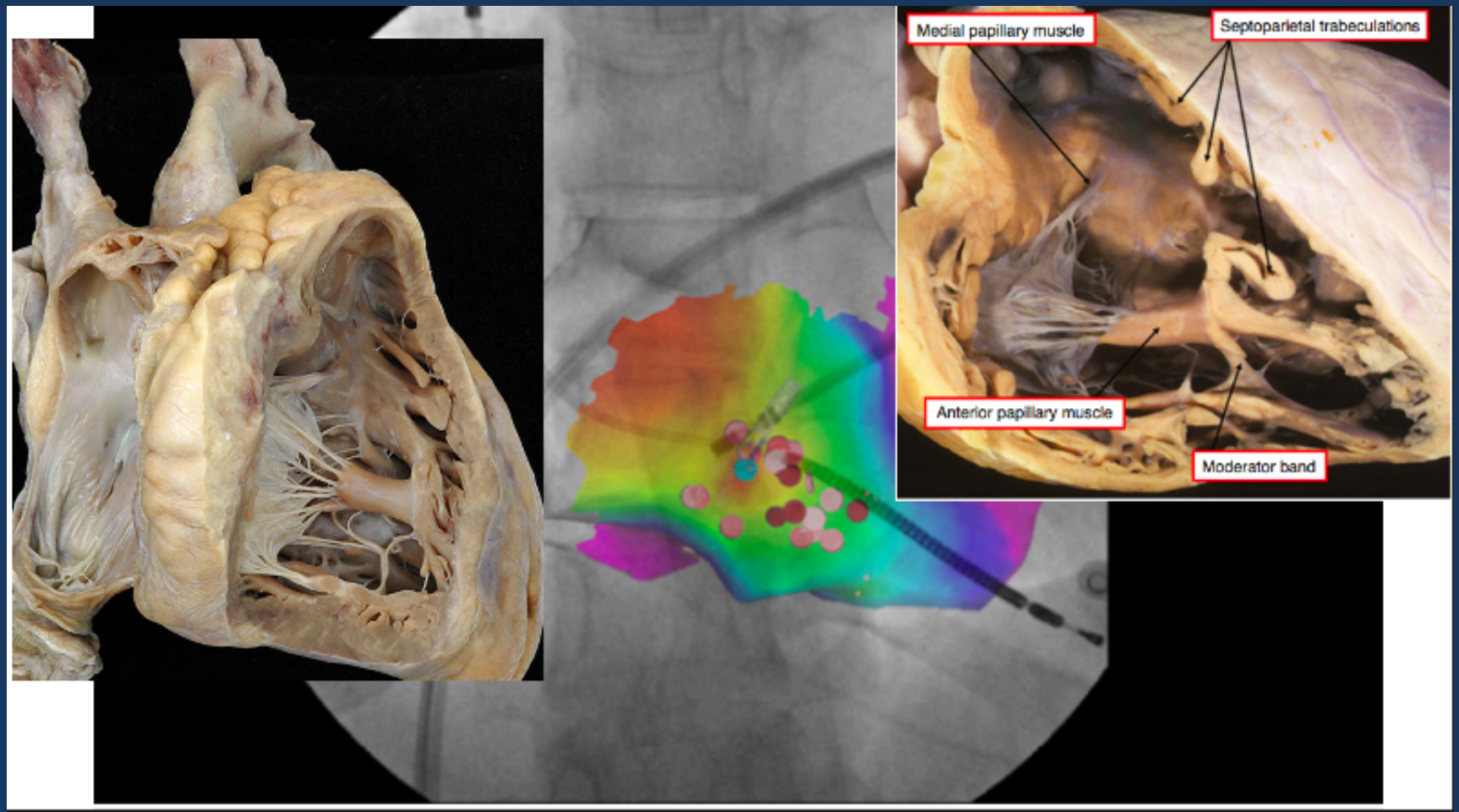
Medial papillary muscle
Septoparietal trabeculations
Anterior papillary muscle
Moderator band