His Bundle uyarımı: Fizyolojik temelleri

Dr. Serkan SAYGI
Medical Park İzmir Hastanesi

SPECIAL COMMUNICATIONS

A technique for ventricular pacing from the His bundle of the intact heart[1]

J Appl Physiol. 1967 Mar;22(3):584-7.

BENJAMIN J. SCHERLAG, BERNARD D. KOSOWSKY, AND ANTHONY N. DAMATO
Cardiopulmonary Laboratory, US Public Health Service Hospital, Staten Island, New York

Permanent, Direct His-Bundle Pacing

A Novel Approach to Cardiac Pacing in Patients With Normal His-Purkinje Activation

Pramod Deshmukh, MD; David A. Casavant, MS;
Mary Romanyshyn, CRNP; Kathleen Anderson, BSN

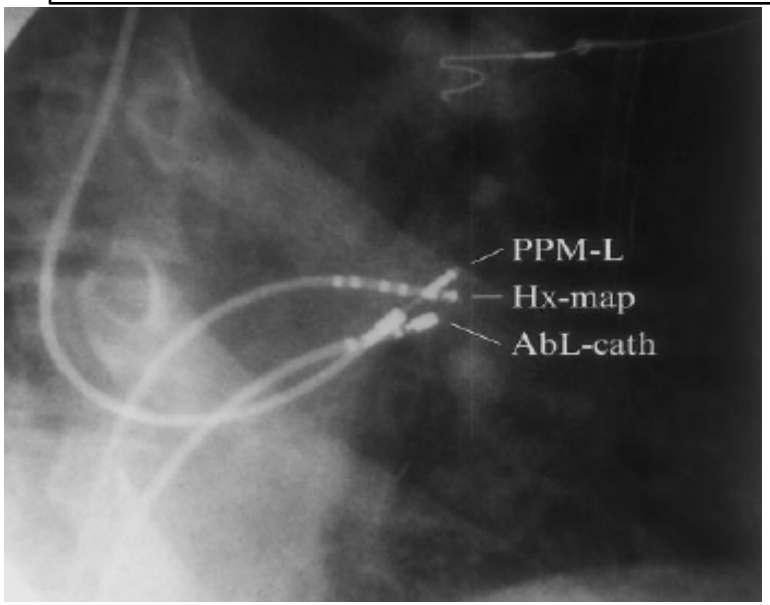

Kalıcı AF-DKMP

Circulation. 2000;101:869-877.

Original Investigations

Clinical Outcomes of His Bundle Pacing Compared to Right Ventricular Pacing

Abdelrahman M, et al. J Am Coll Cardiol. 2018 Mar S0735-1097(18)33478-8

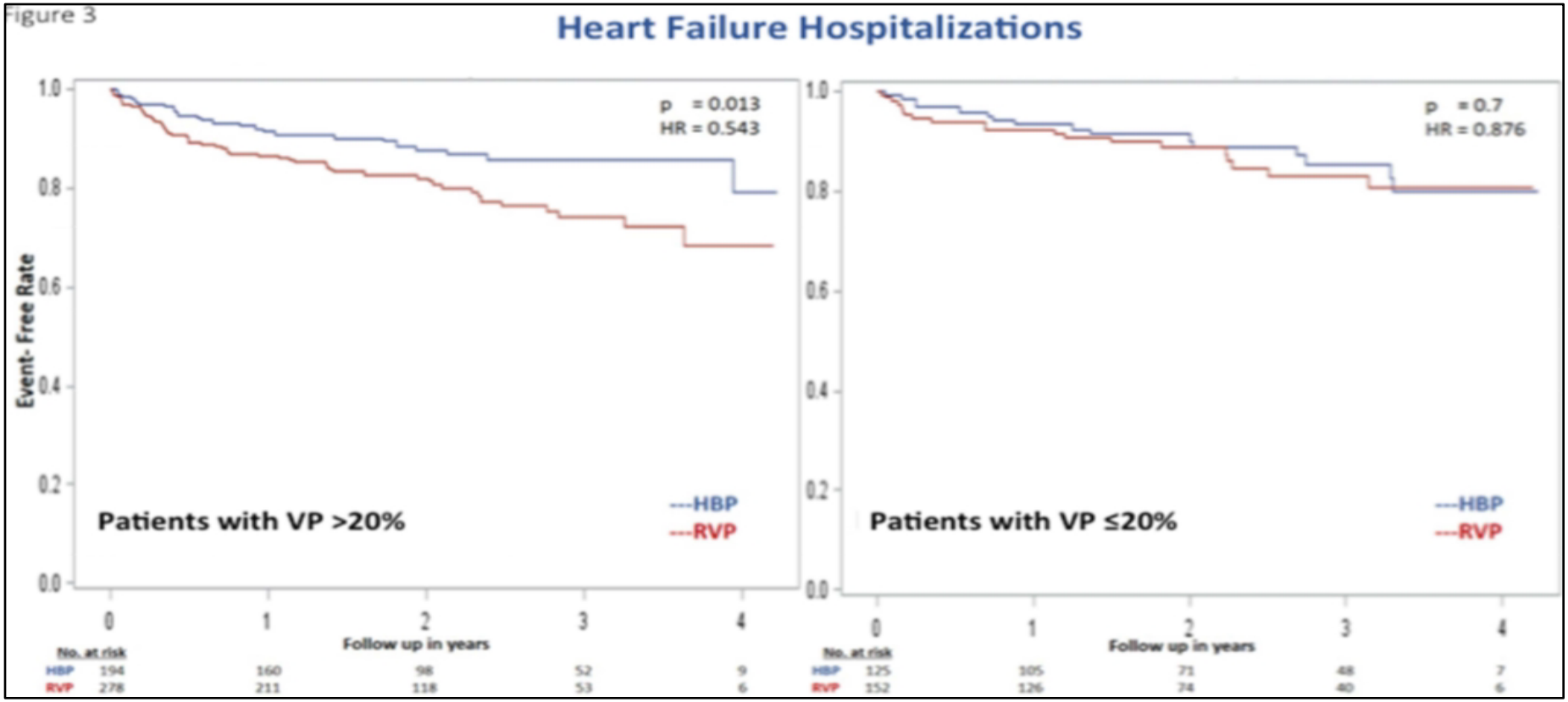

2013-2016➔ 332 HBP; % 91.6 başarı, %37.8 SHBP

2018 ACC/AHA/HRS Guideline on the Evaluation and Management of Patients With Bradycardia and Cardiac Conduction Delay

IIa	B-R[SR]	4. In patients with atrioventricular block who have an indication for permanent pacing with a LVEF between 36% and 50% and are expected to require ventricular pacing more than 40% of the time, it is reasonable to choose pacing methods that maintain physiologic ventricular activation (e.g., cardiac resynchronization therapy [CRT] or His bundle pacing) over right ventricular pacing (S6.4.4.1-7, S6.4.4.1-11–S6.4.4.1-19).
IIa	B-R	5. In patients with atrioventricular block who have an indication for permanent pacing with a LVEF between 36% and 50% and are expected to require ventricular pacing less than 40% of the time, it is reasonable to choose right ventricular pacing over pacing methods that maintain physiologic ventricular activation (e.g., CRT or His bundle pacing) (S6.4.4.1-15, S6.4.4.1-16, S6.4.4.1-20, S6.4.4.1-21).
IIb	B-R[SR]	6. In patients with atrioventricular block at the level of the atrioventricular node who have an indication for permanent pacing, His bundle pacing may be considered to maintain physiologic ventricular activation (S6.4.4.1-19, S6.4.4.1-22–S6.4.4.1-25).

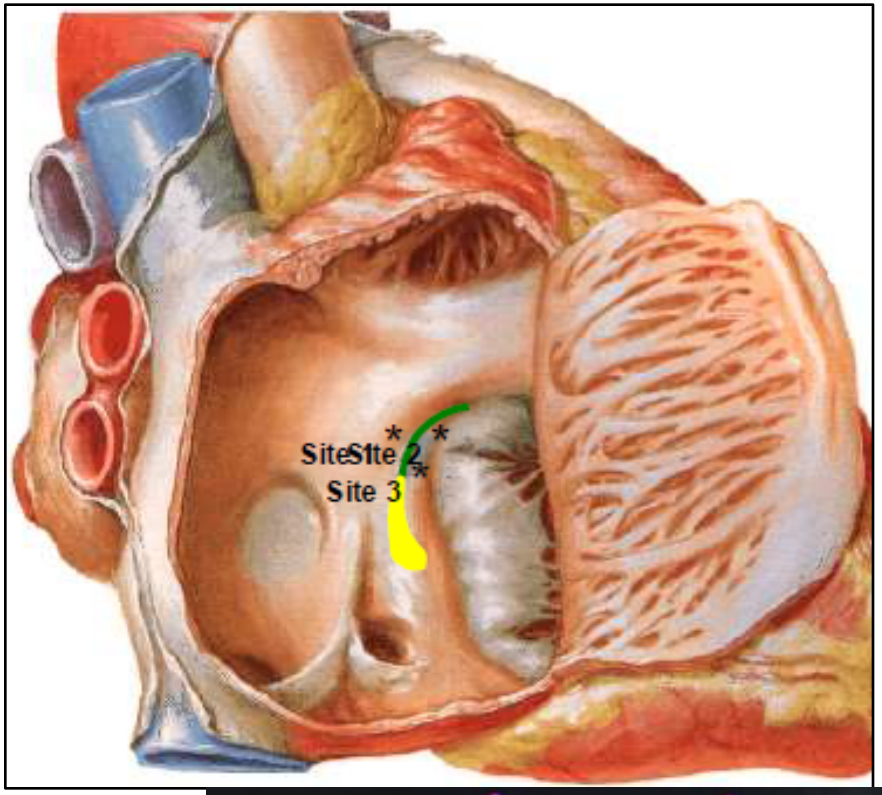
Site 1
Site 2
Site 3

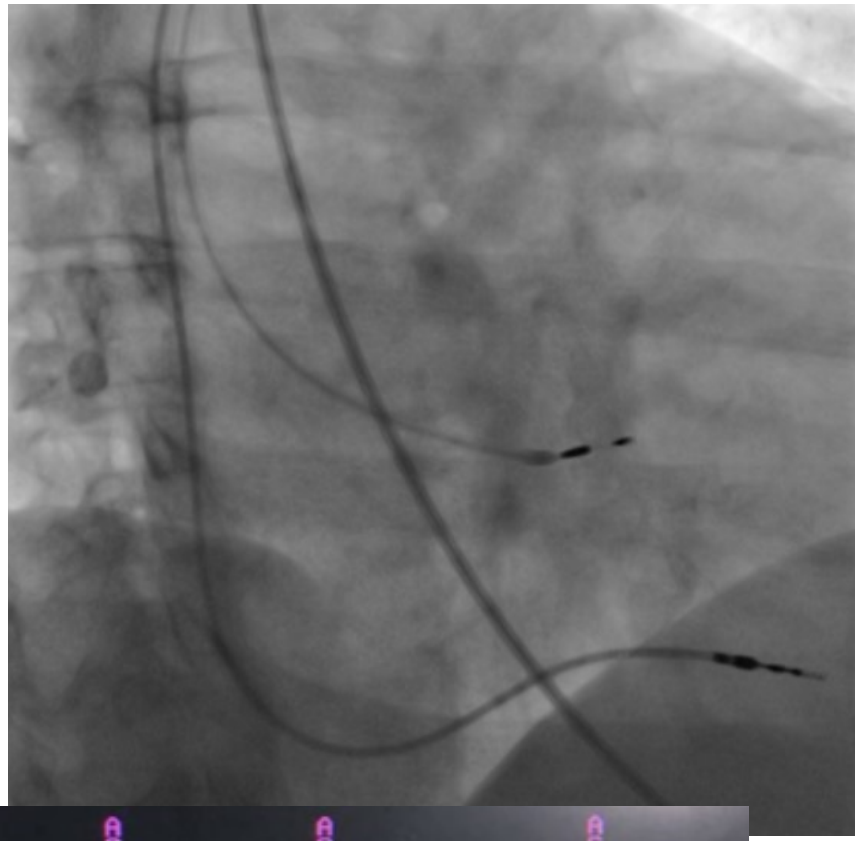

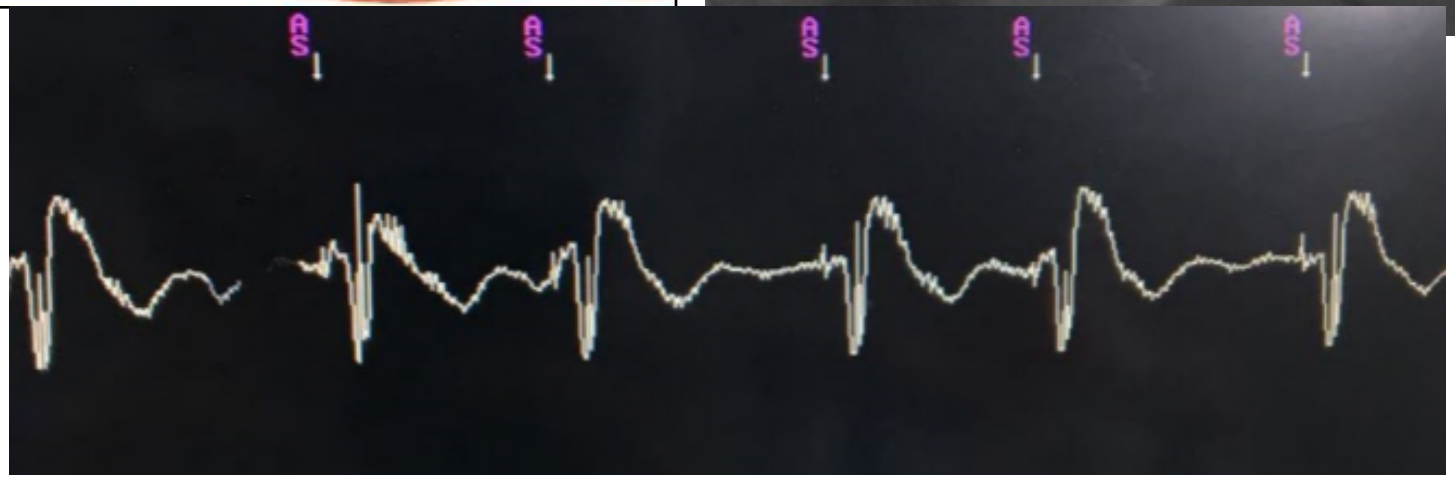
AS
AS
AS
AS
AS

Supra Hisian AV blok

Non-selektif HBP

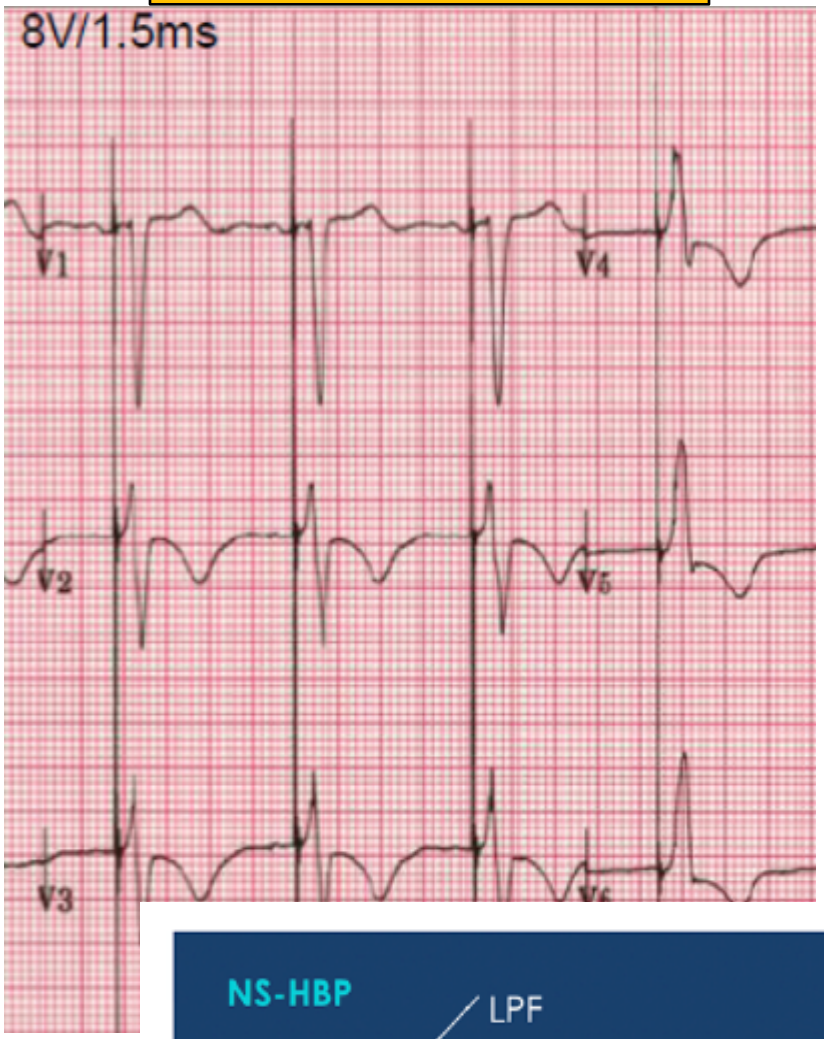

Selektif HBP

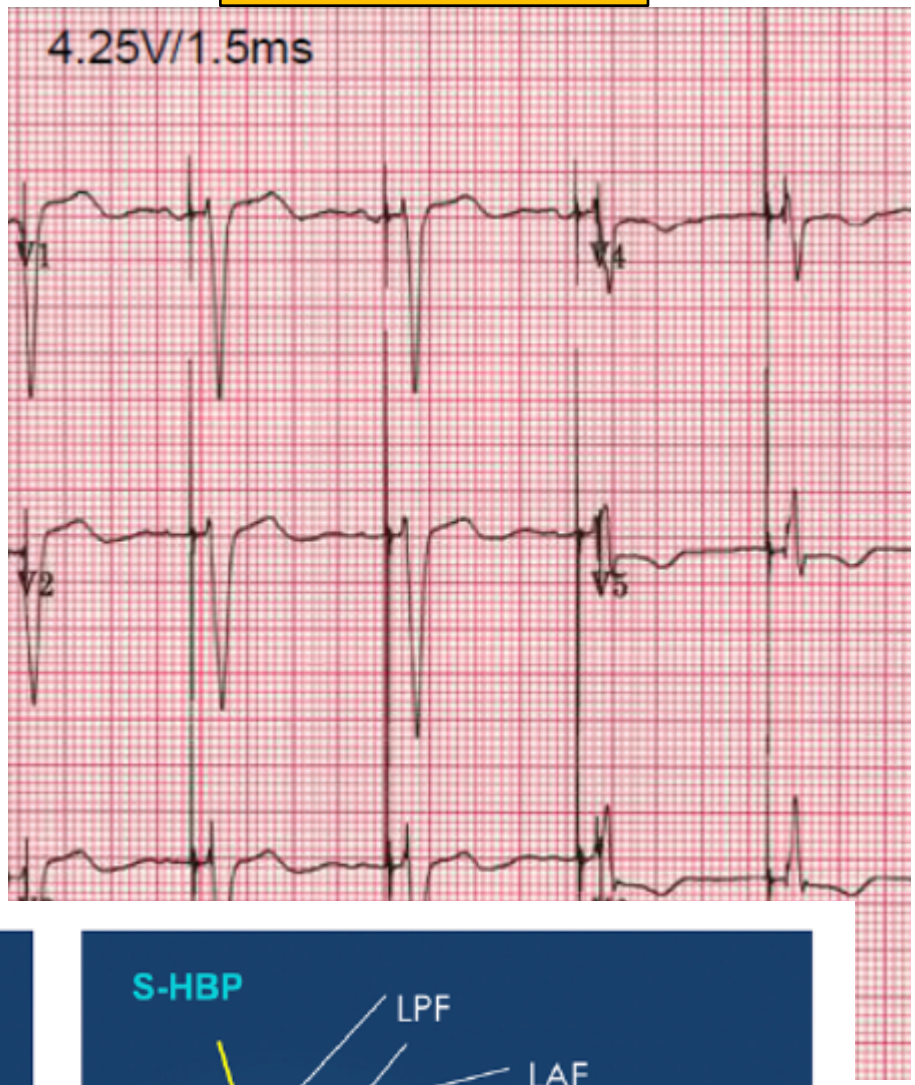

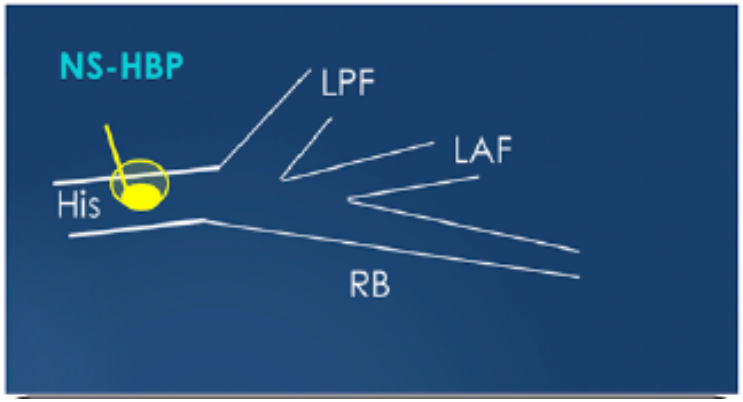

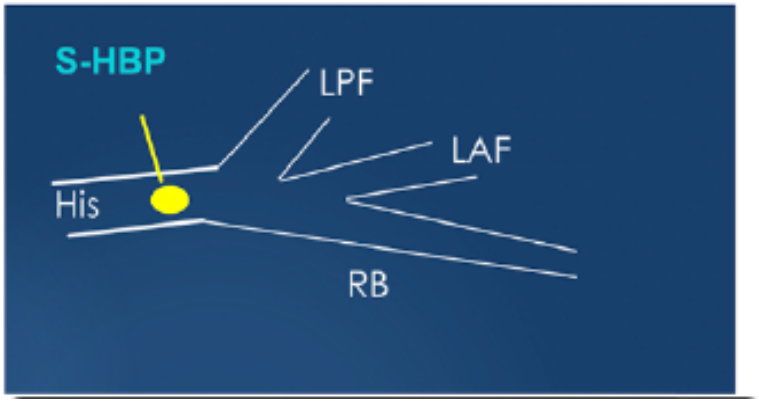

Novel Method for Assessment of His Bundle Pacing Morphology Using Near Field and Far Field Device Electrograms

Circ Arrhythm Electrophysiol. 2019;12:e006878. DOI: 10.1161/CIRCEP.118.006878

NS HBP

NF EGM negative (red)

NF $_{\text{Time to peak}}$ = 20ms (red)

FF $_{\text{QRSd}}$ = 126ms (blue)

S HBP

FF $_{\text{QRSd}}$= 86ms (blue) → Far field

AEGM

NF EGM positive (red) → Near Field

NF Time to peak =50ms

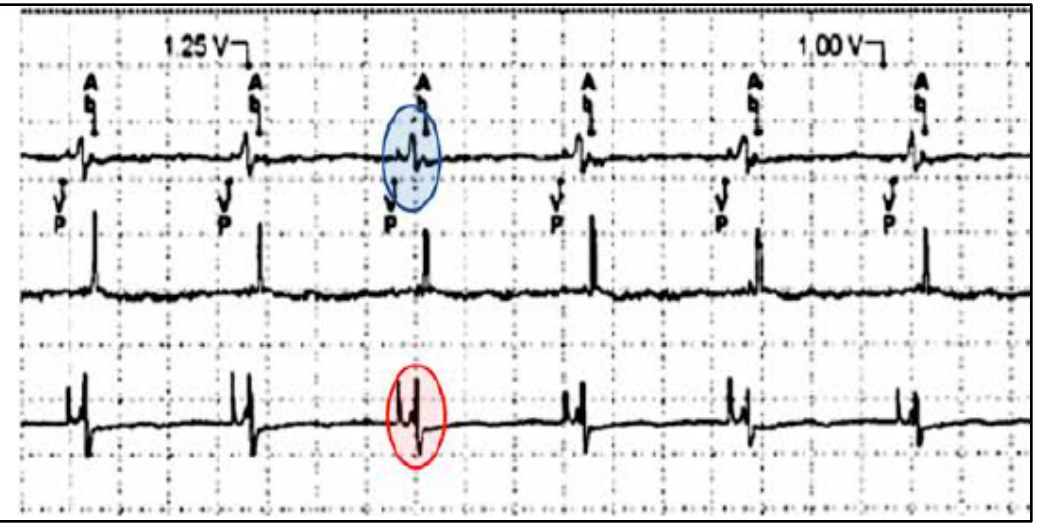

Programmed His Bundle Pacing

A Novel Maneuver for the Diagnosis of H

Circ Arrhythm Electrophysiol. 2019;12:e007052. D

NS HBP

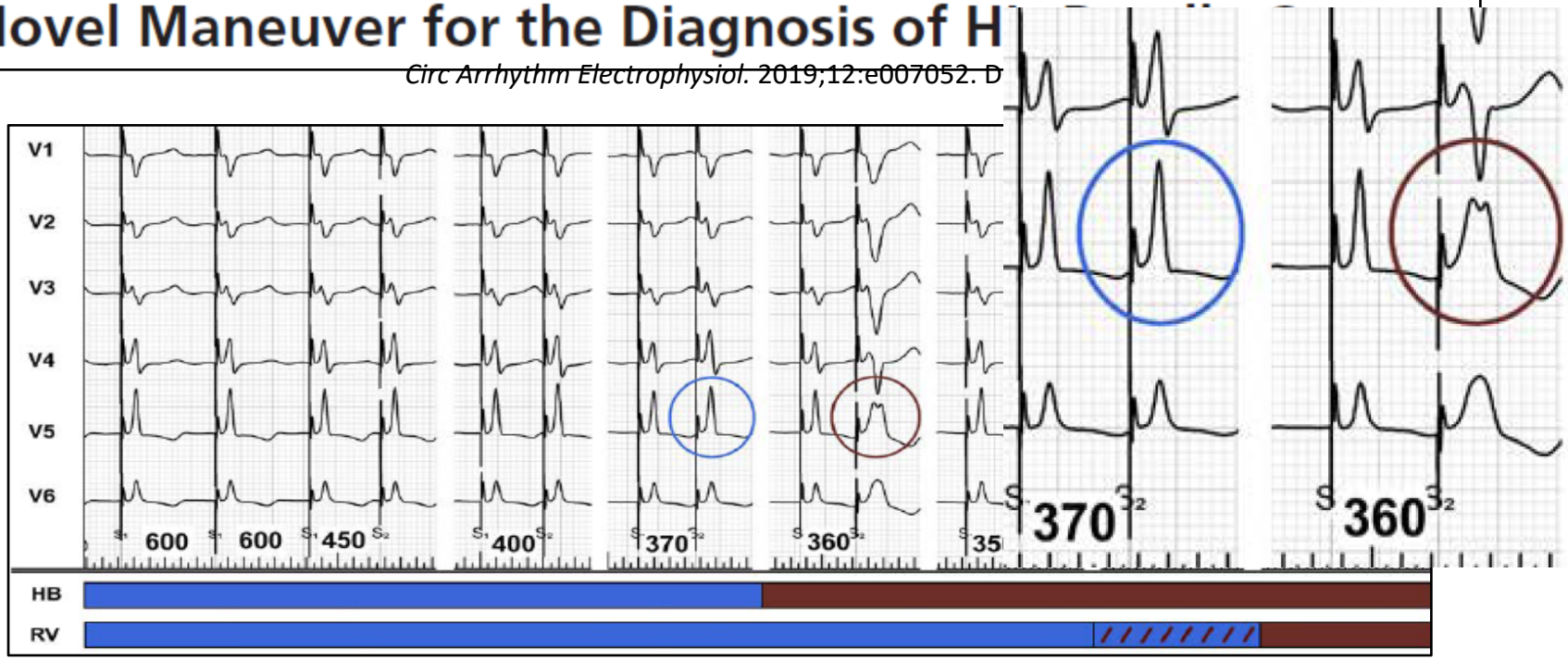

Pseudo NS HBP

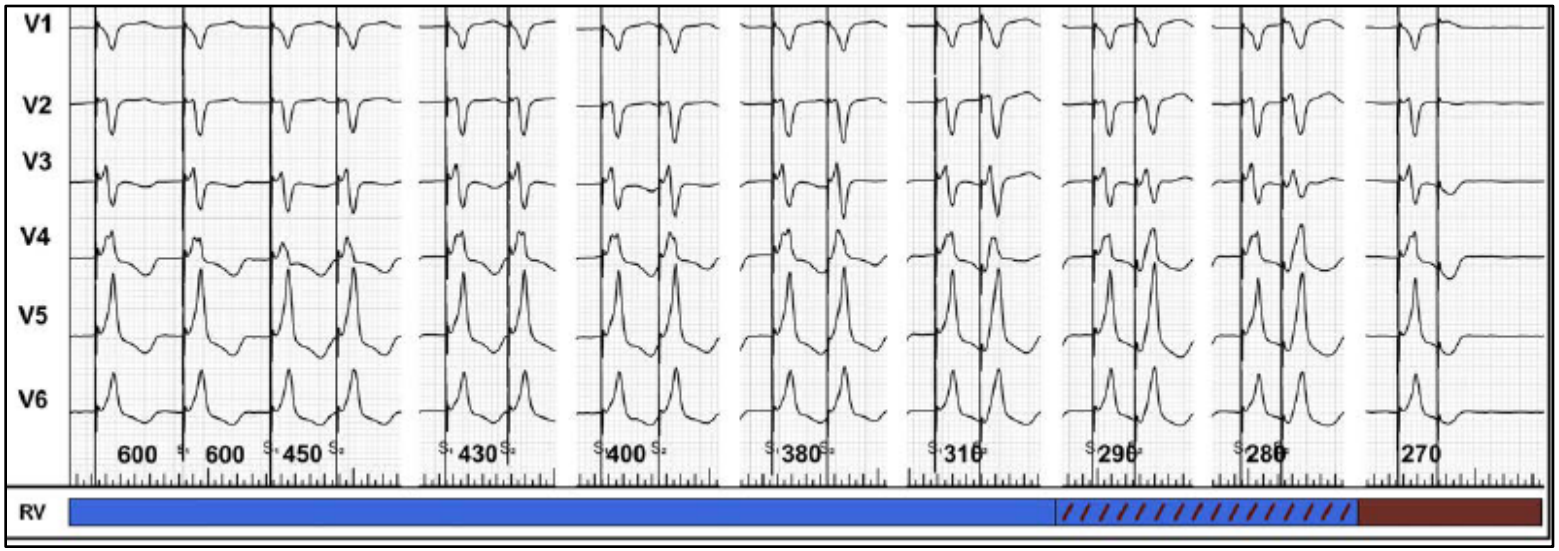

İnfra-Hisian/Dal bloklarında His pacing

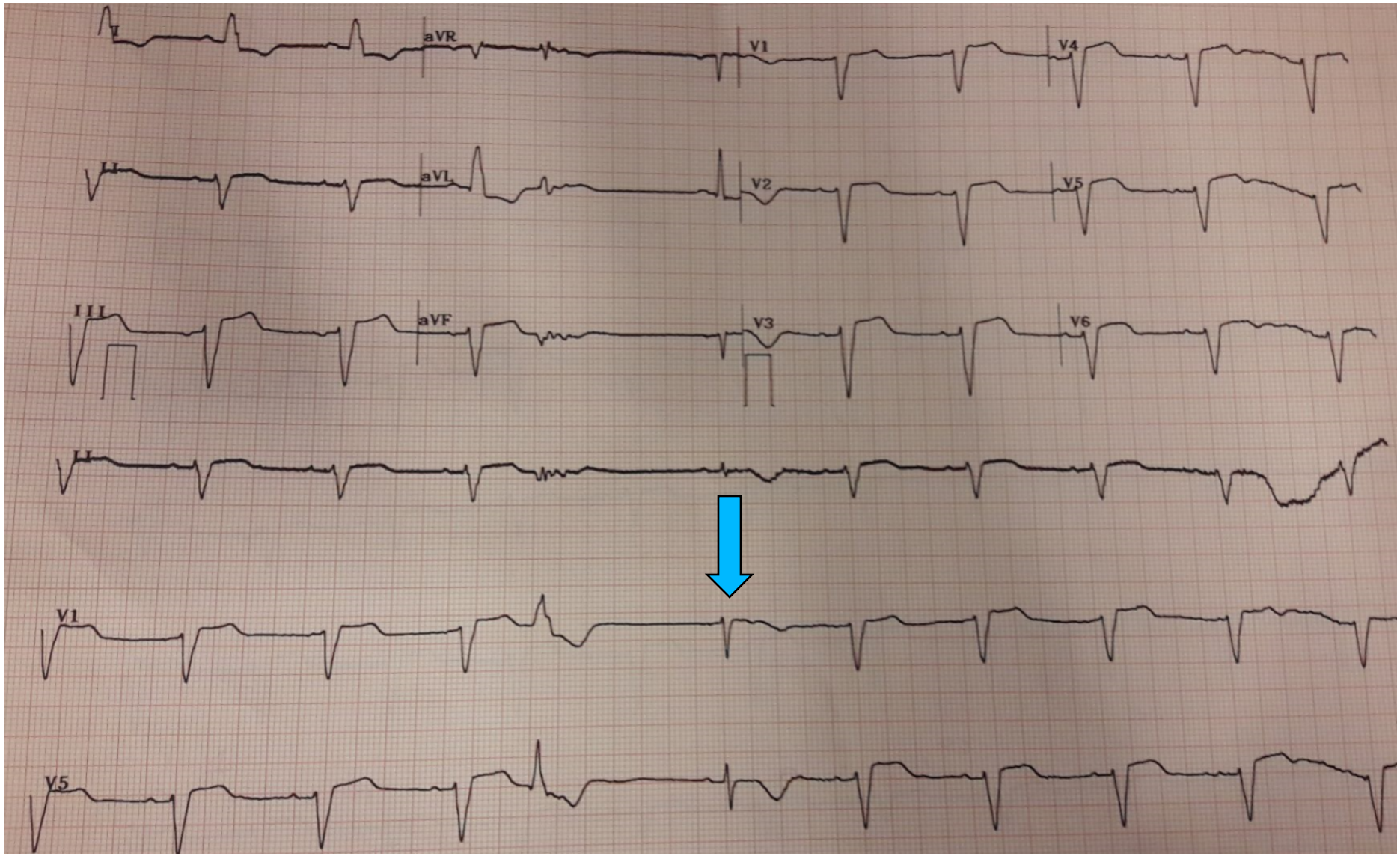

Dal bloklarında His pacing

Normalization of Bundle Branch Block Patterns by Distal His Bundle Pacing

Clinical and Experimental Evidence of Longitudinal Dissociation in the Pathologic His Bundle

Nabil El-Sherif, M.D., Fernando Amat-Y-Leon, M.D., Clyde Schonfield, M.D., Benjamin J. Scherlag, Ph.D., Kenneth Rosen, M.D., Ralph Lazzara, M.D., and Christopher Wyndham, M.D.

Circulation. 1978;57:473-483

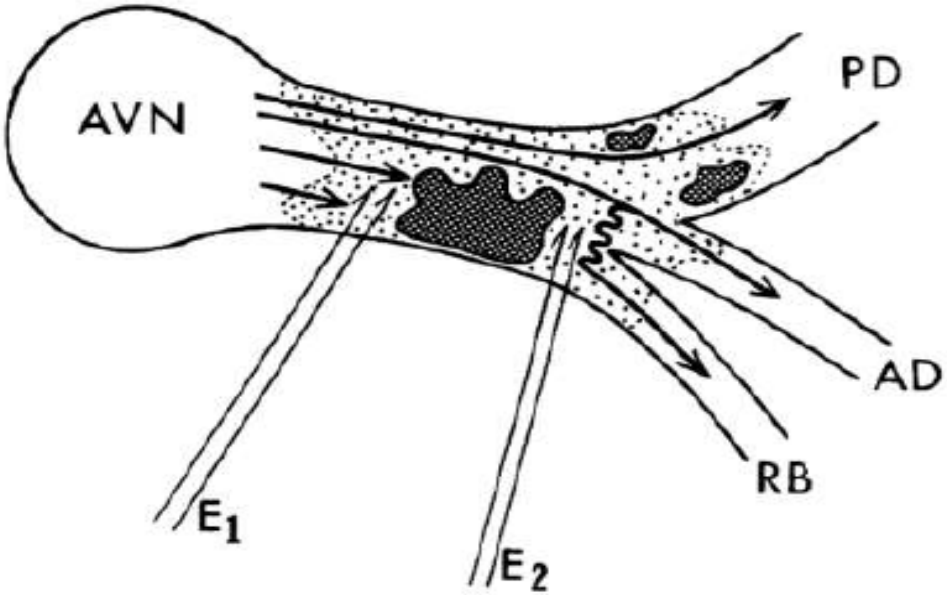

Longitudinal Dissociation in the His Bundle

Bundle Branch Block due to Asynchronous Conduction within the His Bundle in Man

ONKAR S. NARULA, M.D.

CIRCULATION VOL 56, NO 6, DECEMBER 1977

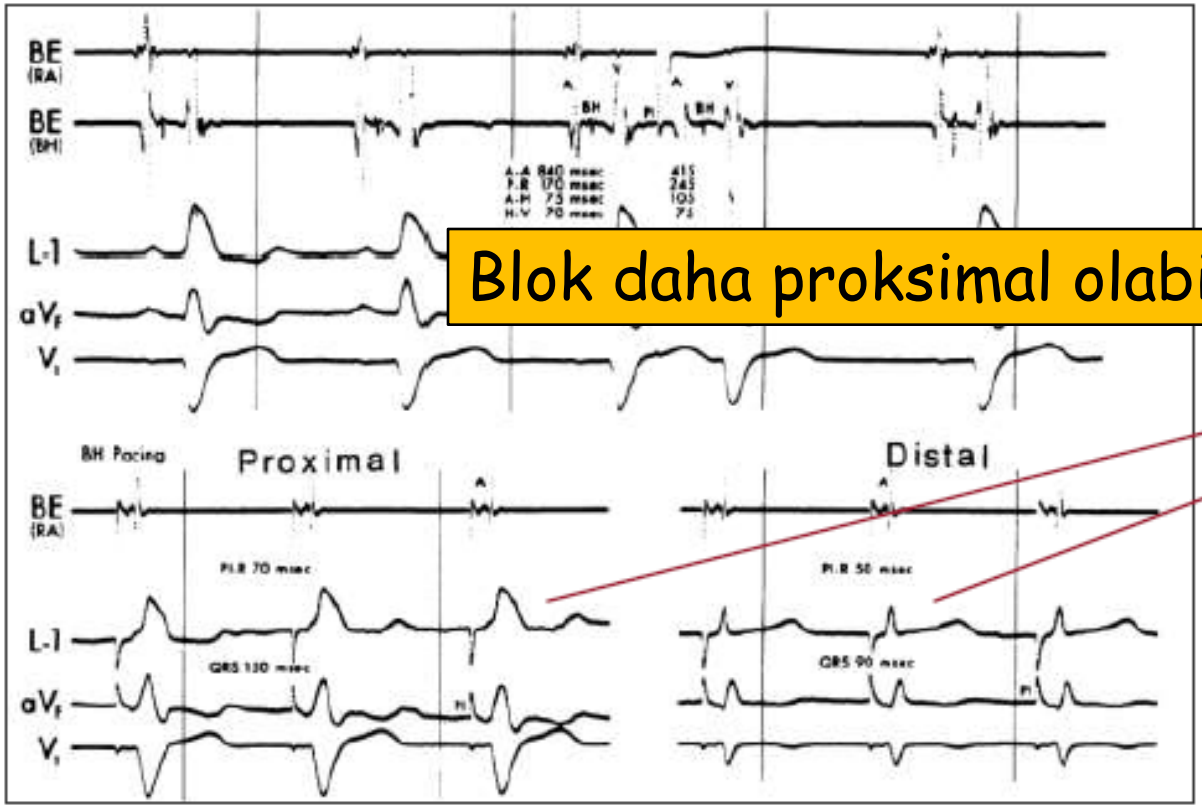

Blok daha proksimal olabilir?

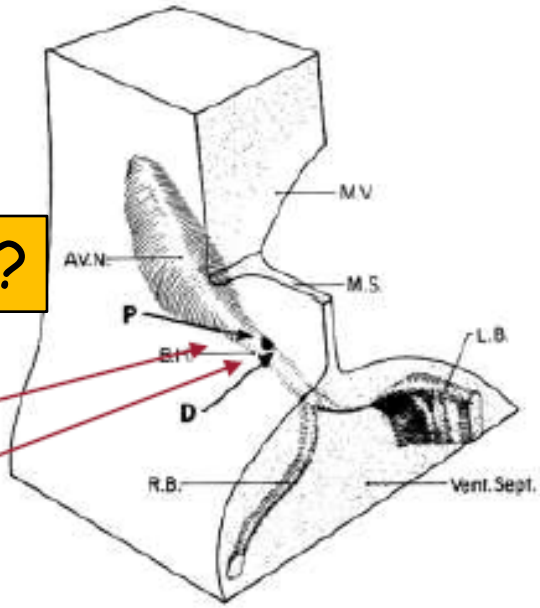

Permanent His-Bundle pacing in a patient with advanced conduction system disease: What is the mechanism of QRS narrowing?

a N, Knight BP

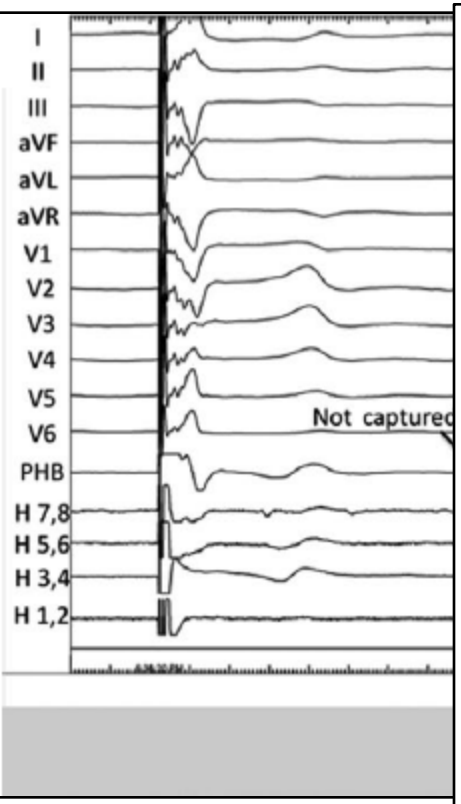

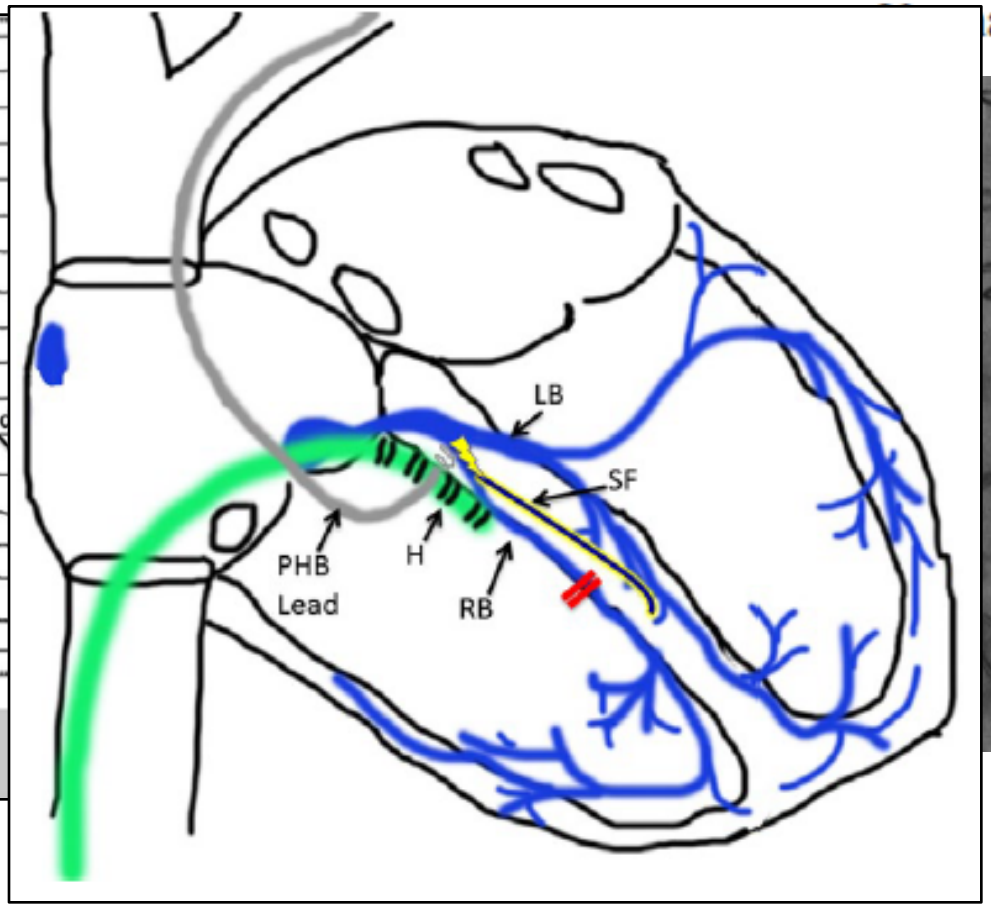

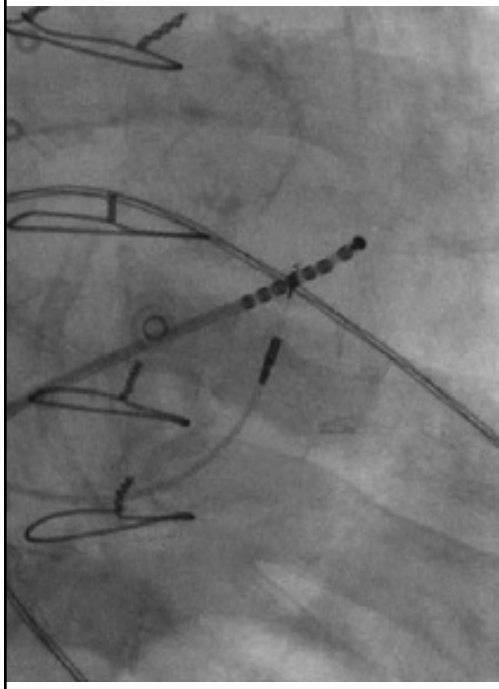

Septal fasikül?

Clin Case Rep 2018;6:1236–1240

Intracardiac Delineation of Septal Conduction in Left Bundle Branch Block Patterns: Mechanistic Evidence of Left Intra-Hisian Block Circumvented by His Pacing

Gaurav A. Upadhyay, Tharian Cherian, Dalise Y. Shatz, Andrew D. Beaser, Zaid Aziz, Cevher Ozcan, Michael T. Broman, Hemal Nayak, and Roderick Tung

Originally published 1 Feb 2019 | https://doi.org/10.1161/CIRCULATIONAHA.118.038648 | Circulation. 2019;0

72 LBBB-11 normal-5 RBBB

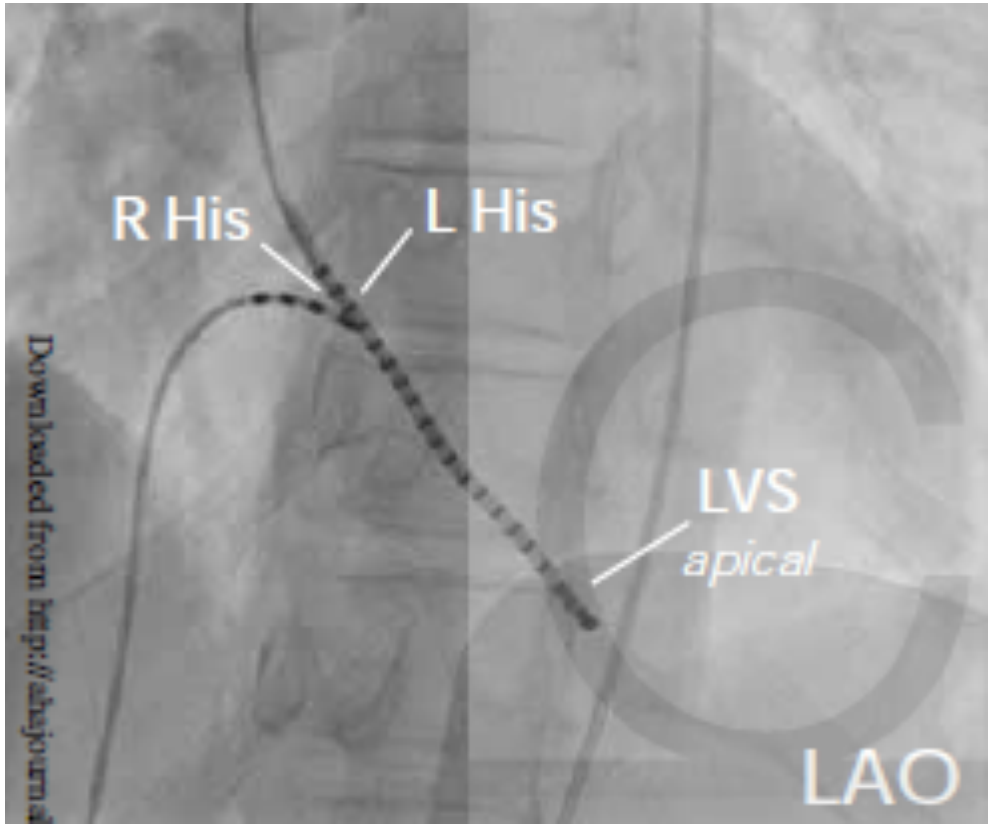

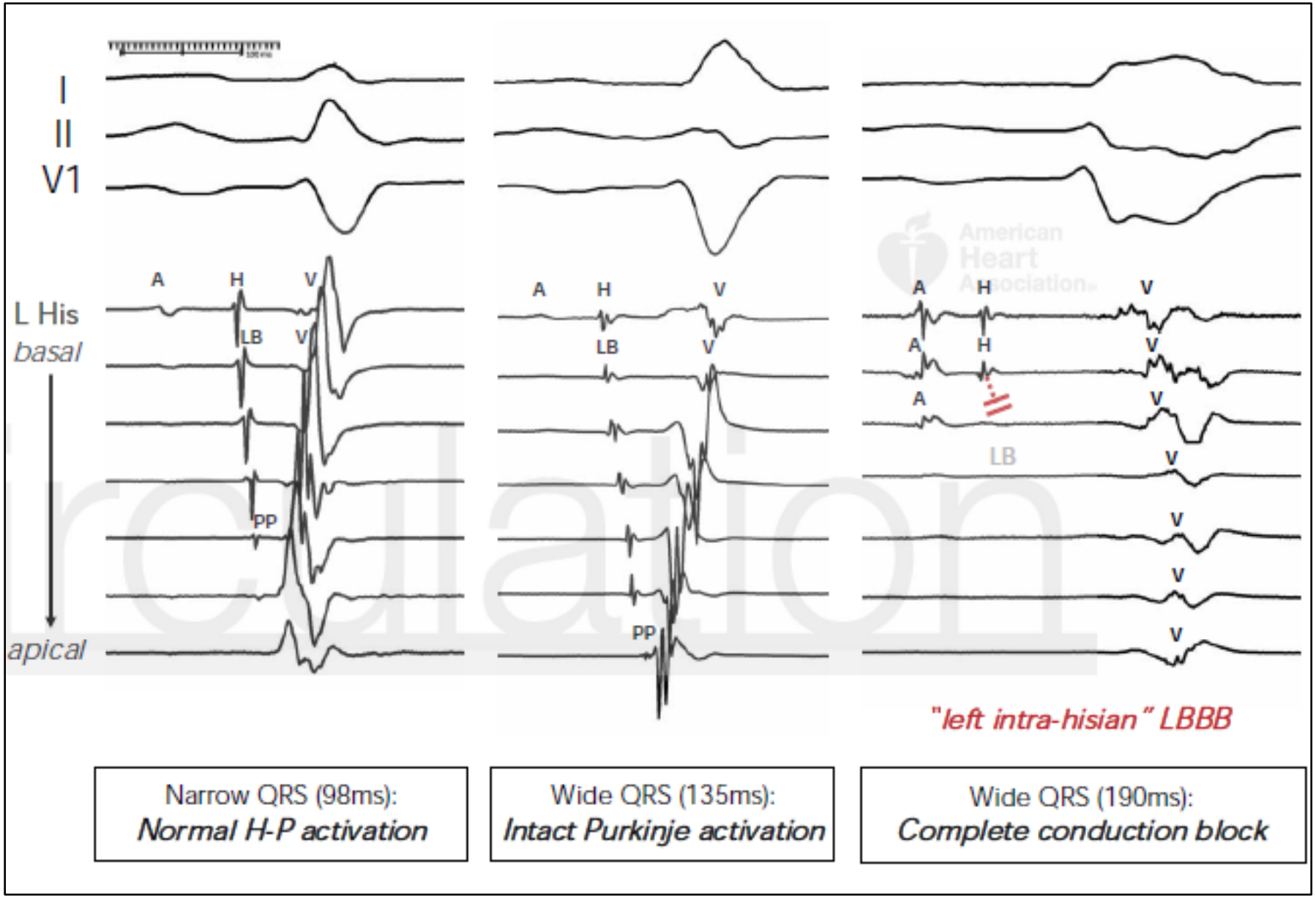

Upadhyay GA. Circulation. 2019 Feb 1. doi:10.1161/CIRCULATIONAHA.118.038648.

İntakt purkinje aktivasyonu

Tam ileti bloğu

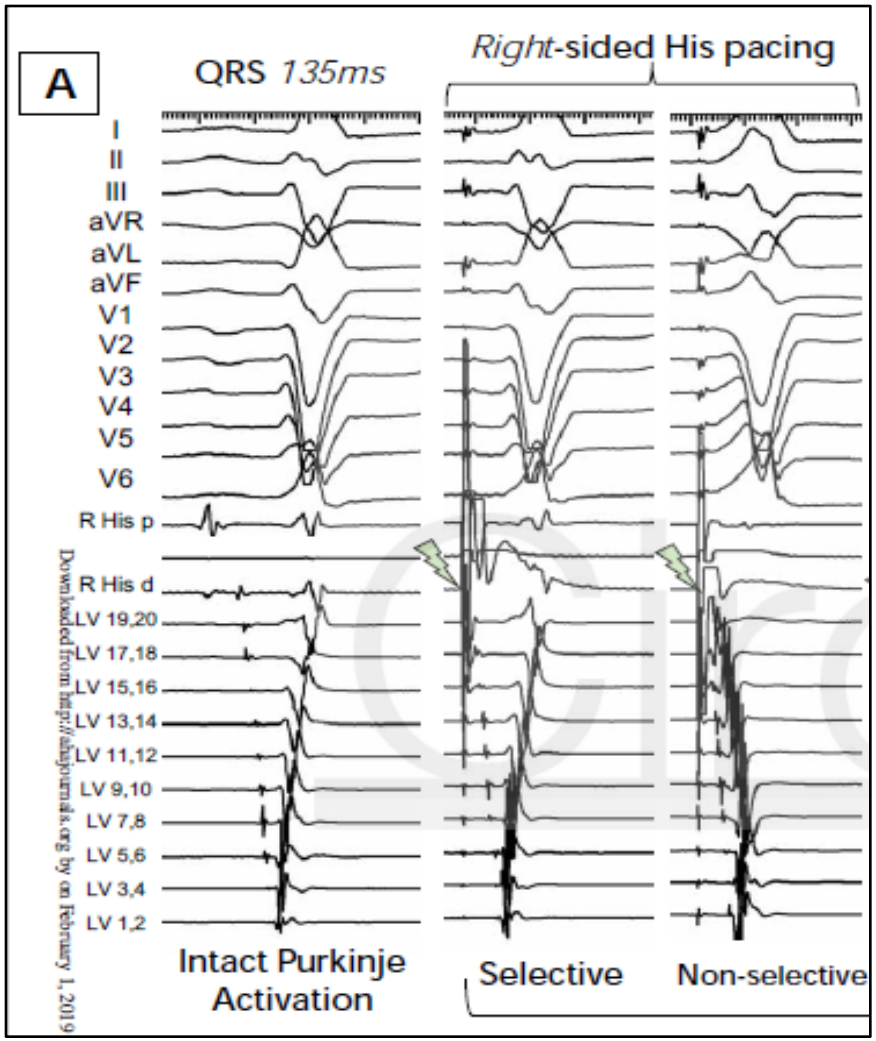

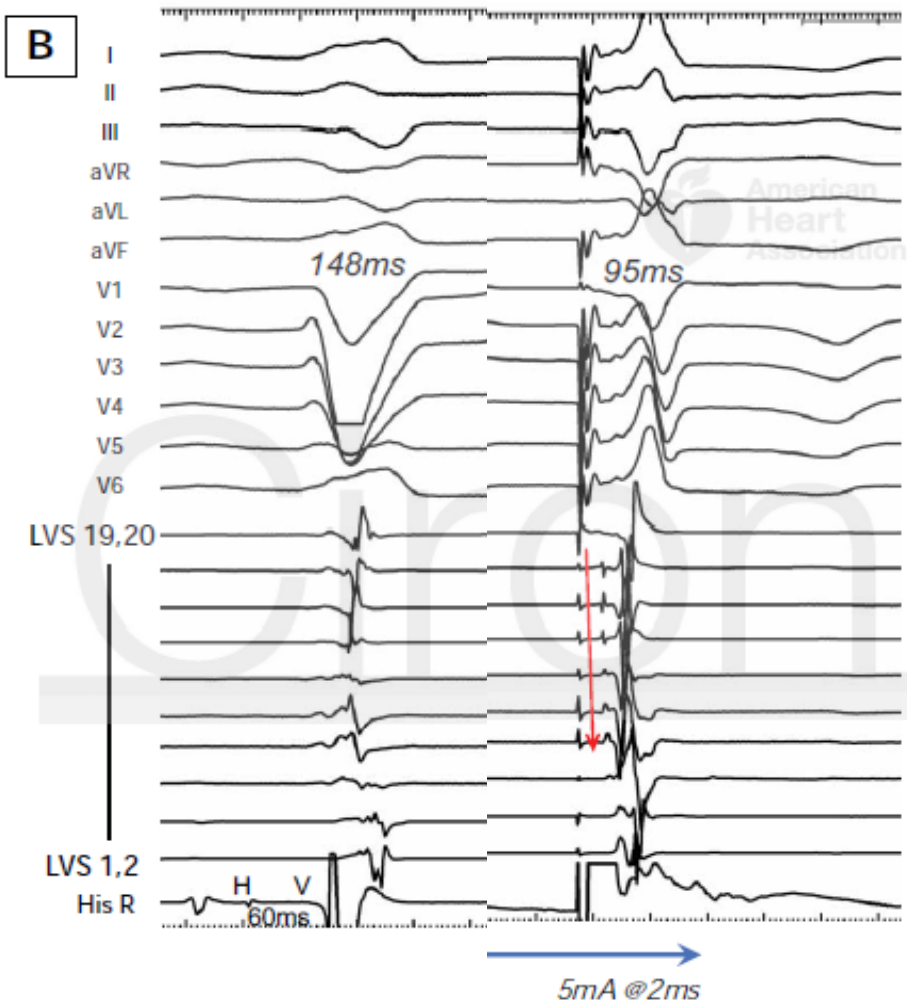

Ø

✓

Upadhyay GA. Circulation. 2019 Feb 1. doi:10.1161/CIRCULATIONAHA.118.038648.

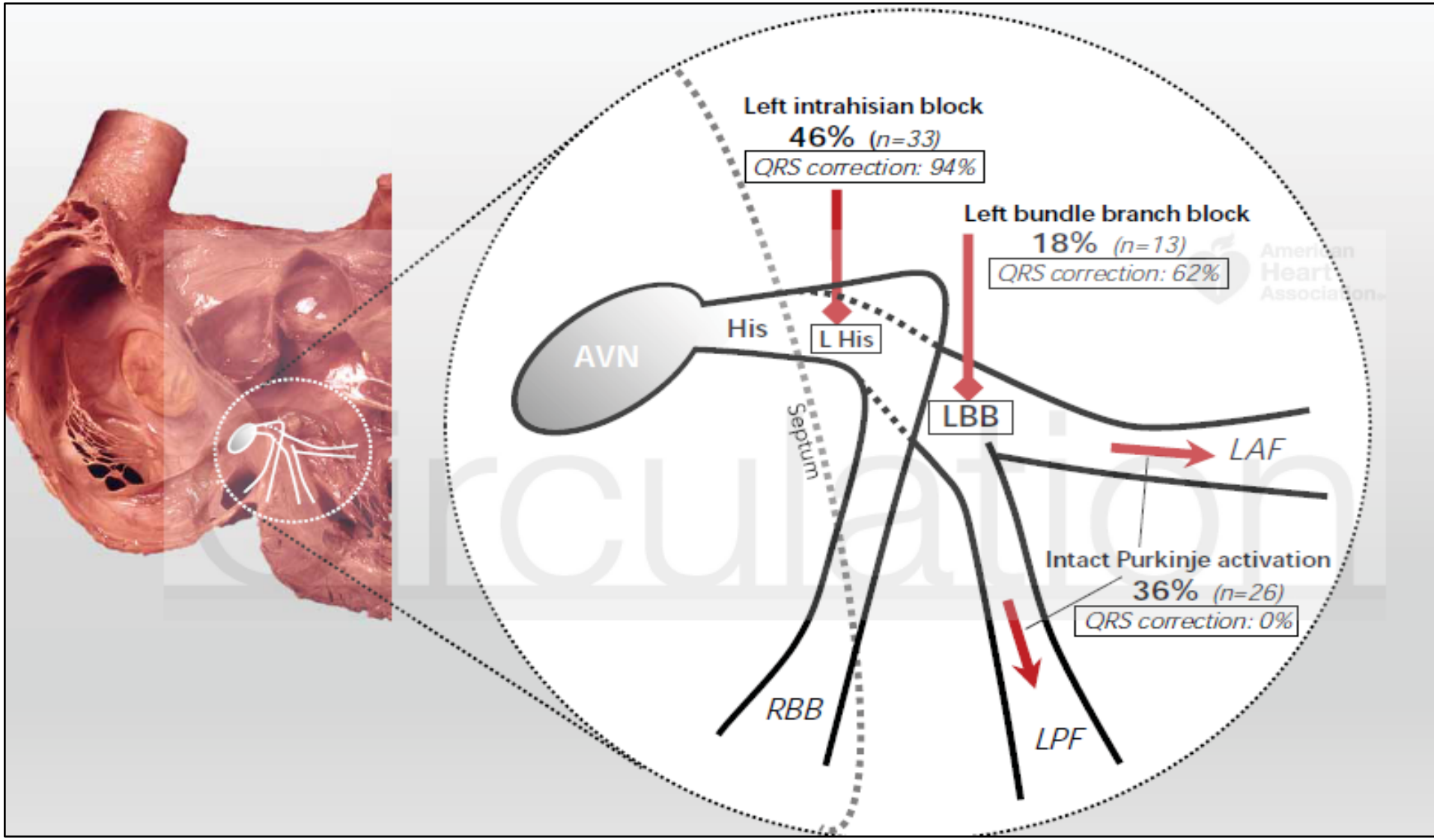

Upadhyay GA, et al. Circulation. 2019 Feb 1. doi:10.1161/CIRCULATIONAHA.118.038648.

His Bundle Pacing in Advanced AV block

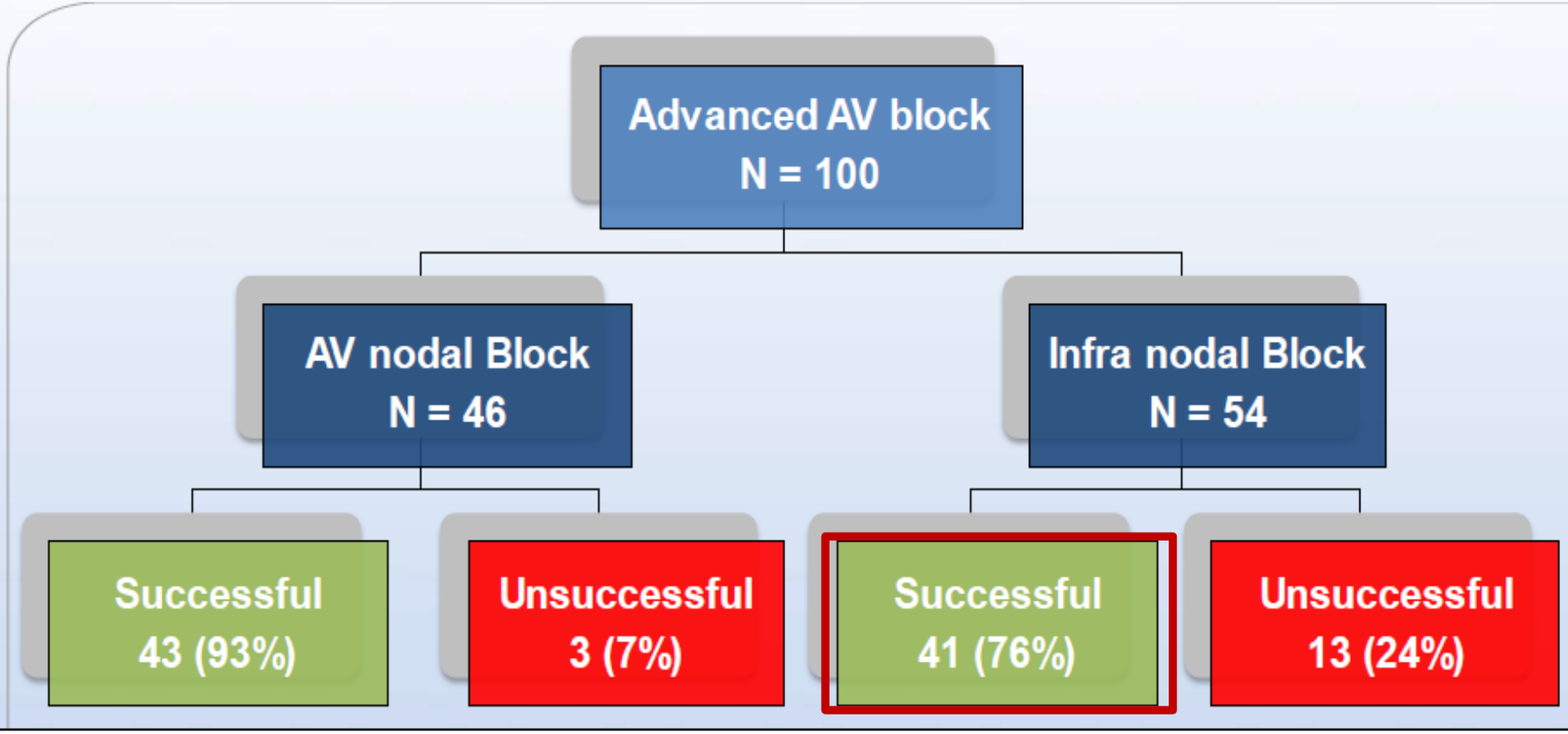

Vijayaraman P, Naperkowski A, Ellenbogen KA et al. Permanent HBP in AV block…JACCEP 2015;1:571-81

Usefulness of His Bundle Pacing to Achieve Electrical Resynchronization in Patients with Complete Left Bundle Branch Block and the Relation Between Native QRS Axis, Duration, and Normalization

Alexandra E. Teng, MD[a], Daniel L. Lustgarten, MD, PhD[b], Pugazhendhi Vijayaraman, MD[c], Roderick Tung, MD[d], Kalyanam Shivkumar, MD, PhD[a], Galen S. Wagner, MD[e], and Olujimi A. Ajijola, MD, PhD[a]

Am J Cardiol. 2016 August 15; 118(4): 527–534.

29 komplet LBBB➔ HBP

21 hasta➔ QRS normal, % 71

3 hasta➔ kısmi yanıt

QRS< 150ms➔ başarı yüksek

His-bundle pacing versus biventricular pacing in cardiac resynchronization therapy patients: A crossover design comparison

Heart Rhythm2015;12:1548–1557

Daniel L. Lustgarten, MD, PhD, FHRS,[*†] Eric M. Crespo, MD, MPH, FHRS,[‡]
Irina Arkhipova-Jenkins, MD,[§] Robert Lobel, MD,[*] Joseph Winget, MD,[*]
Jodi Koehler, MS,[§] Evan Liberman, BS,[§] Todd Sheldon, MS[§]

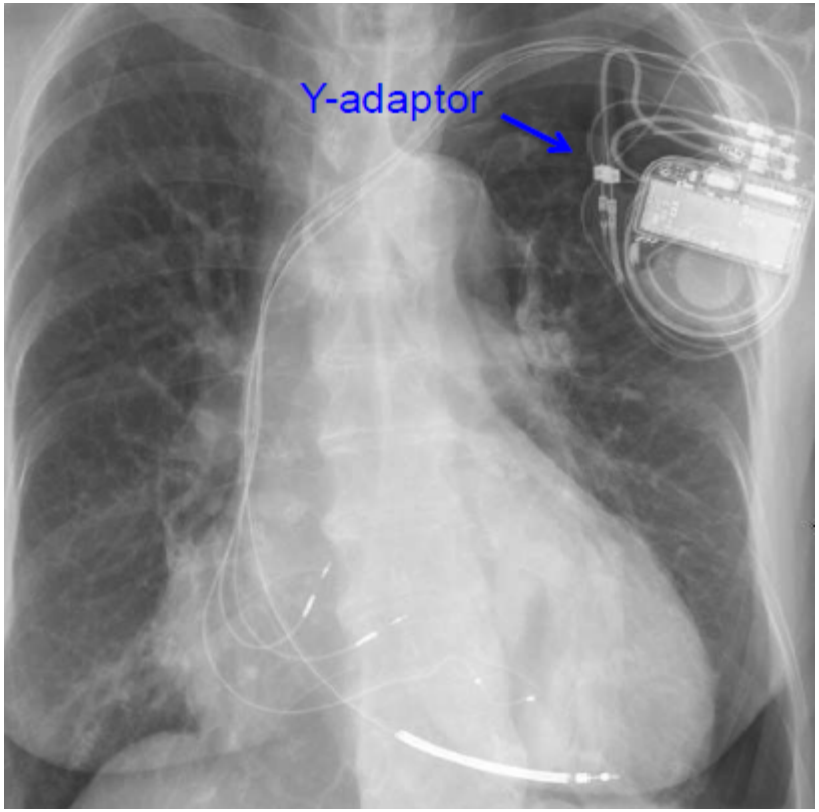

29 hasta-28 komplet LBBB➔ HBP-CRT

NİKMP/İKMP

21 hasta➔ QRS normal (İKMP yanıt yüksek)

Permanent His-bundle pacing for cardiac resynchronization therapy: Initial feasibility study in lieu of left ventricular lead

Heart Rhythm 2017 Sep;14(9):1353-1361

Olujimi A. Ajijola, MD, PhD, Gaurav A. Upadhyay, MD, FHRS, Carlos Macias, MD, Kalyanam Shivkumar, MD, PhD, FHRS, Roderick Tung, MD, FHRS

Permanent His-bundle pacing as an alternative to biventricular pacing for cardiac resynchronization therapy: A multicenter experience

Heart Rhythm 2018 Mar;15(3):413-420

Parikshit S. Sharma, MD, MPH, FACC, Gopi Dandamudi, MD, FHRS, Bengt Herweg, MD, David Wilson, MD, Rajeev Singh, MD, Angela Naperkowski, RN, FHRS, CCDS, CEPS, Jayanthi N. Koneru, MBBS, Kenneth A. Ellenbogen, MD, FACC, FHRS, Pugazhendhi Vijayaraman, MD, FACC, FHRS

106 olgu, % 90 başarılı, 7 hastada eşik yükselmesi,

3 hastada lead revizyonu (LV lead)

Permanent His bundle pacing: Recommendations from a Multicenter His Bundle Pacing Collaborative Working Group for standardization of definitions, implant measurements, and follow-up

Heart Rhythm 2018 Mar;15(3):460-46

Pugazhendhi Vijayaraman, MD, FHRS, Gopi Dandamudi, MD, FHRS, Francesco Zanon, MD, FHRS, Parikshit S. Sharma, MD, MPH, Roderick Tung, MD, FHRS, Weijian Huang, MD, FHRS, Jayanthi Koneru, MBBS, Hiroshi Tada, MD, PhD, FHRS, Kenneth A. Ellenbogen, MD, FHRS, Daniel L. Lustgarten, MD, PhD, FHRS

Threshold< 2.5V@1ms
> 3.5 V!!, > 1 V artışlar önemli
His injurycurrent +
SHBP-NSHBP ?
Sensing daha düşük
EP operatör➔ 10 olgu

TABLE 3 Current Candidates for Consideration of Permanent HBP

AV nodal block: second- and third-degree block
Infranodal, intra-Hisian AV block
Atrial fibrillation and slow ventricular response
Sinus node dysfunction and marked first-degree AV block (PR interval >240 ms)
AV nodal ablation (especially if EF <40%)
Any patient with anticipated need for high burden of RV pacing, especially if EF <40%-50%
ICD-eligible patients with previously-listed indications and high RV pacing burden (>40%)
CRT-eligible patients with LBBB who failed LV lead placement
CRT nonresponder: especially RBBB

TEŞEKKÜRLER

İnfra-nodal blok

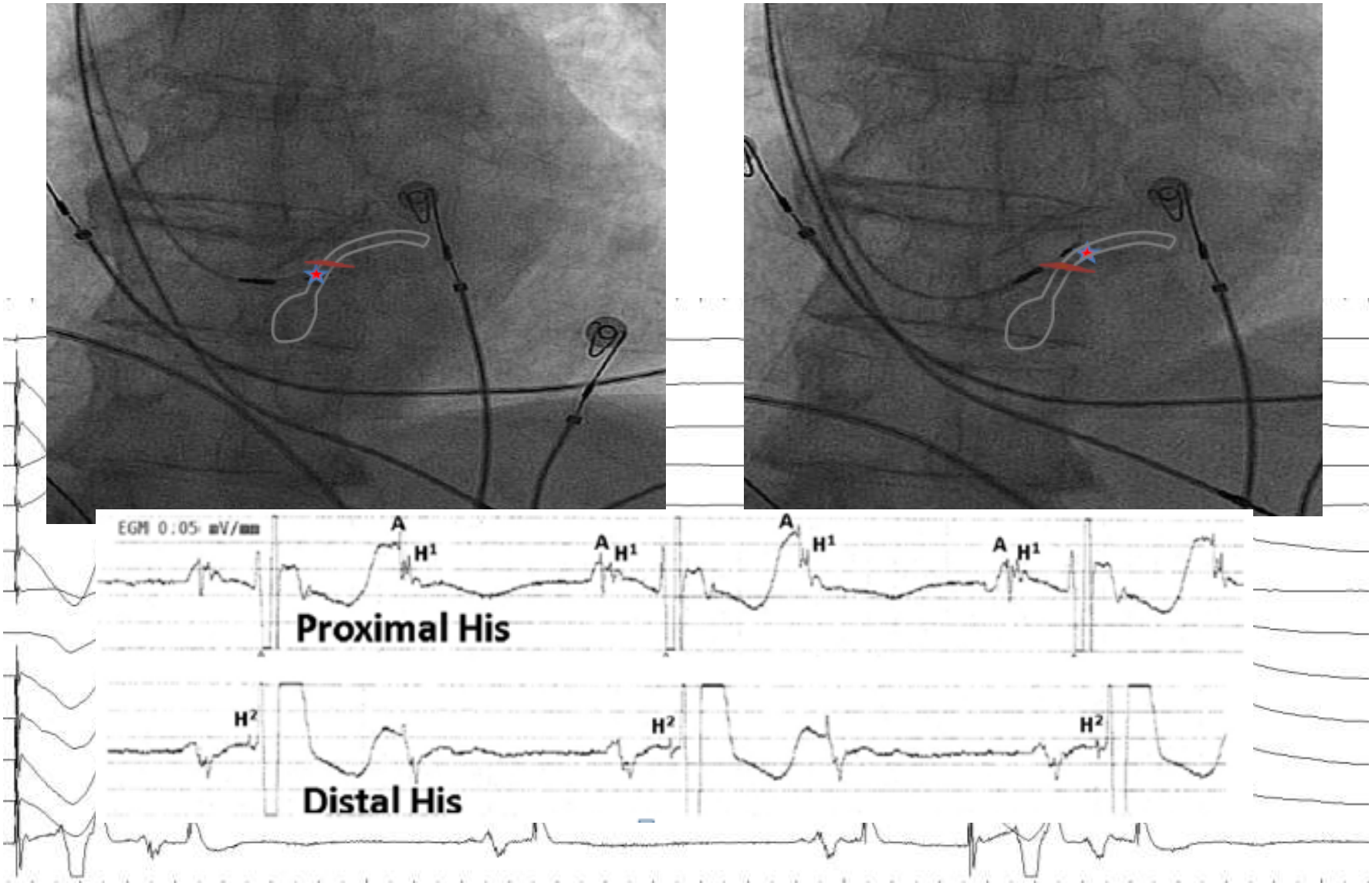

Pugazhendhi Vijayaraman

Dal bloklarında His pacing-mekanizma

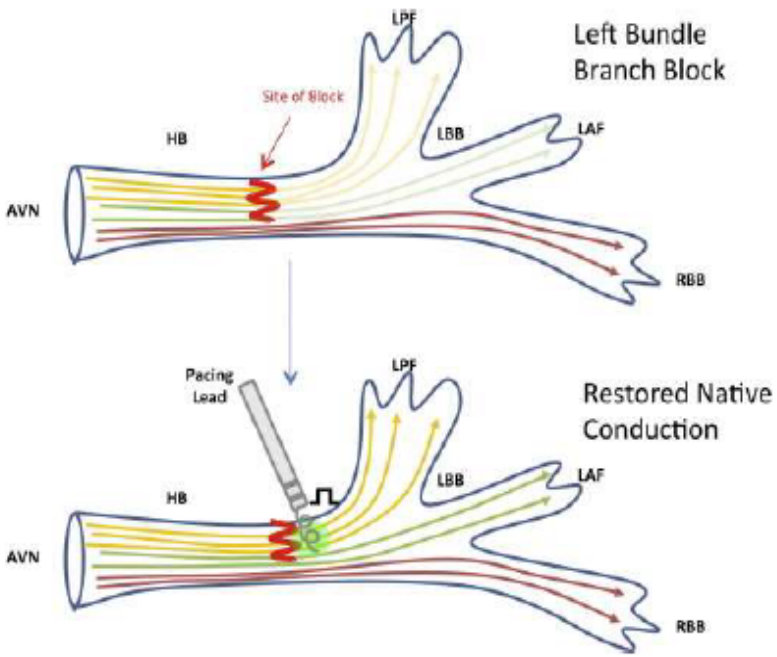

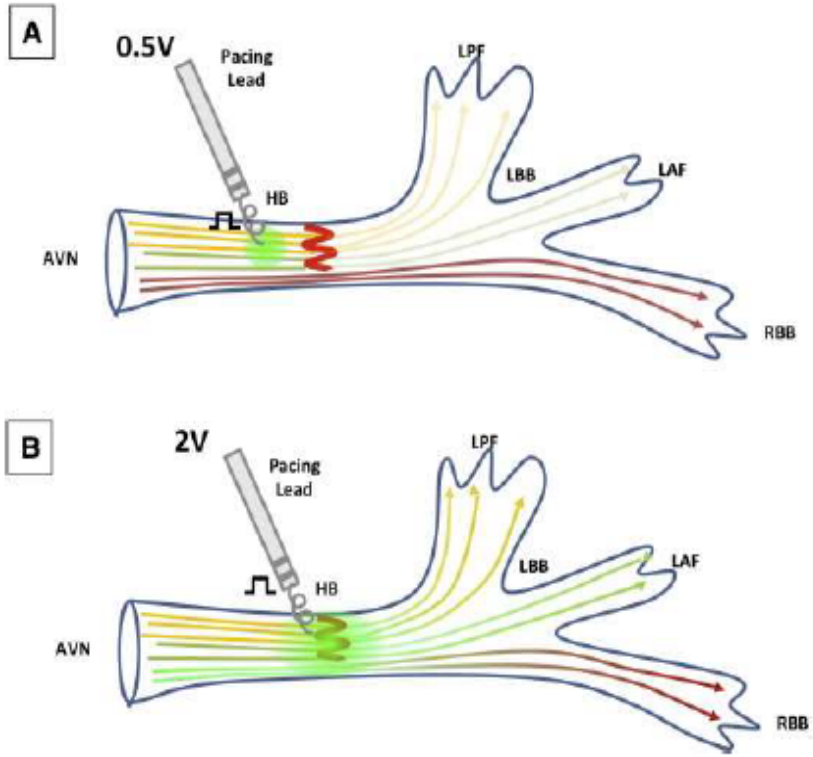

Teng A et al, Journal of Electrocardiography August 2016

Virtual electrode theory of pacing

- Propogation begins at some distance from stimulus electrode

J Electrocardiol. 2016 ; 49(5): 644–648

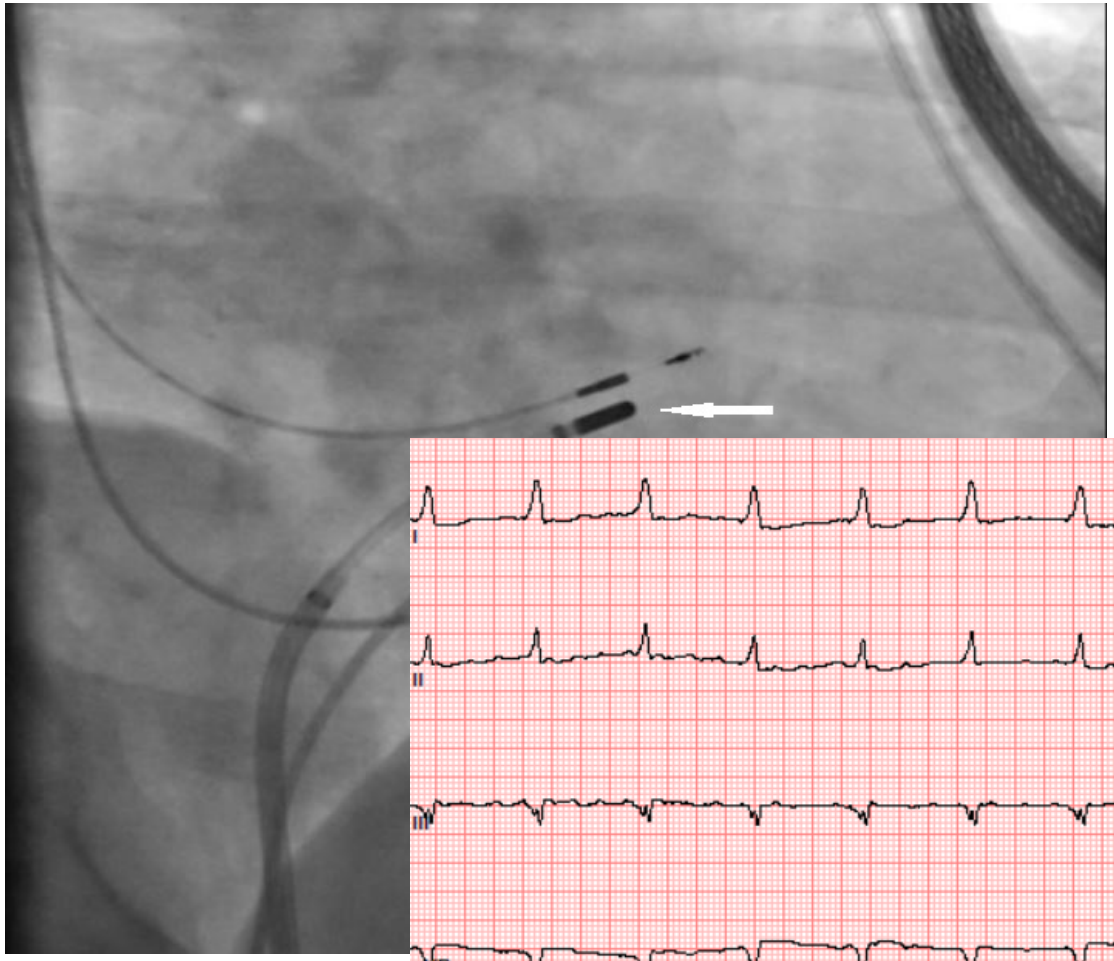

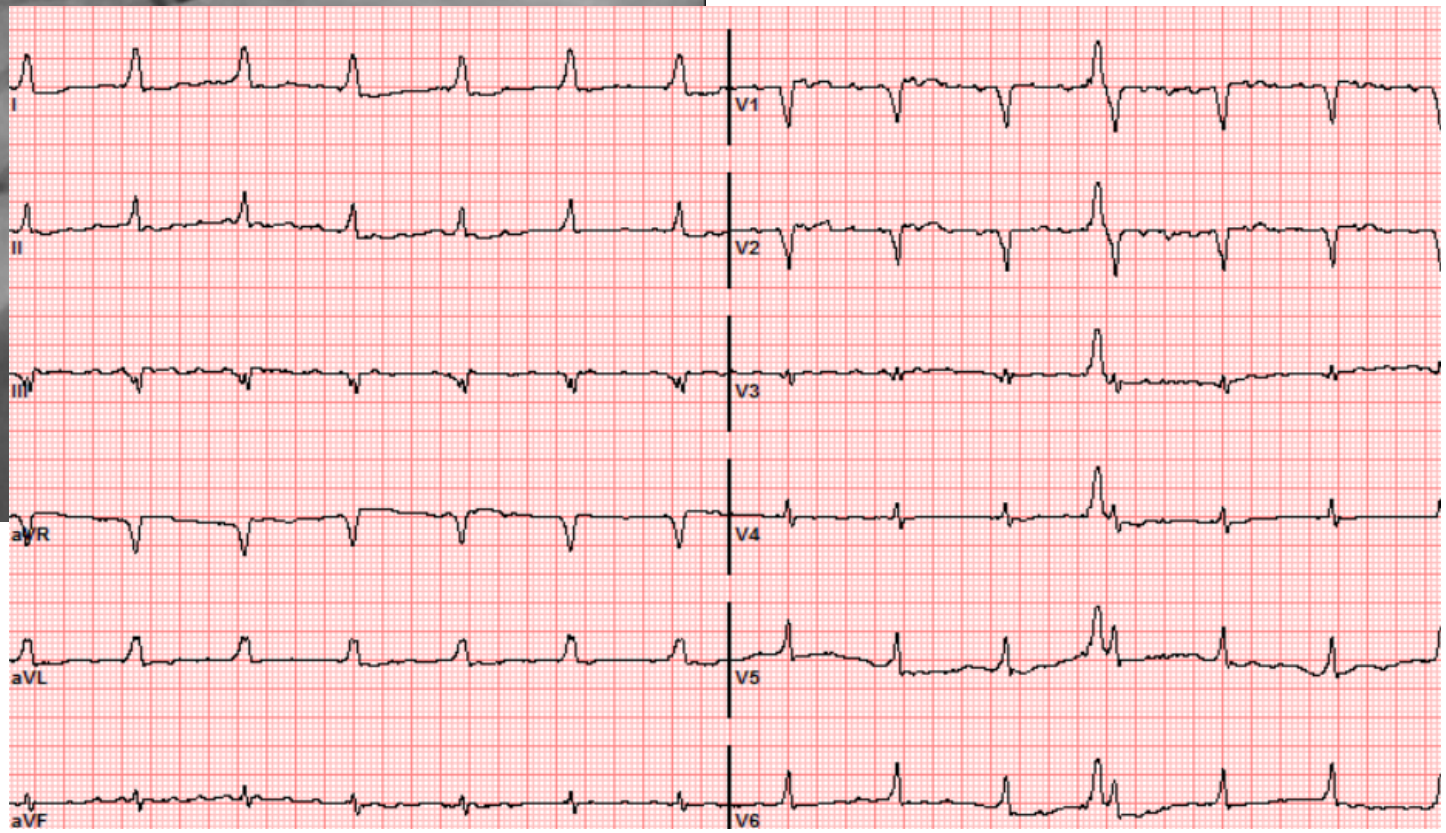
I
II
III
aVR
aVL
aVF
V1
V2
V3
V4
V5
V6

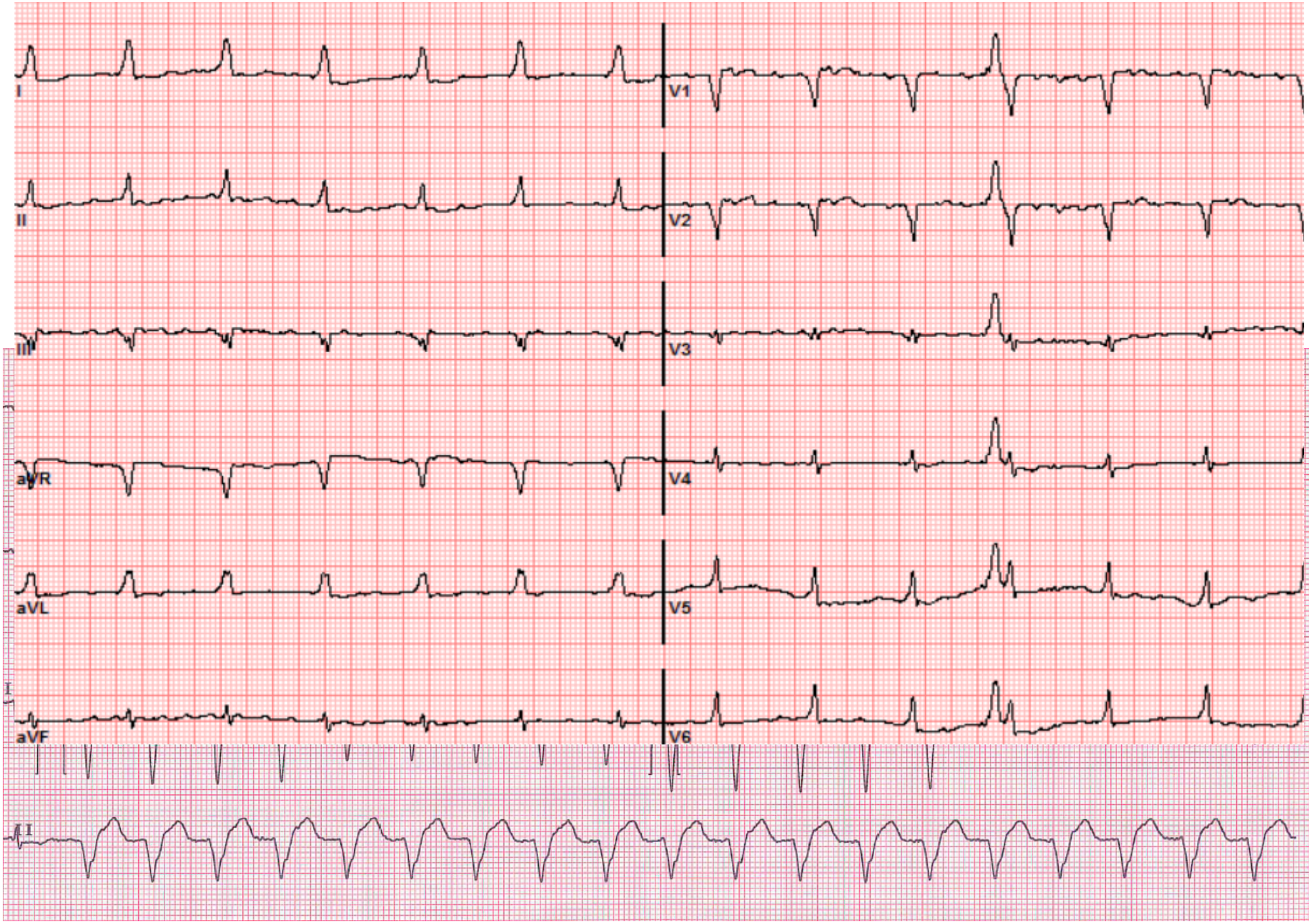
I
V1
II
V2
III
V3
aVR
V4
aVL
V5
aVF
V6
II

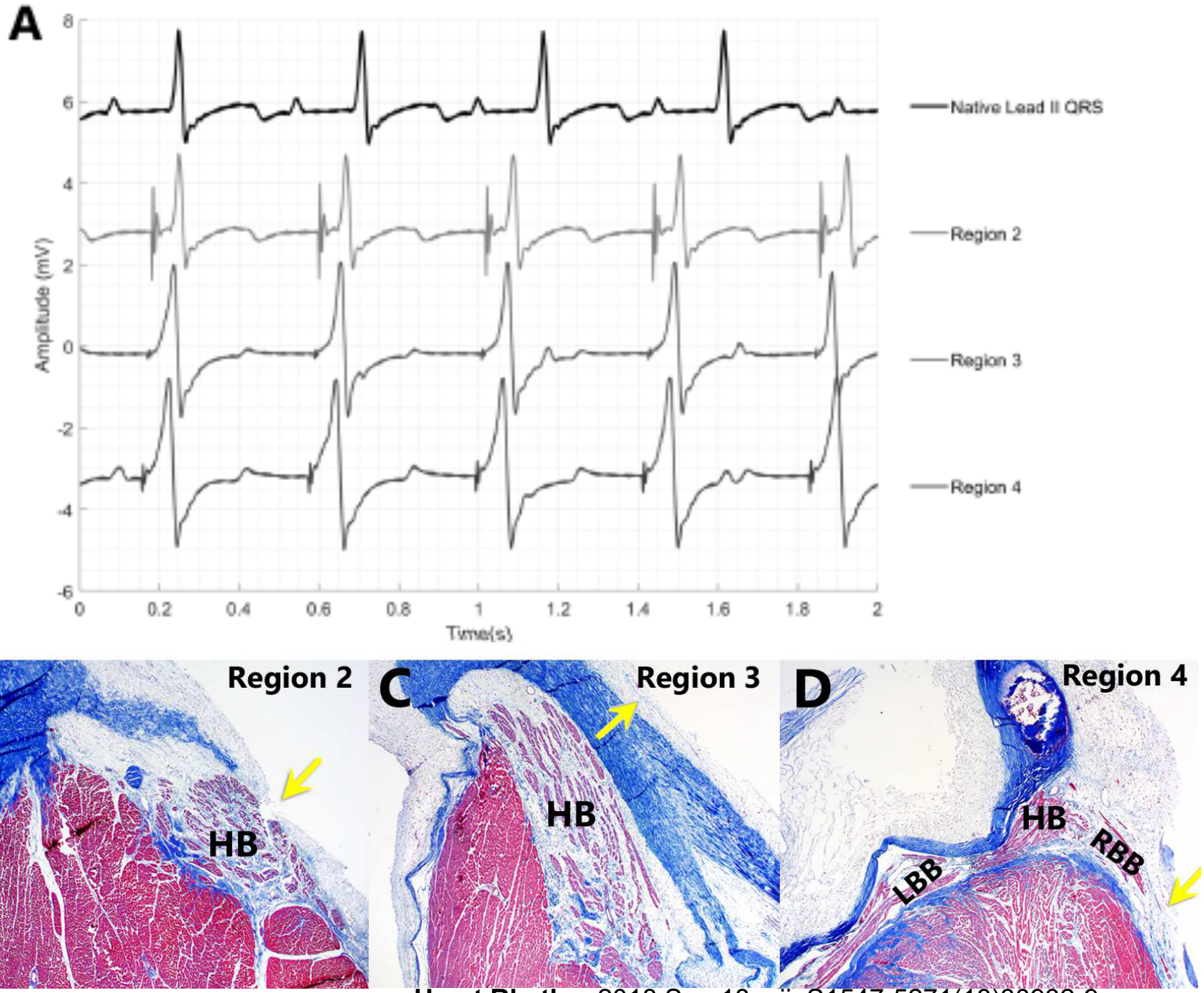

Heart Rhythm 2018 Sep 18. pii: S1547-5271(18)30932-9.

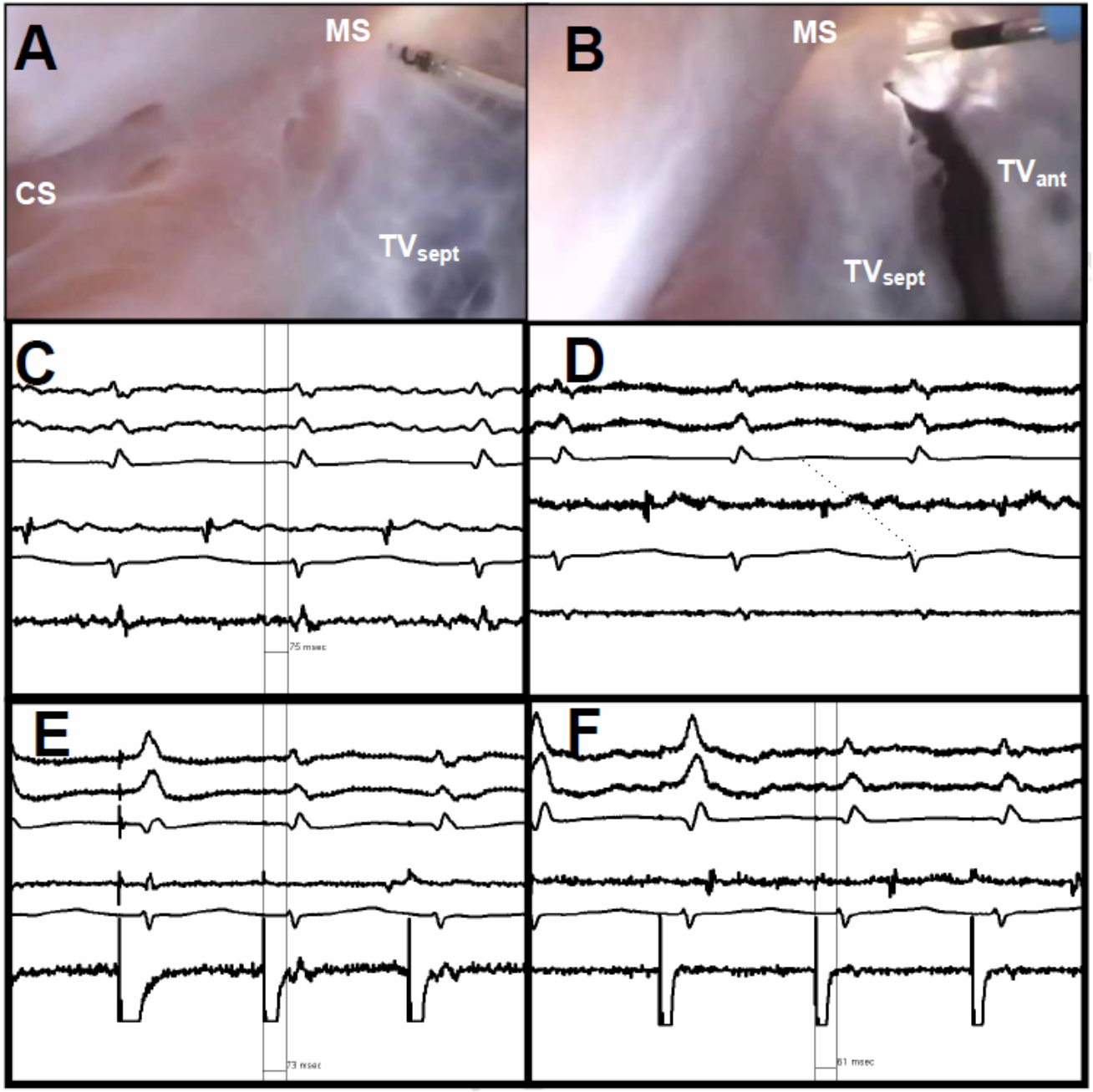

HeartRhythm Case Reports (2019),

DAVID

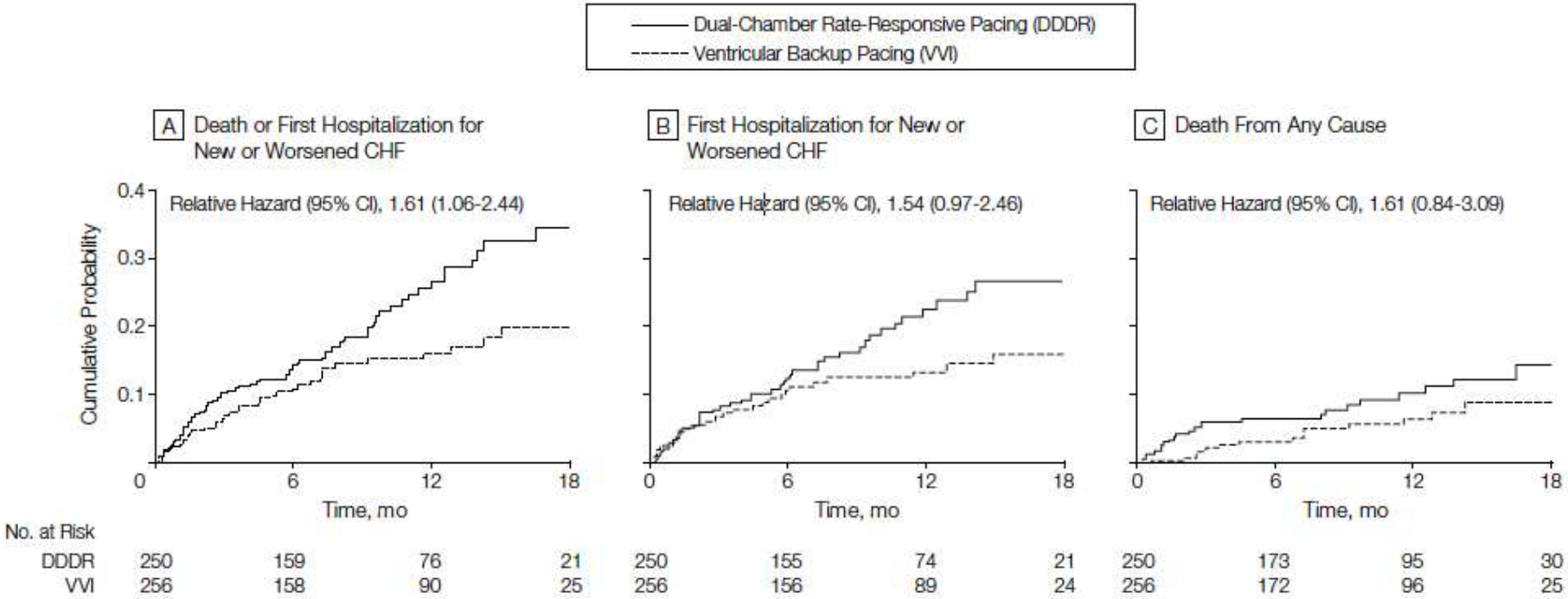

JAMA 2002;288

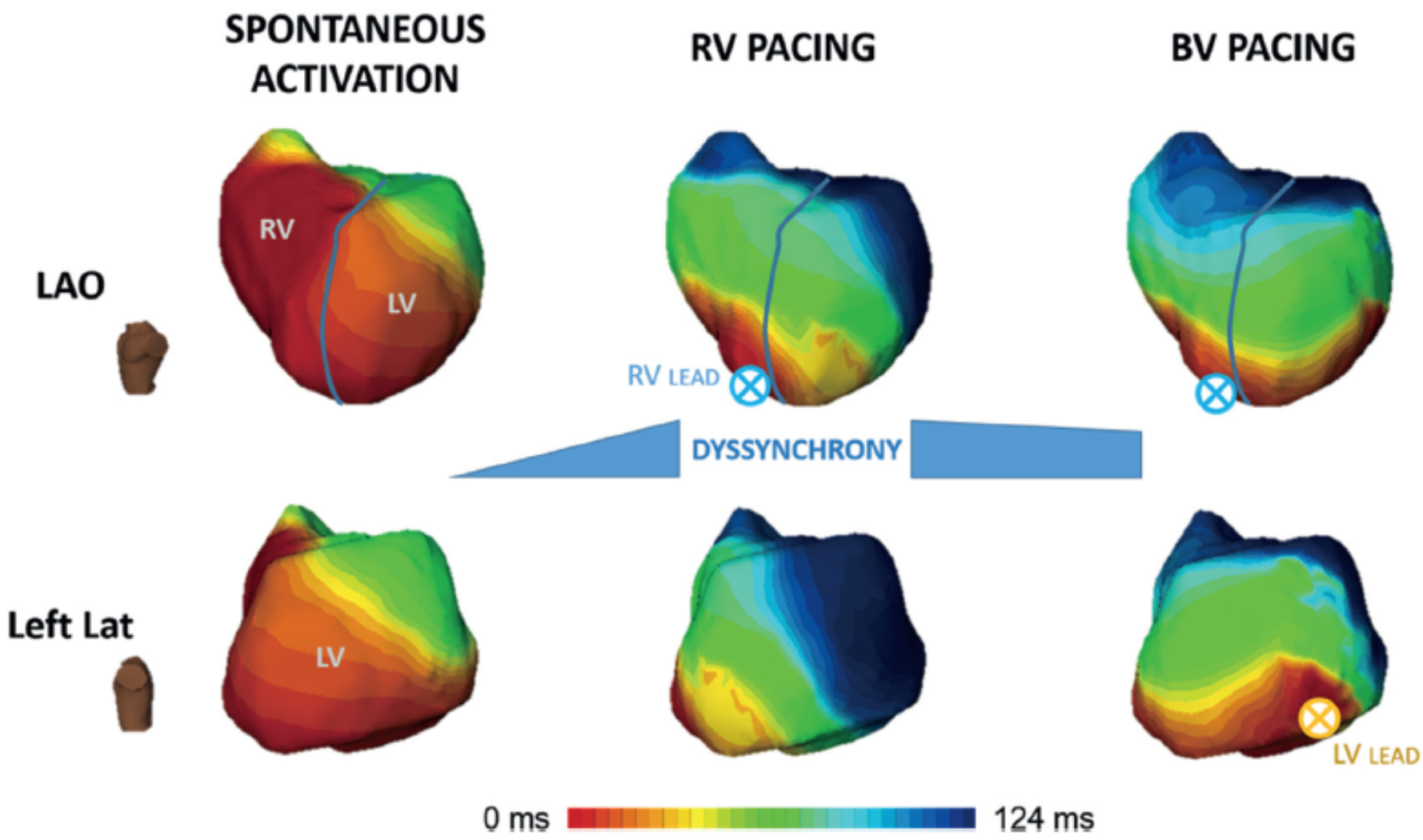

JACC VOL . 69, NO. 25 , 2017

Non-selektif HBP

Selektif HBP

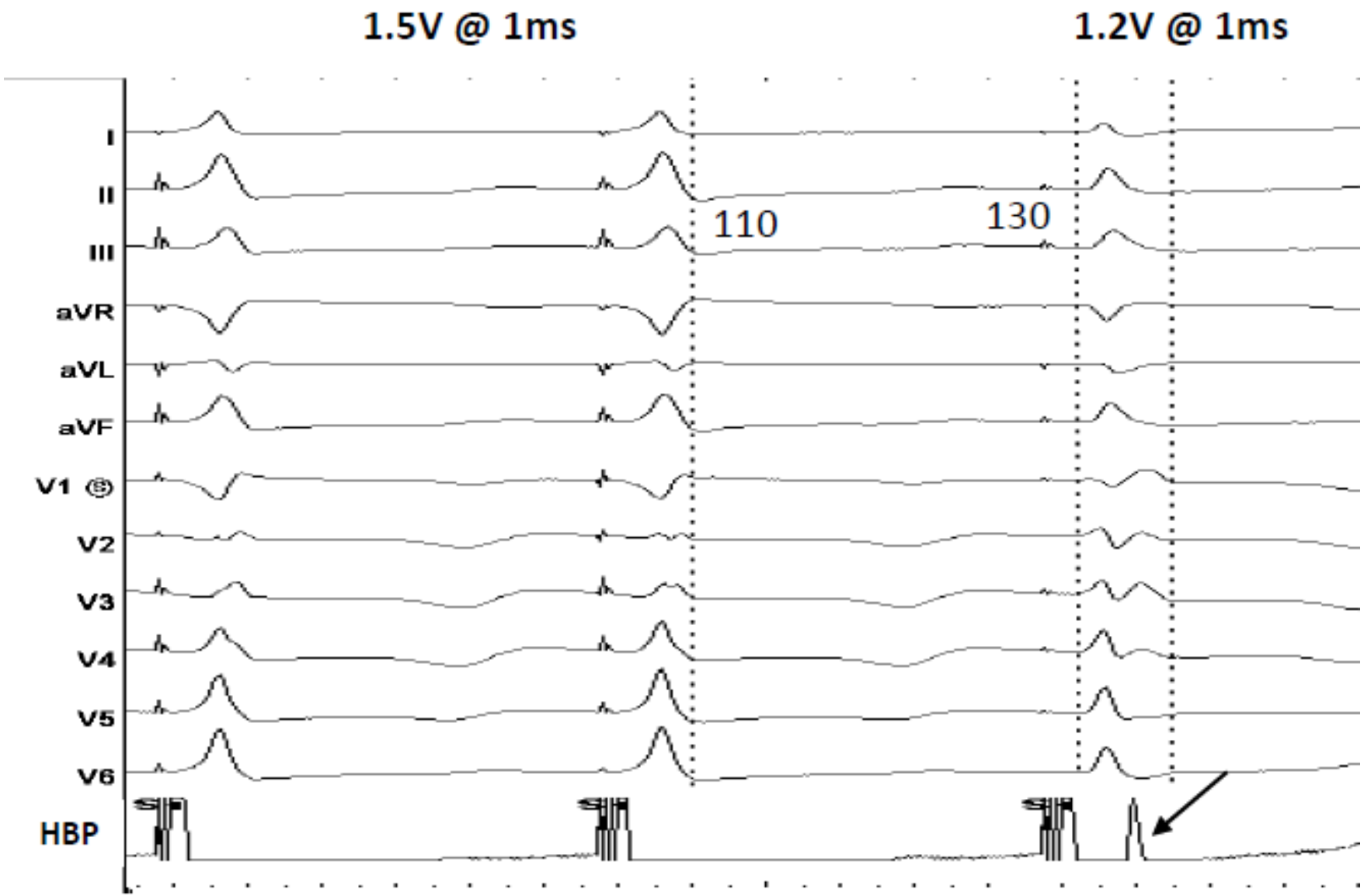

Adverse Effect of Ventricular Pacing on Heart Failure and Atrial Fibrillation Among Patients With Normal Baseline QRS Duration in a Clinical Trial of Pacemaker Therapy for Sinus Node Dysfunction

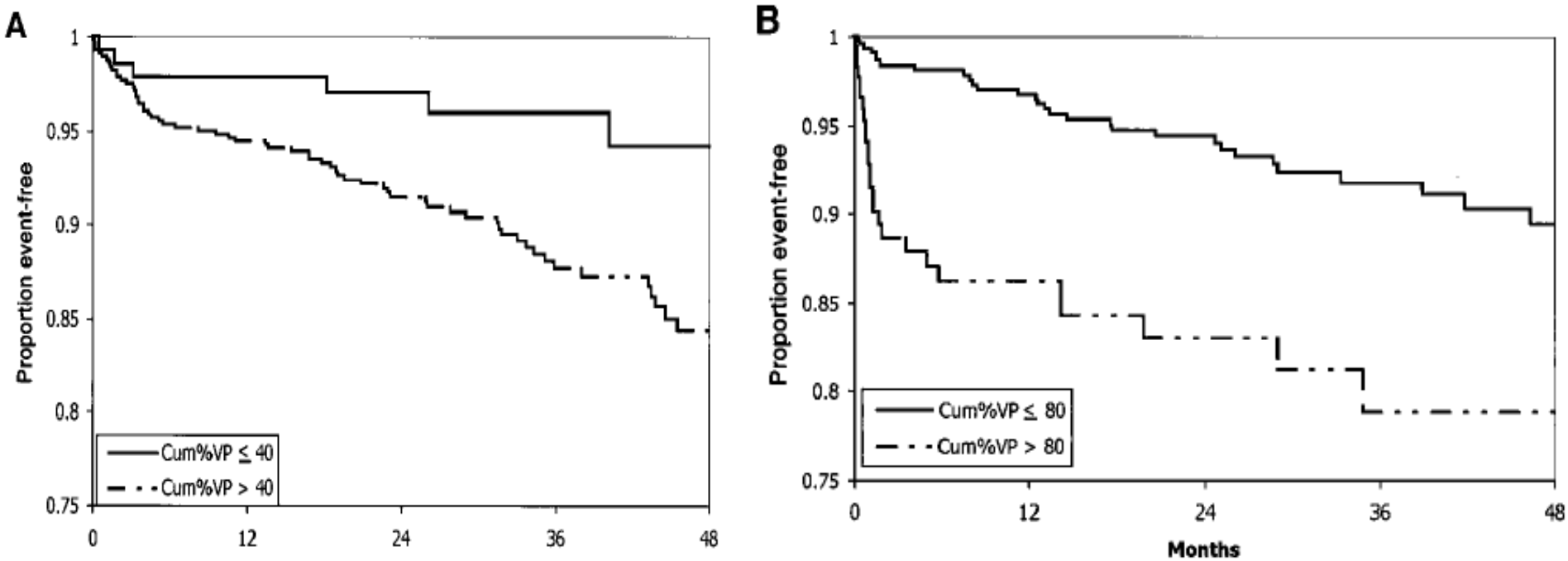

Conclusions—Ventricular desynchronization imposed by ventricular pacing even when AV synchrony is preserved increases the risk of HF hospitalization and AF in SND with normal baseline QRSd. (***Circulation*. 2003;107:2932-2937.**)

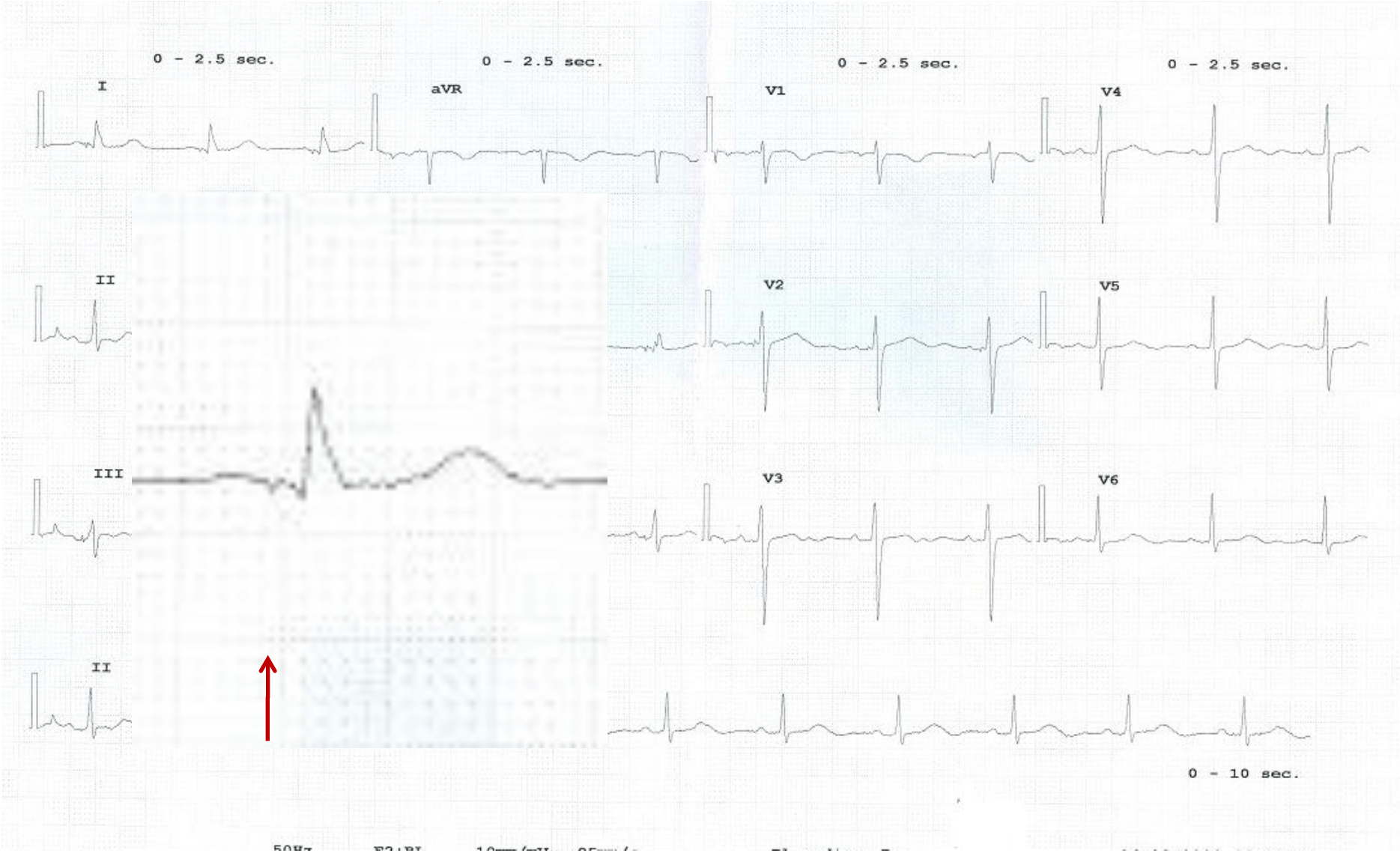

Francesco Zanon

YÖNTEM

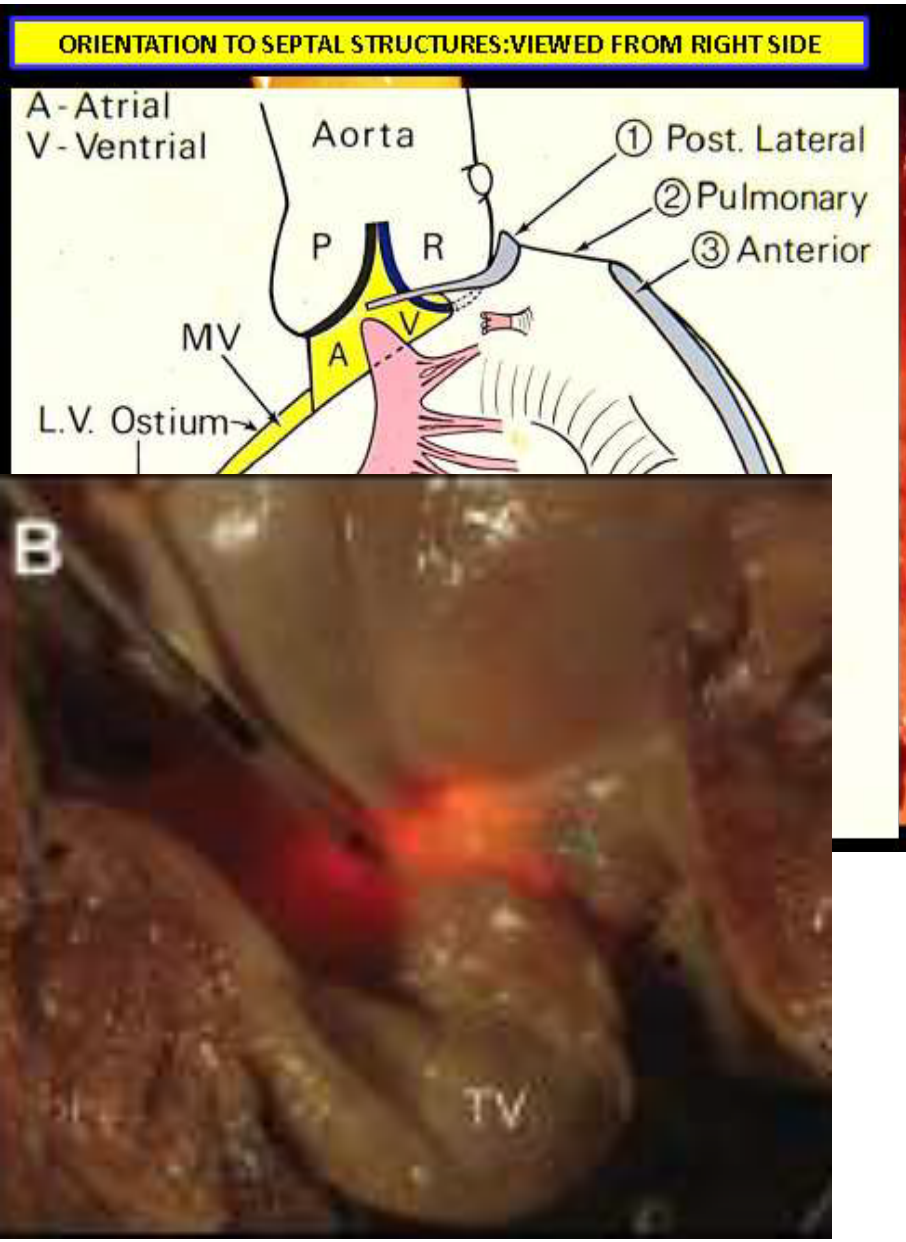

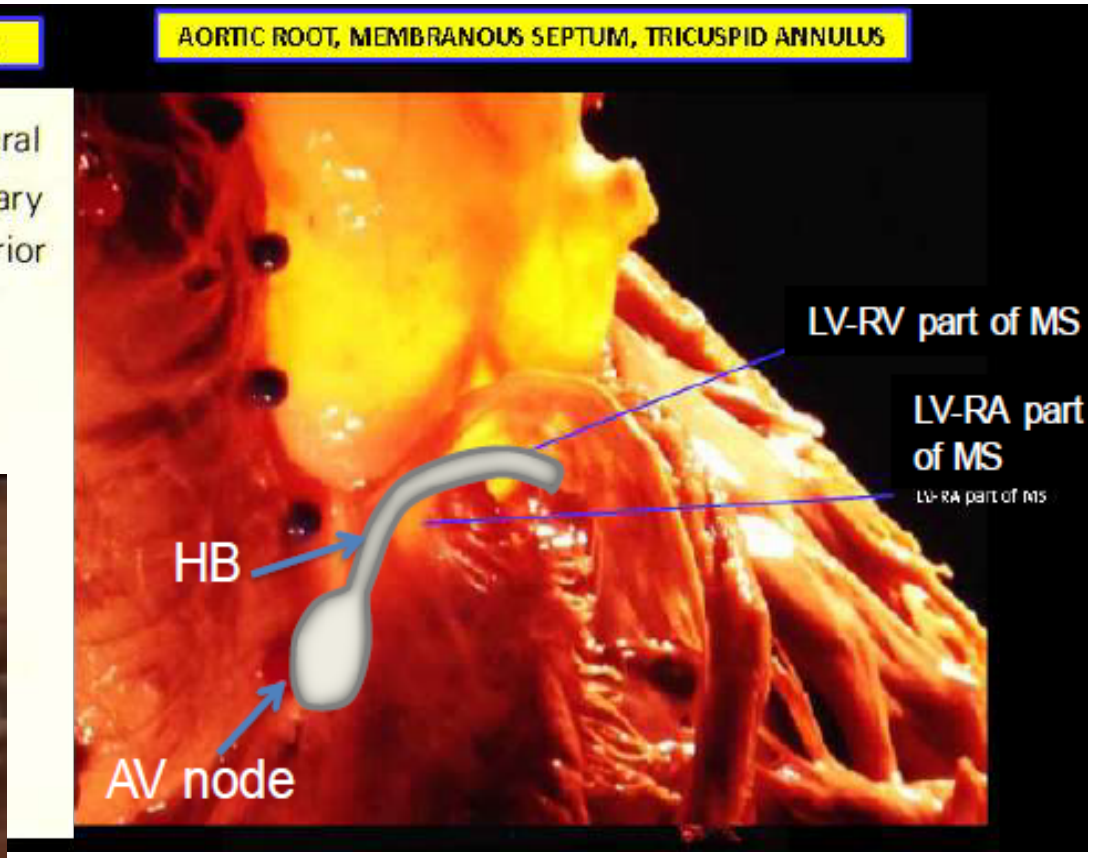

Courtesy: K.Shivkumar, UCLA

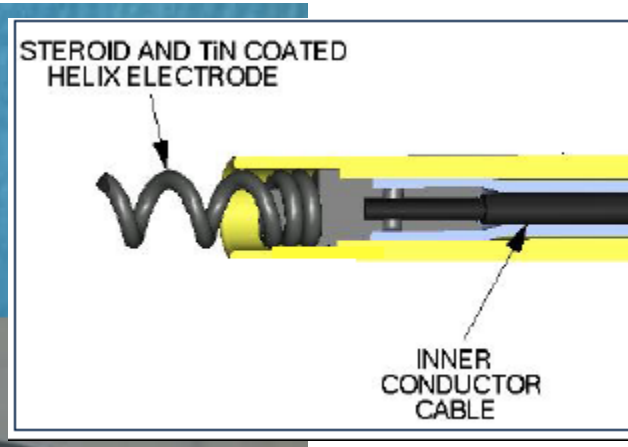

Medtronic SelectSite C304 - 8 Fr

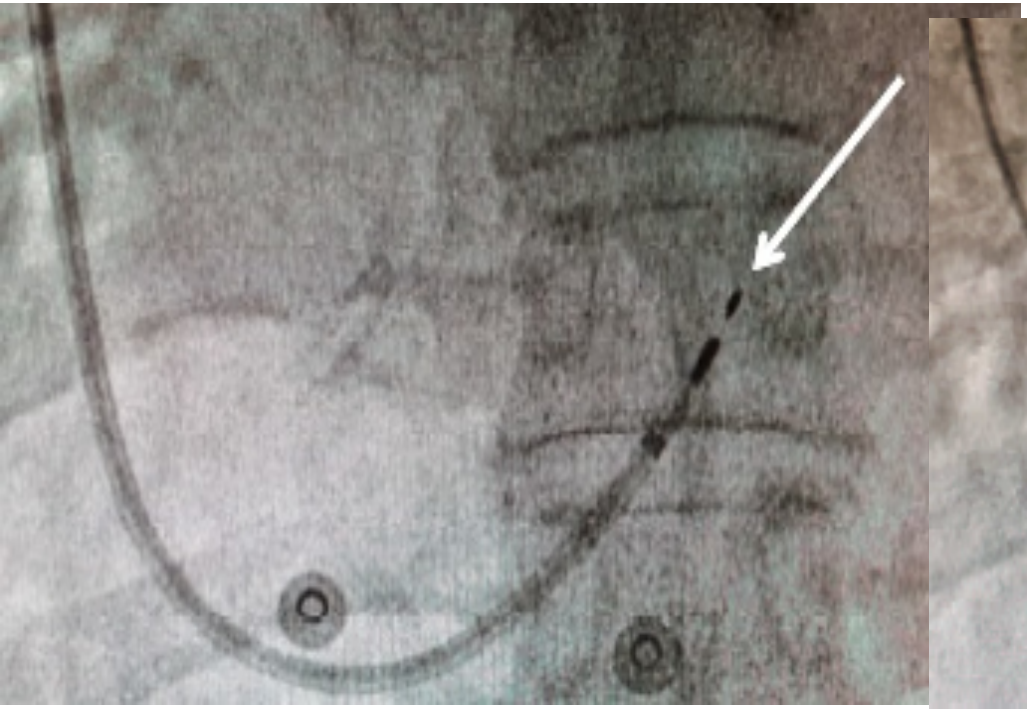

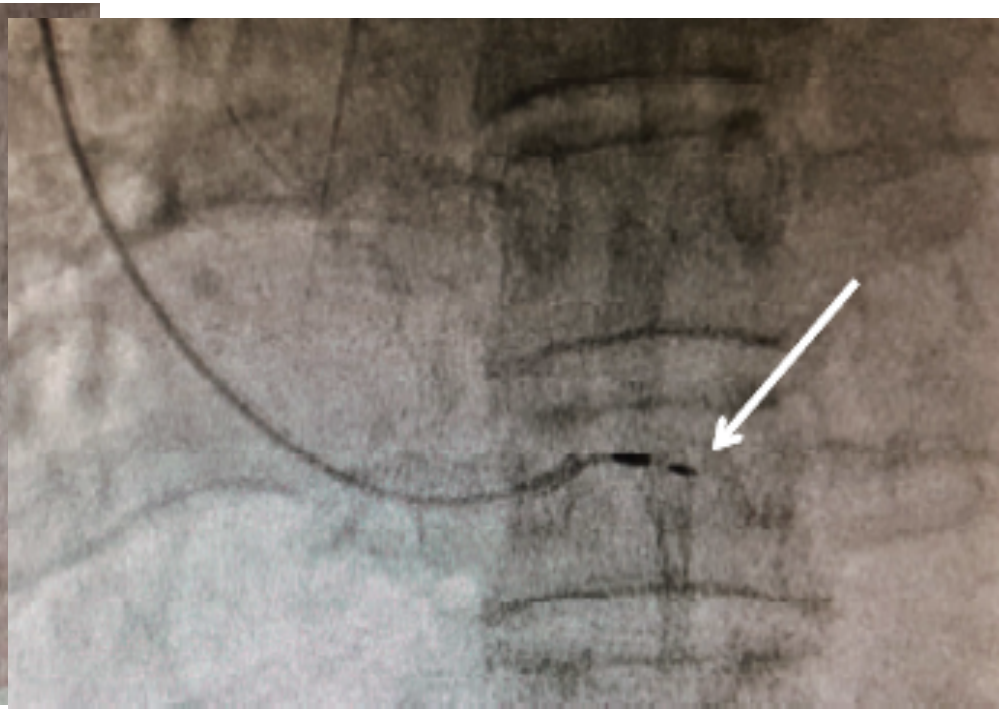

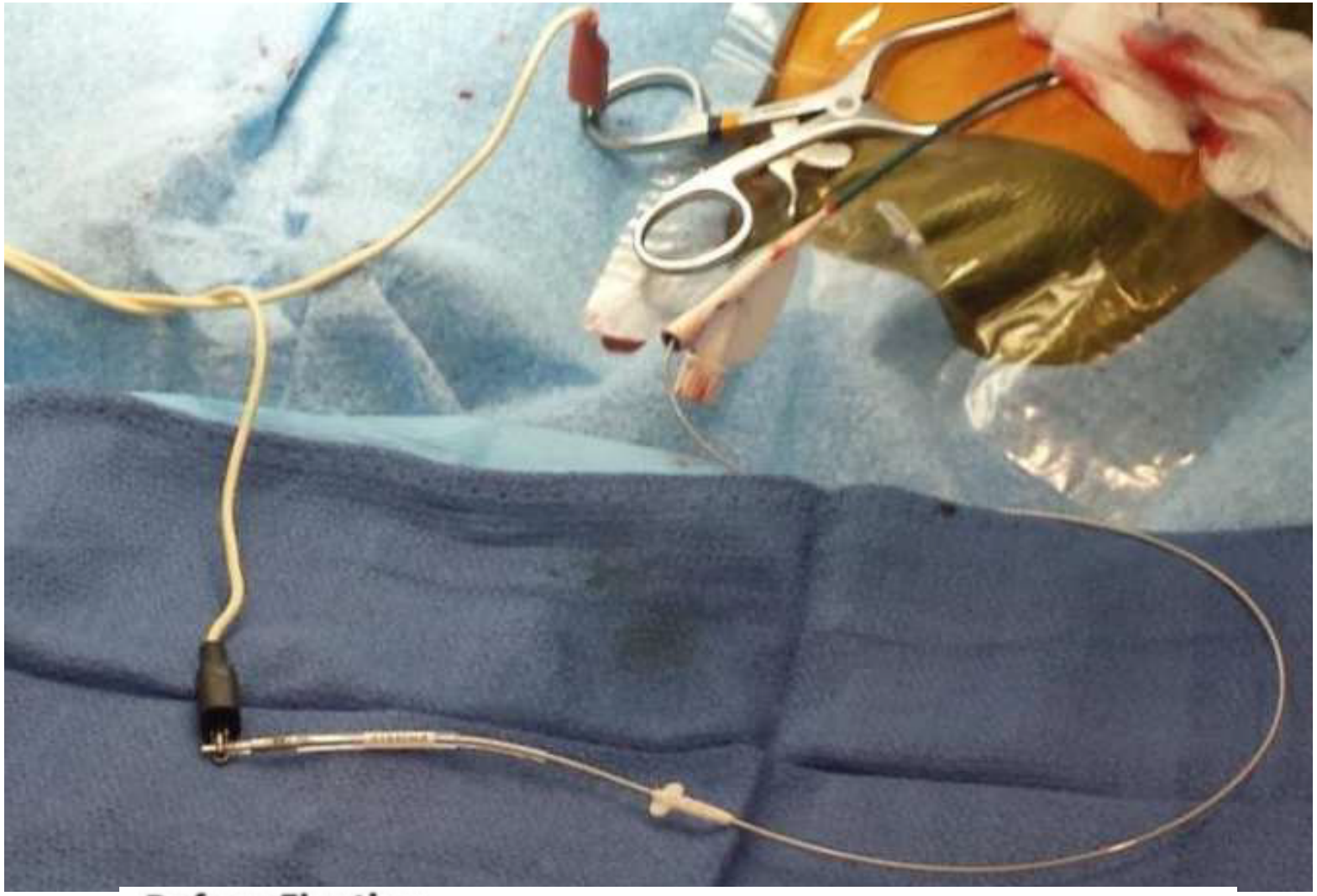

Before Fixation

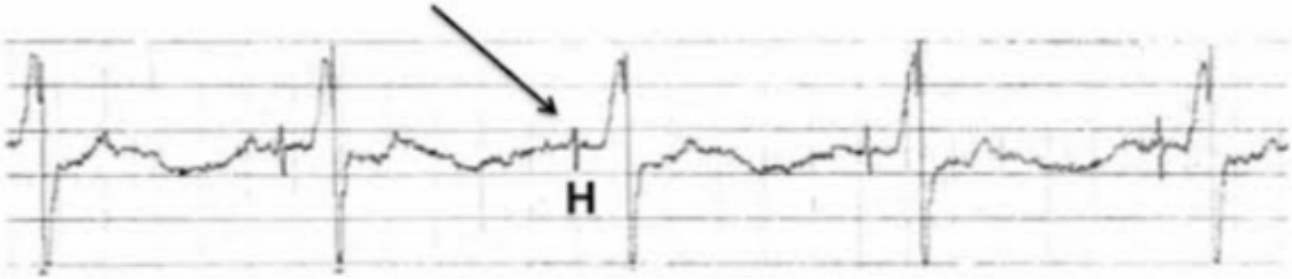

Before Fixation

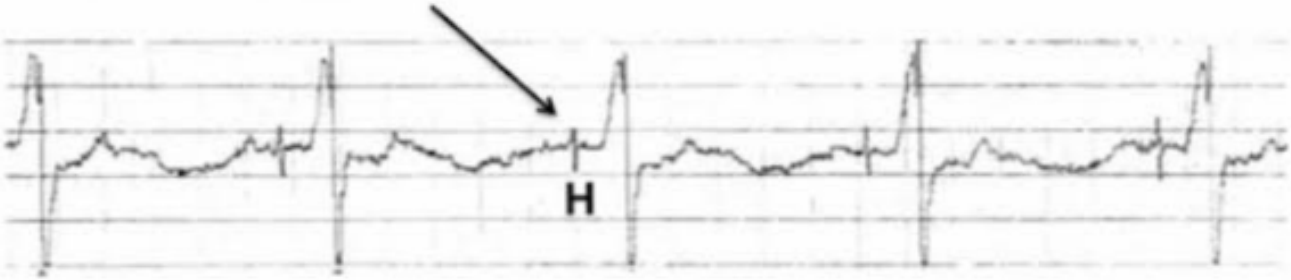

His bundle injury current

At implant



5 minutes

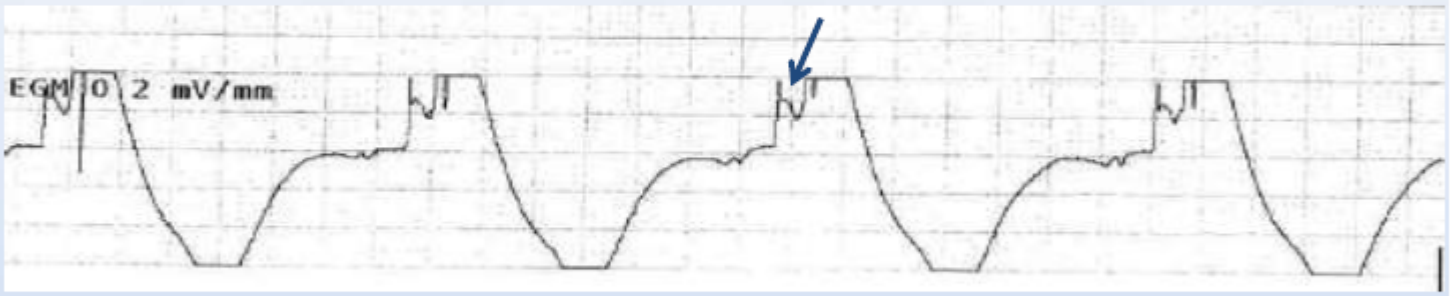

20 minutes

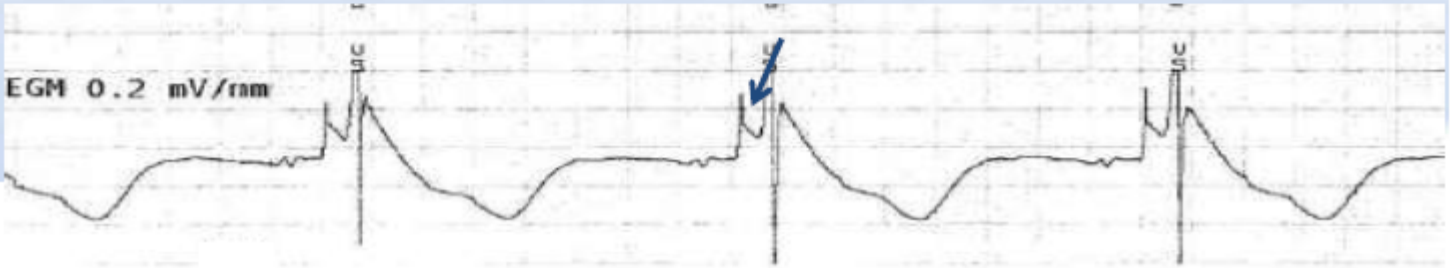

Non-selektif HBP

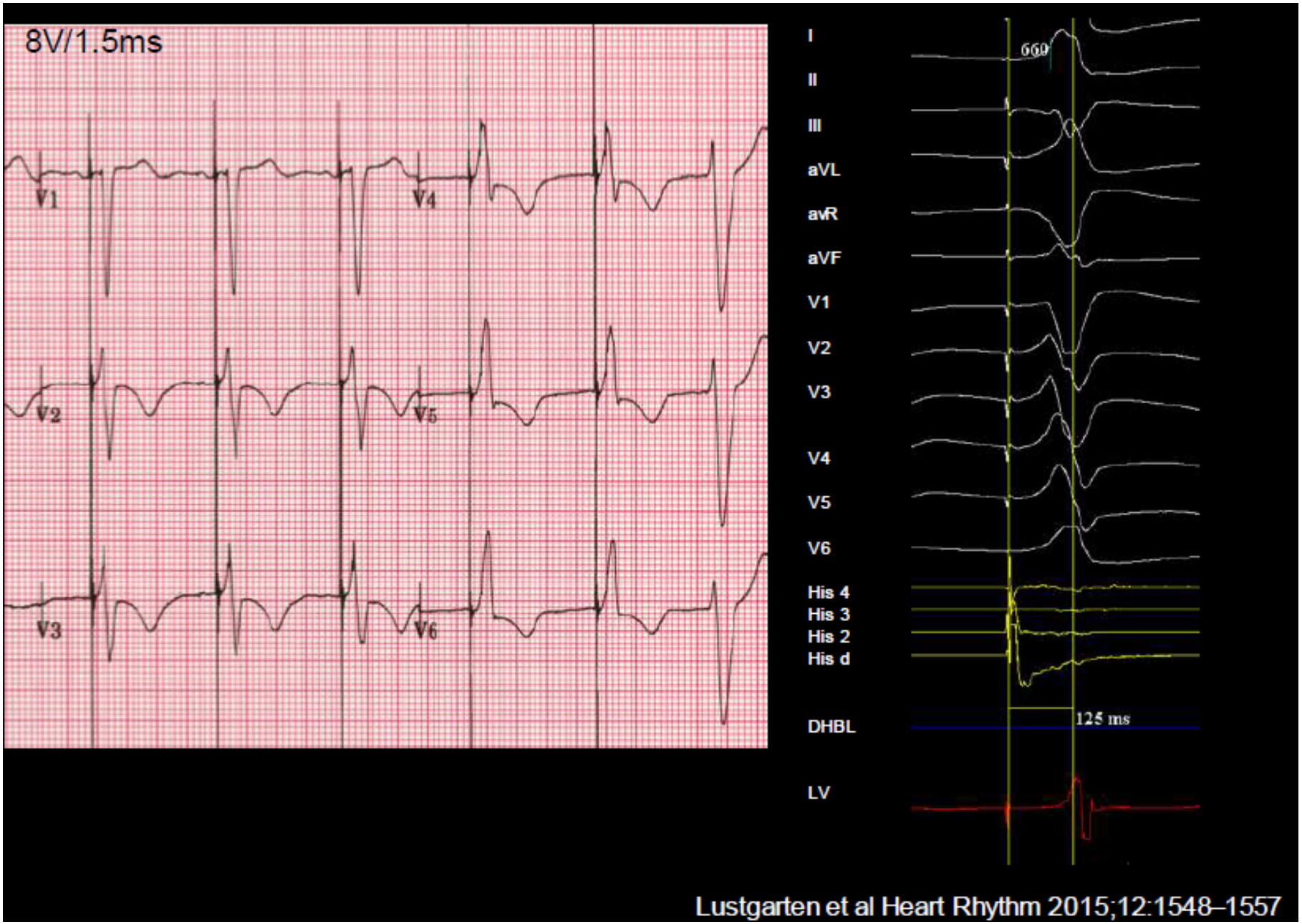

Lustgarten et al Heart Rhythm 2015;12:1548–1557

Selektif HBP

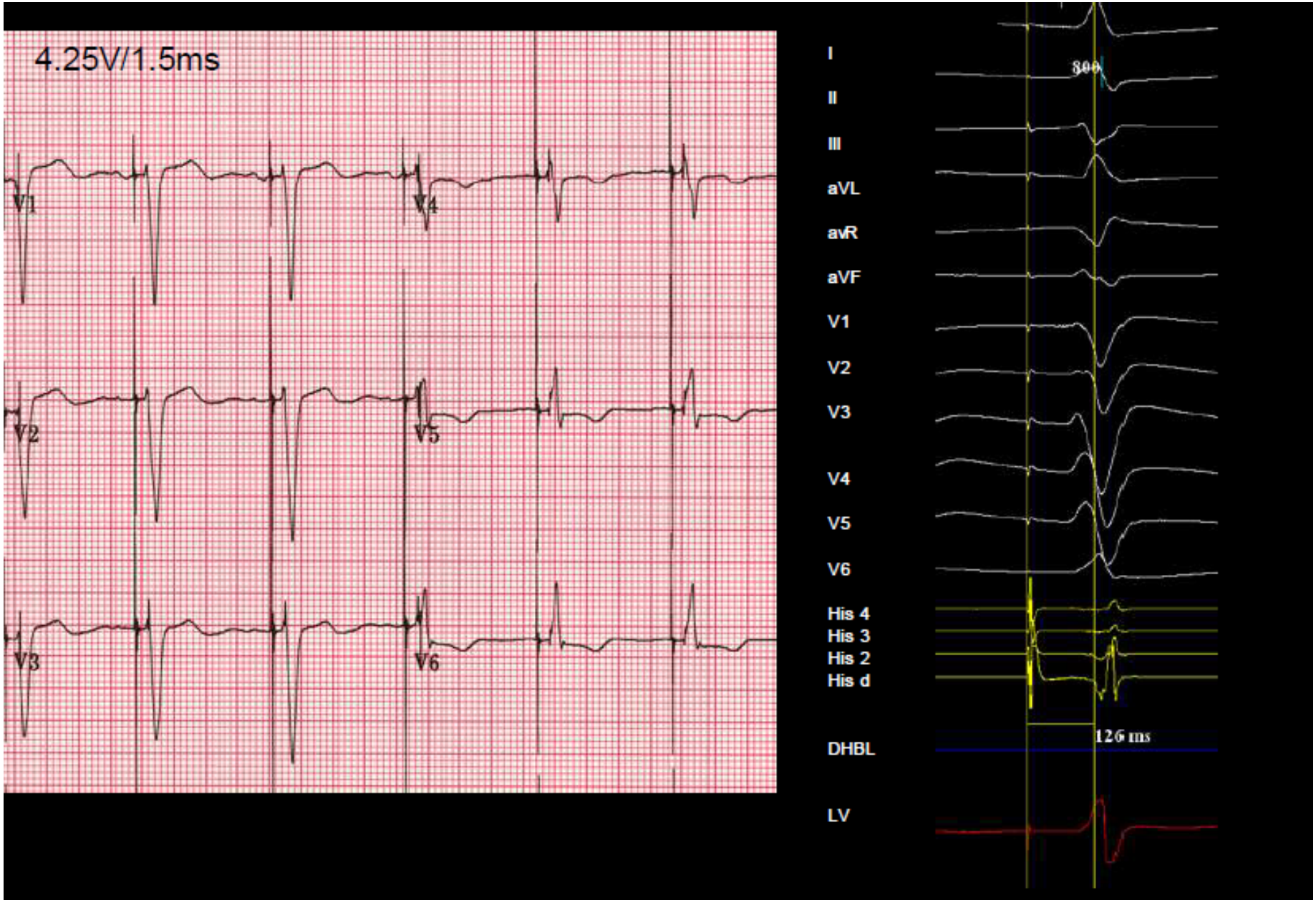

Lustgarten et al Heart Rhythm 2015;12:1548–1557

Selektif HBP

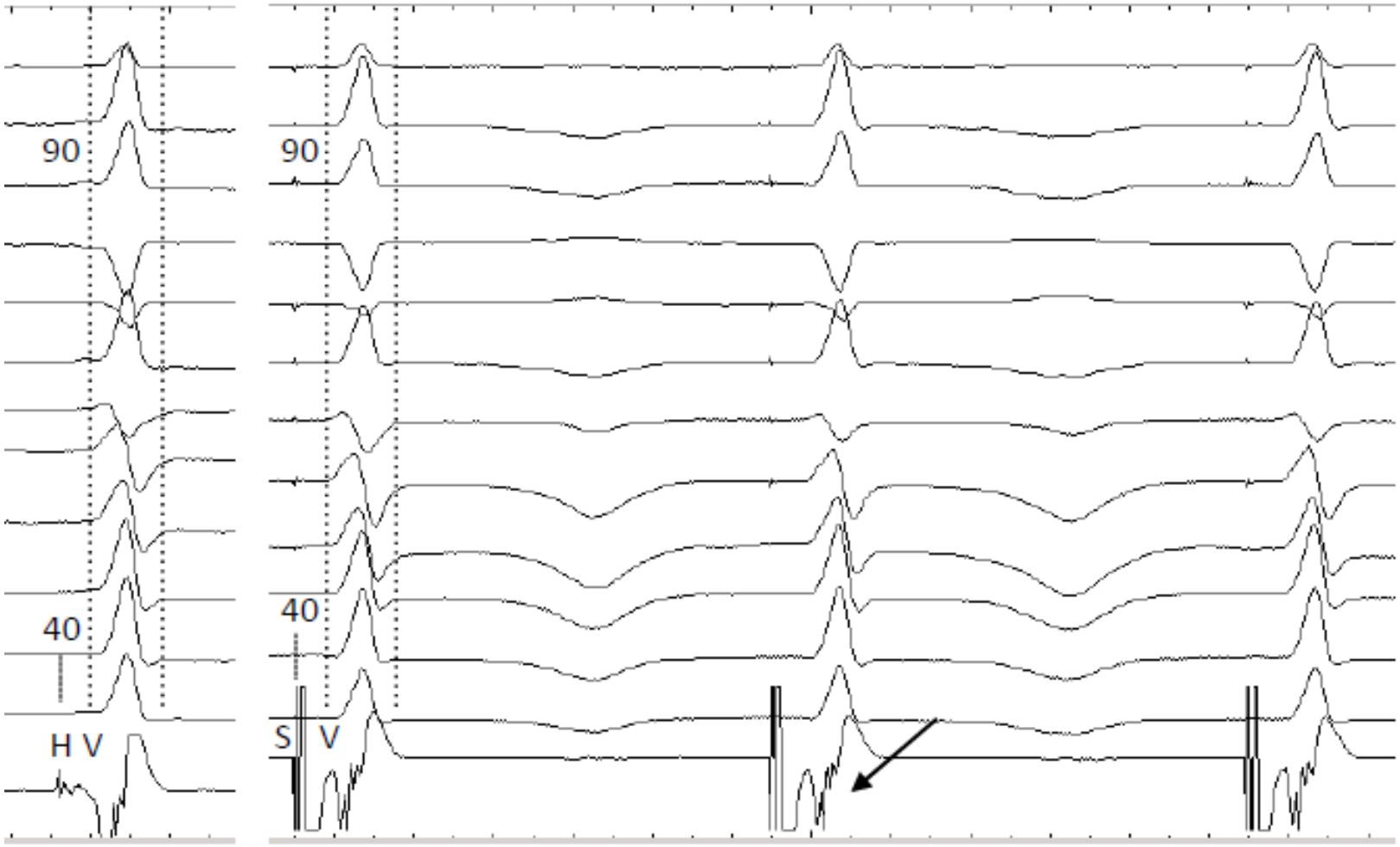

Non-selektif HBP

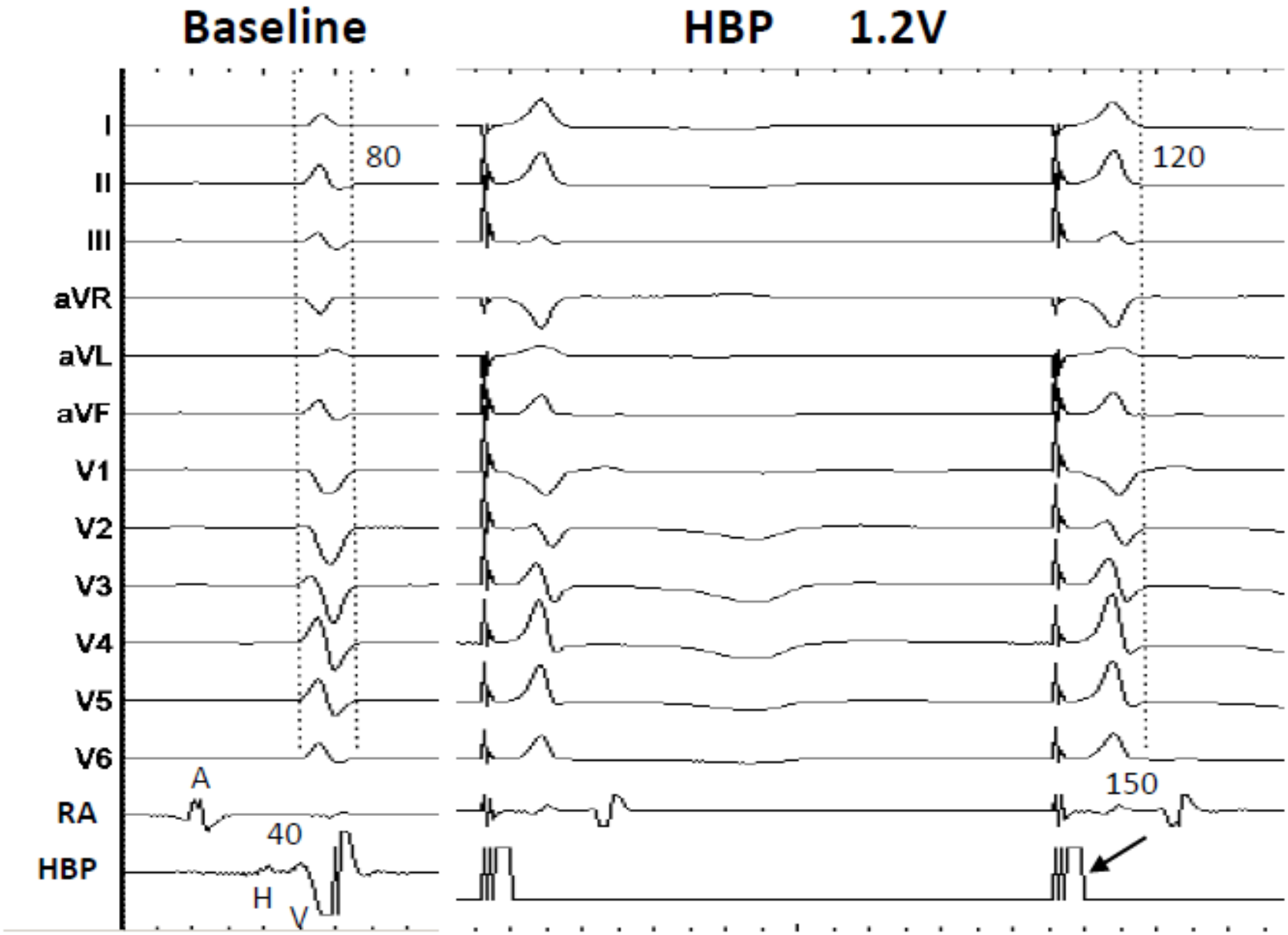

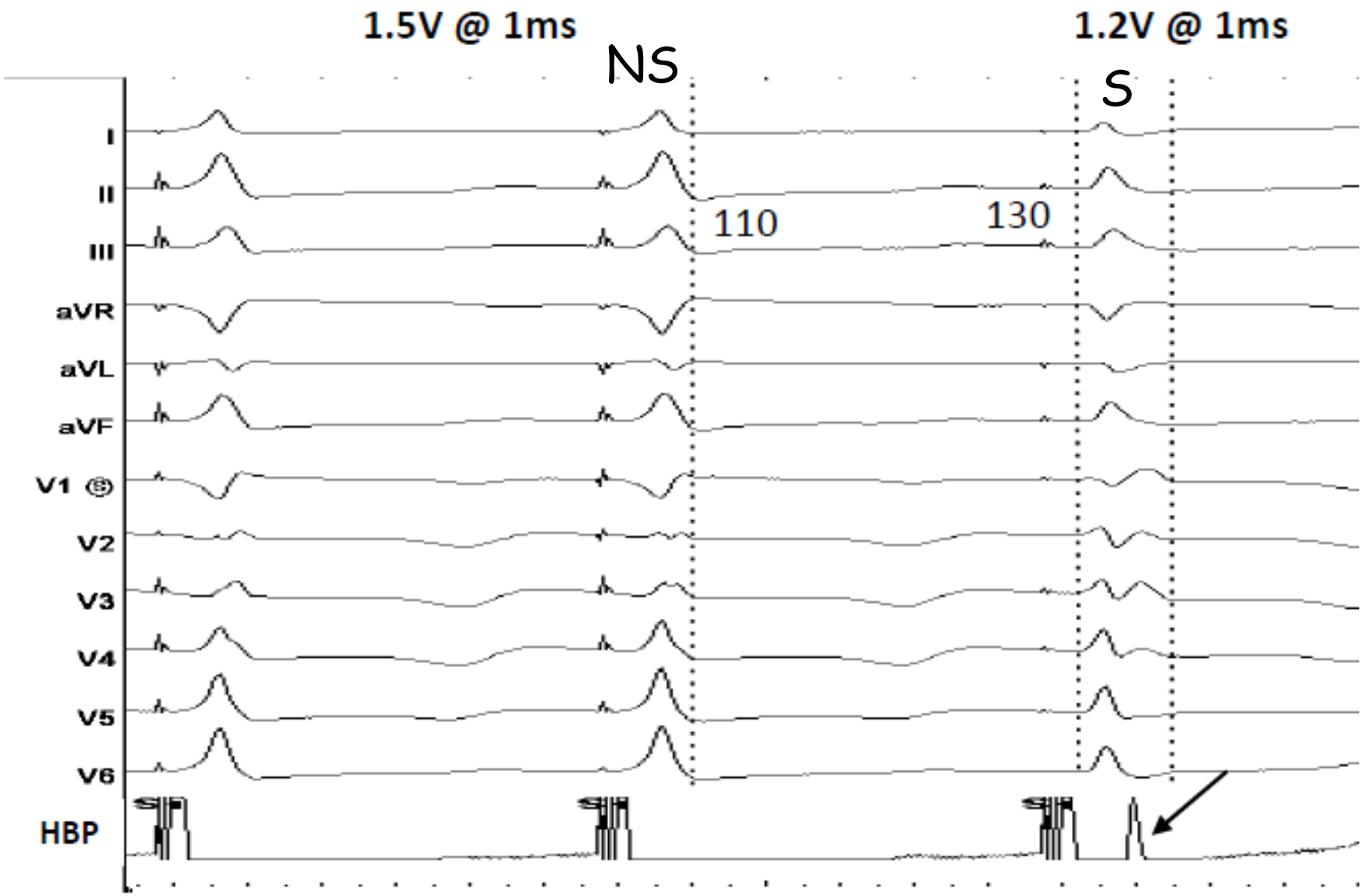
1.5V @ 1ms
NS
1.2V @ 1ms
S
110
130
I
II
III
aVR
aVL
aVF
V1
V2
V3
V4
V5
V6
HBP

Selective versus non-selective his bundle pacing for cardiac resynchronization therapy

Gaurav A. Upadhyay, MD, Roderick Tung, MD*

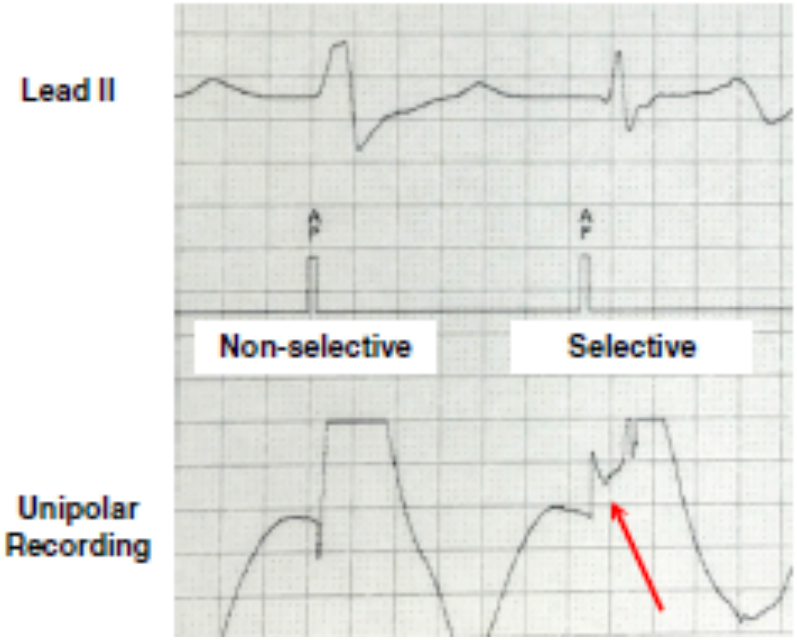

Degree of QRS narrowing with selective and non-selective His bundle capture across case reports and case series of CRT-eligible patients.

Study	Type of capture	Baseline QRS (ms)	HBP QRS (ms)	Change (%)
Case reports				
Dabrowski et al. [11]	Non-selective	160	100	−38%
Manovel et al. [12]	Selective	150	80	−47%
Rehwinkel et al. [13]	Non-selective	178	128	−28%
Wu et al. [14]	Selective	200	90	−55%
Shan et al. [15]	Non-selective	166	103	−38%
Ajijola et al. [16]	Non-selective	198	123	−38%
Case series				
Lustgarten et al. [18]	Non-selective	169 ± 16	160 ± 25	−5%
(n = 29)	Selective		131 ± 35	−23%

Selective His bundle capture is associated with a narrower final QRS width than non-selective capture, although both represent improvements from baseline QRS width.

Journal of Electrocardiology 50 (2017) 191 – 194

Atrioventricular node ablation and His bundle pacing

Pugazhendhi Vijayaraman*, Faiz A. Subzposh, and Angela Naperkowski

Europace (2017) **19**, iv10–iv16

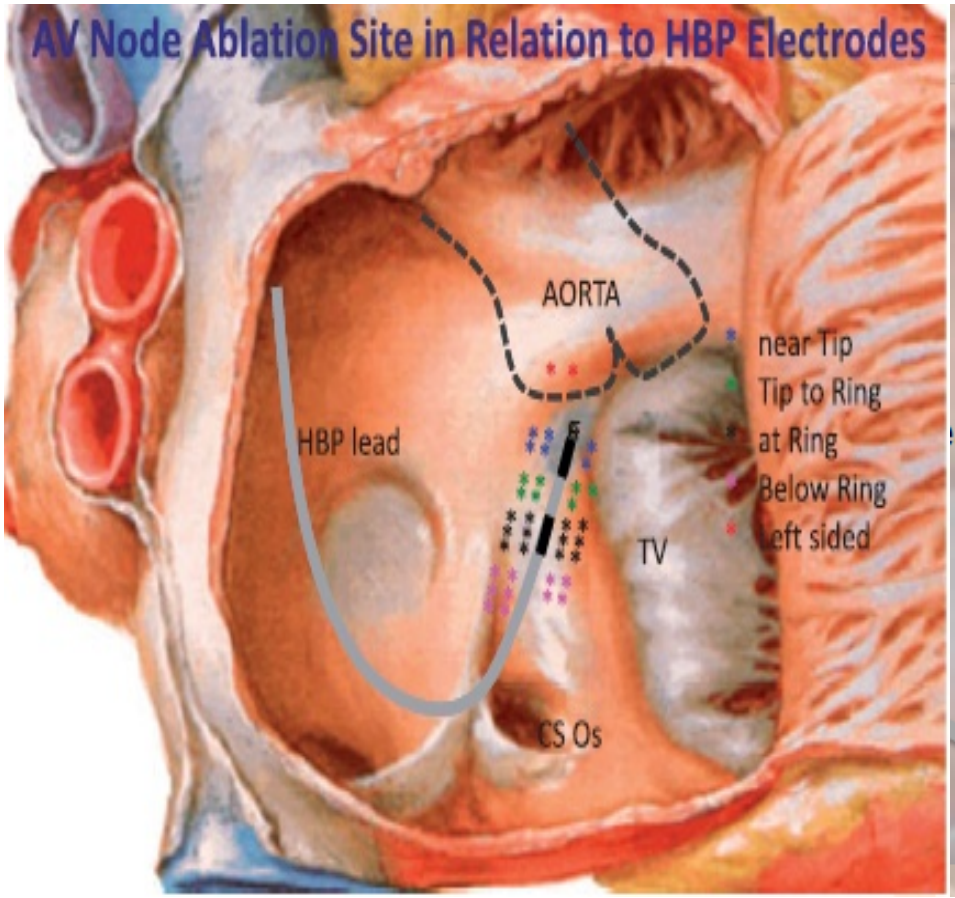

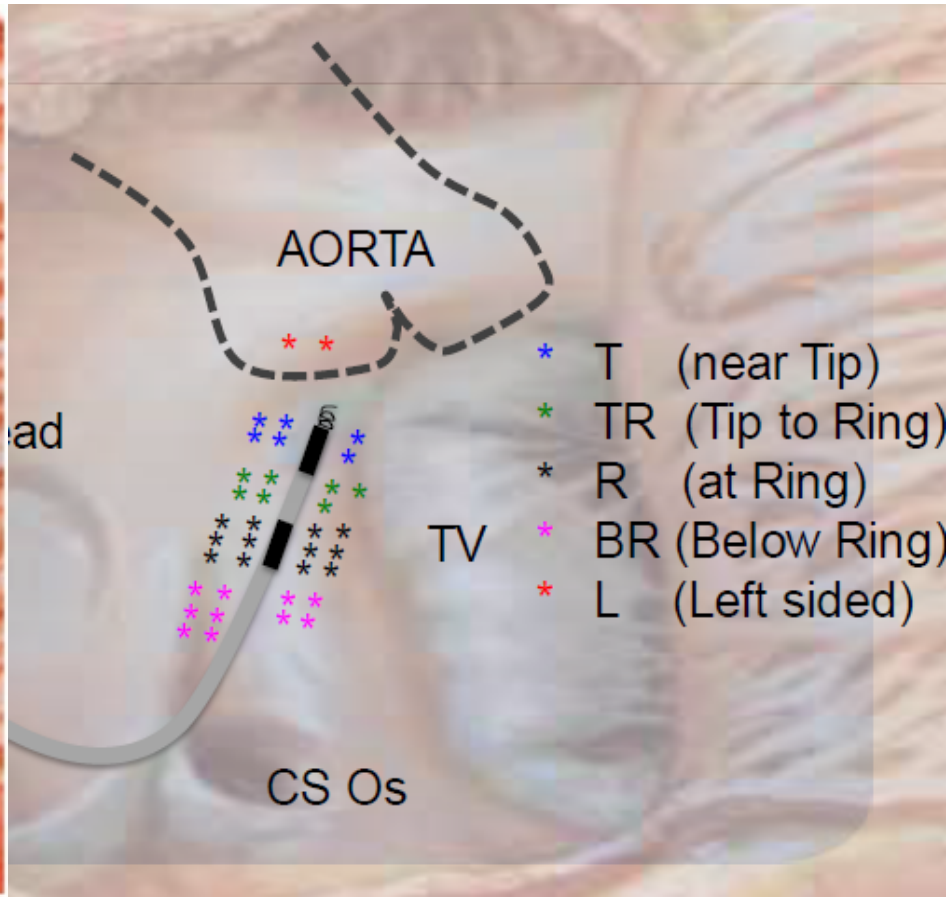

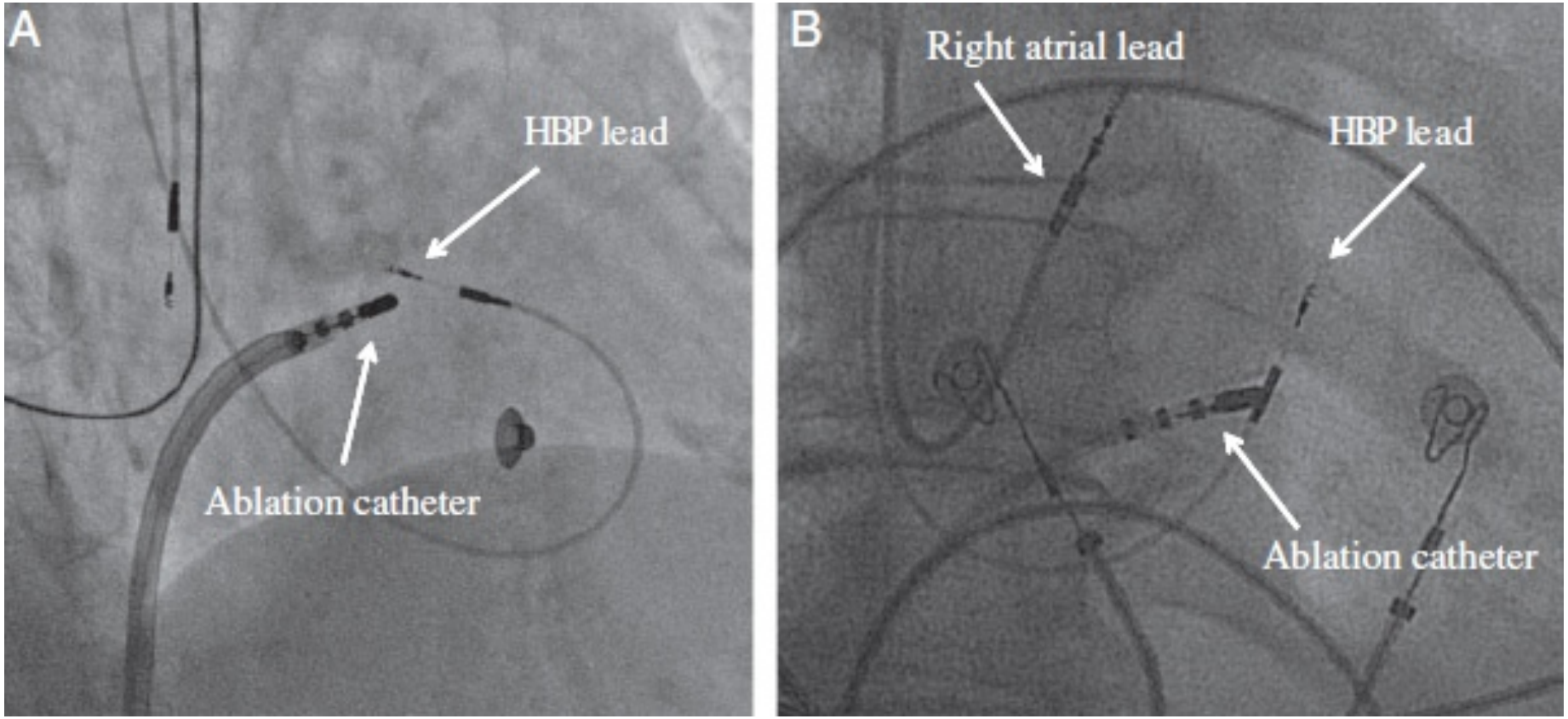

Europace (2017) **19**, iv10–iv16

42/40 başarılı
42/30 aynı seansta AVNA-His pace

Electrophysiologic Insights Into Site of Atrioventricular Block

Lessons From Permanent His Bundle Pacing

JACC: CLINICAL ELECTROPHYSIOLOGY VOL. 1, NO. 6, 2015

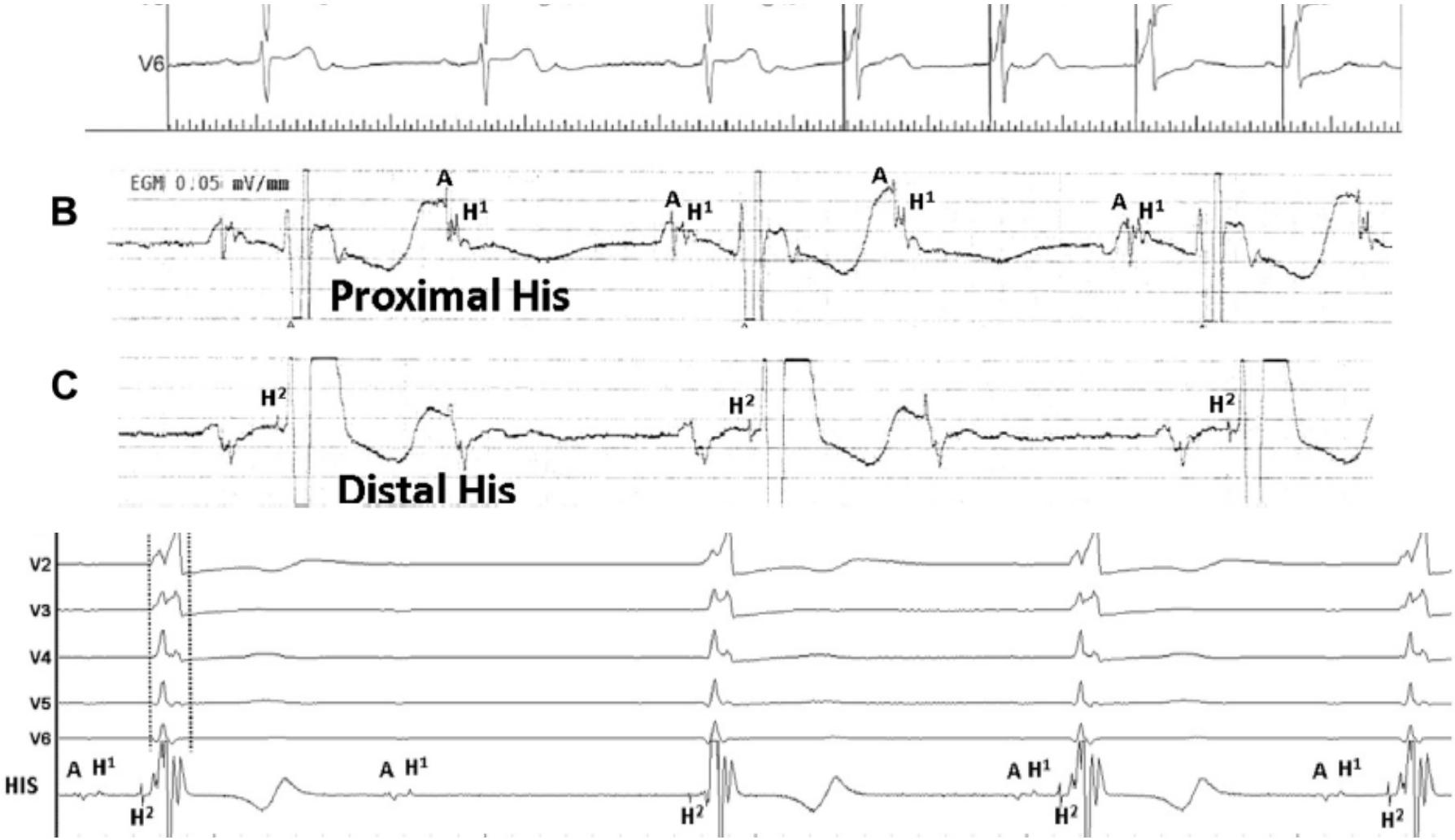

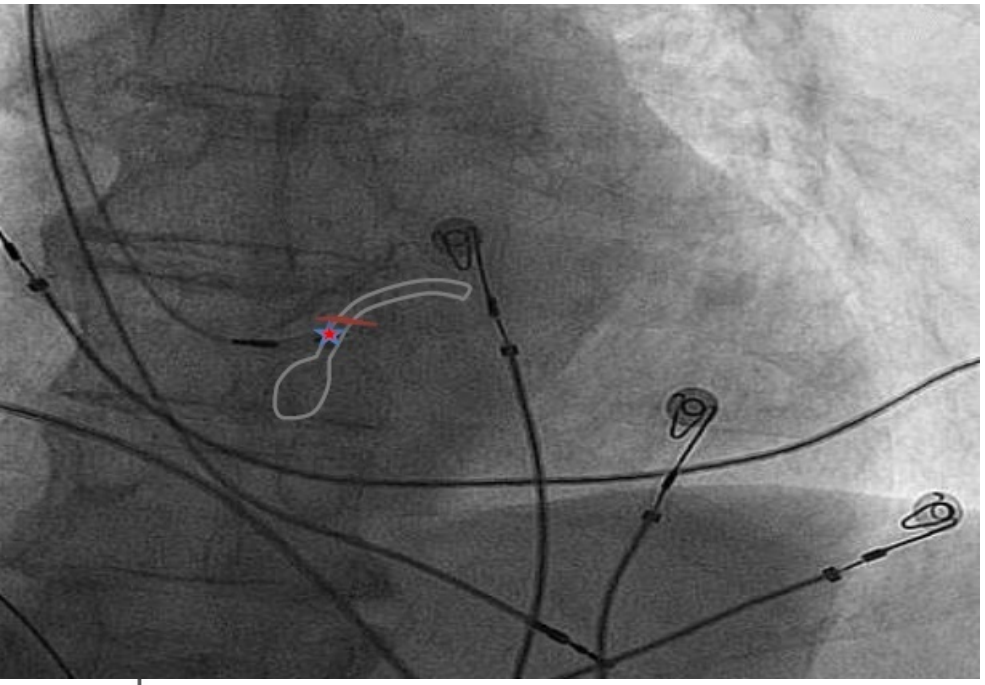

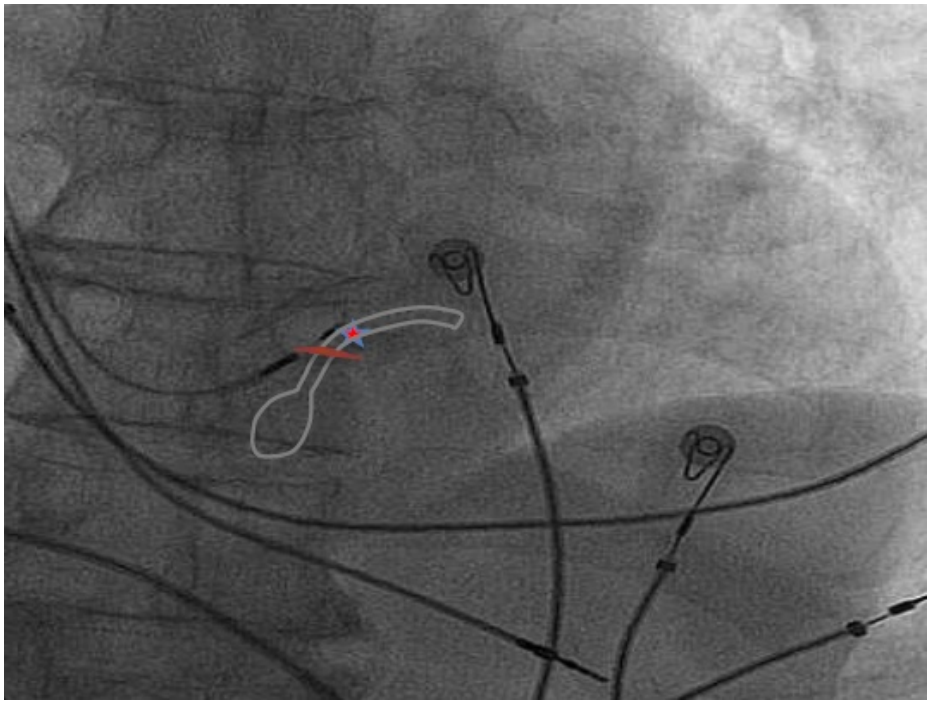

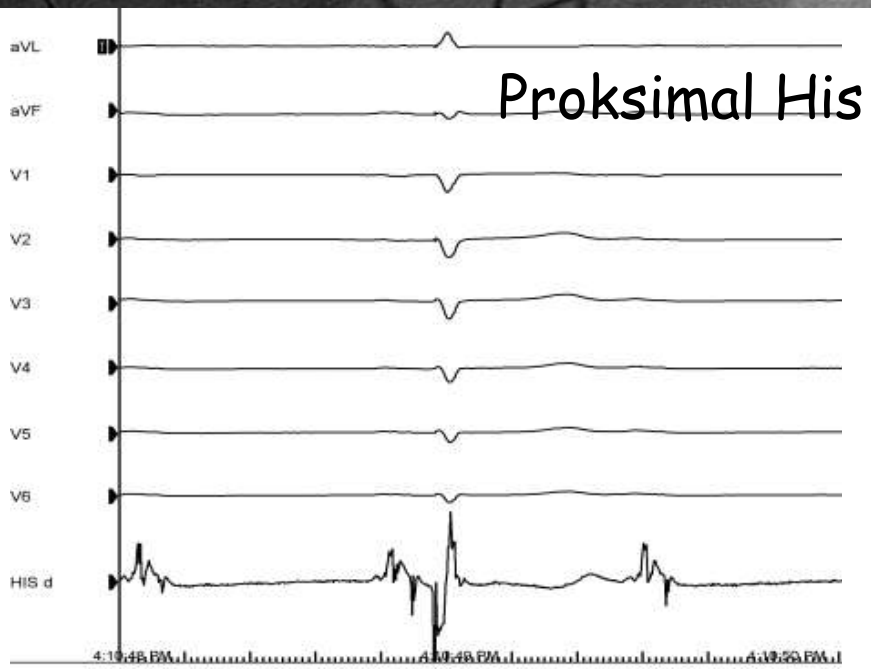

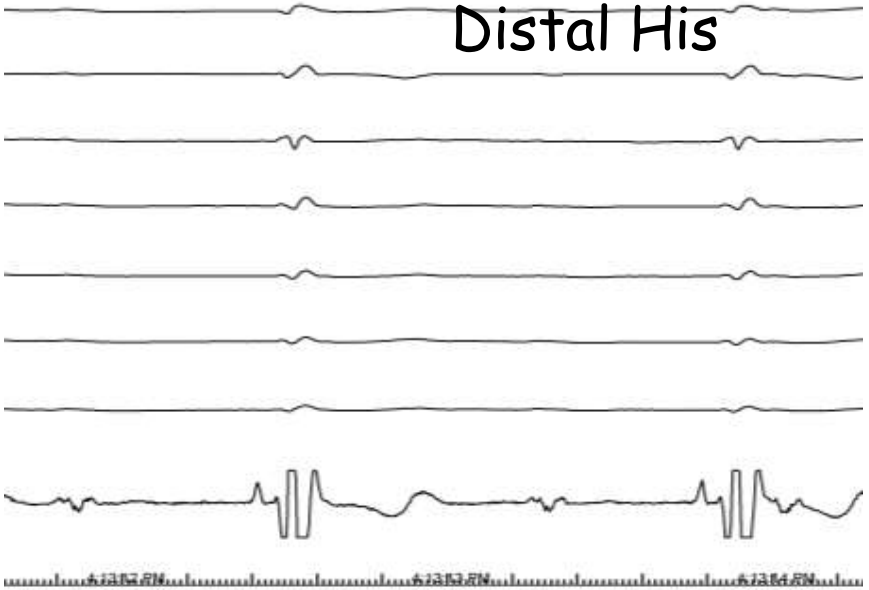

Pugazhendhi Vijayaraman

TEŞEKKÜRLER