10. Atriyal Fibrilasyon Zirvesi 2021

11–13 Kasım 2021 • Calista Kongre Merkezi Antalya



Klinik Kabus I: Çıkım Yolu Taşikardileri

Sağ ve Sol Ventrikül Çıkım Yolunun Anatomisi

Dr Umuttan Doğan

Akdeniz Üniversitesi Tıp Fakültesi Kardiyoloji AD

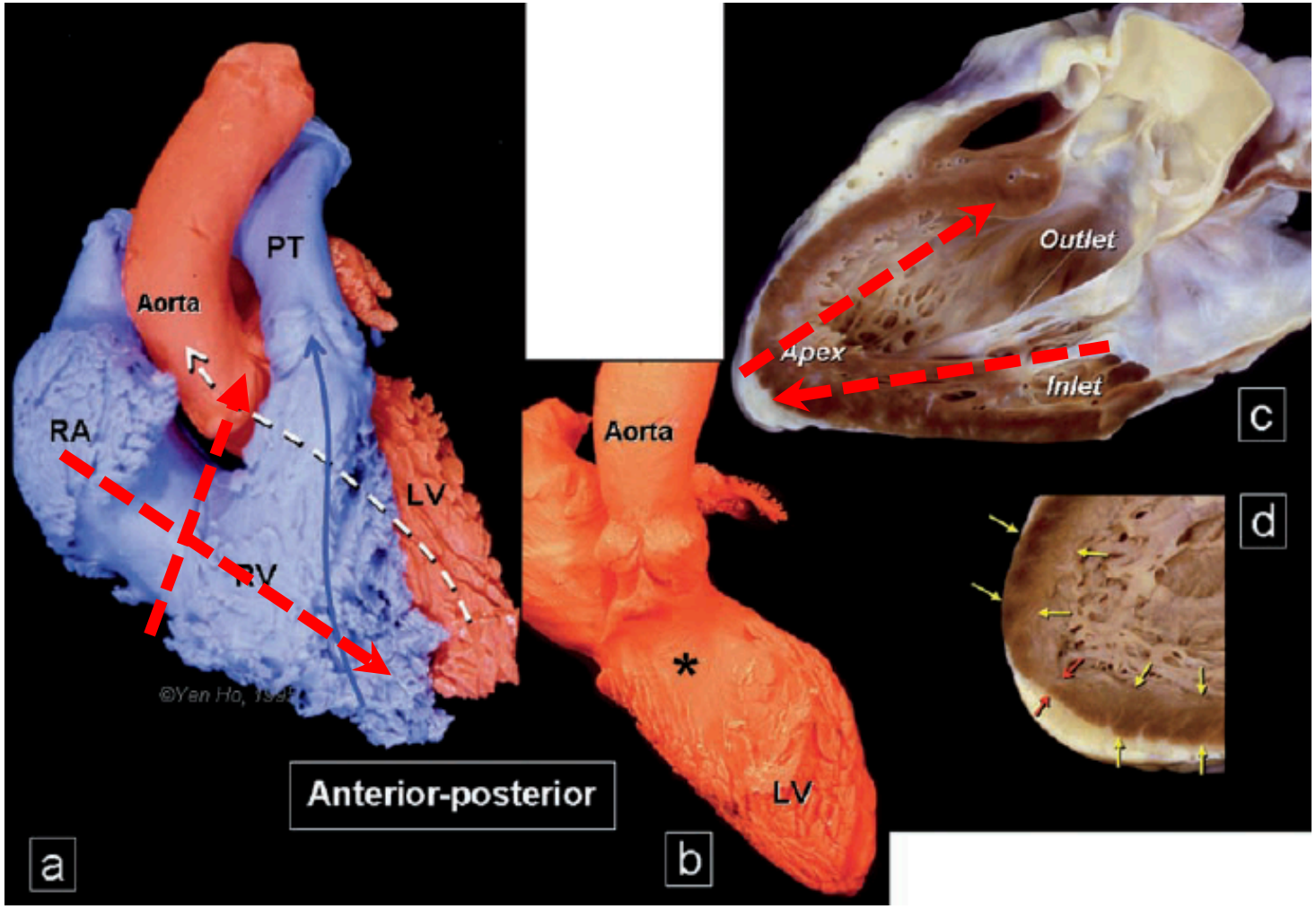
PT
Aorta
RA
LV
RV
©Yen Ho, TSEP
Anterior-posterior
a
Aorta
*
LV
b
Outlet
Apex
Inlet
c
d

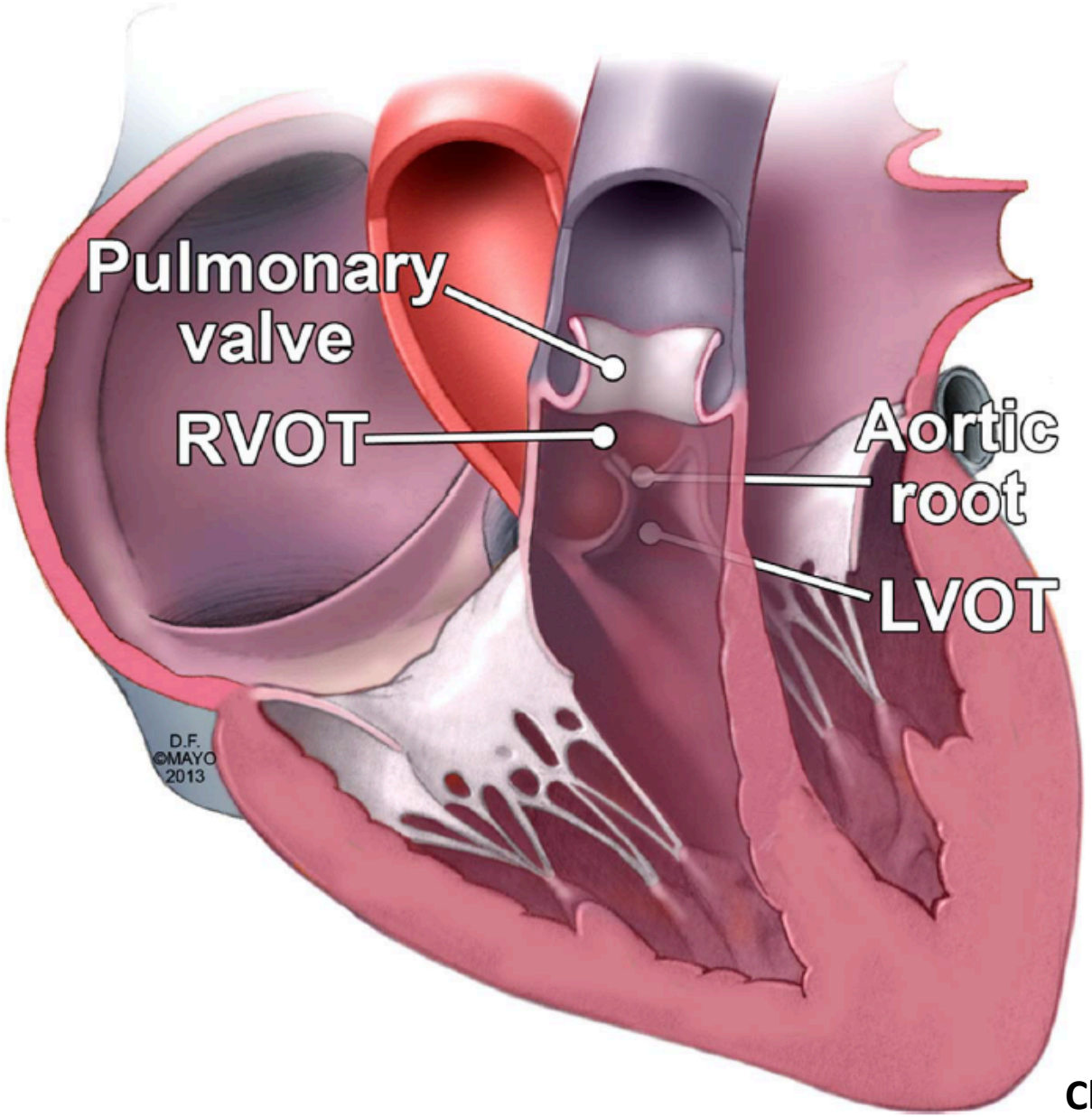

Clin Anat 2014;27(6): 885–893

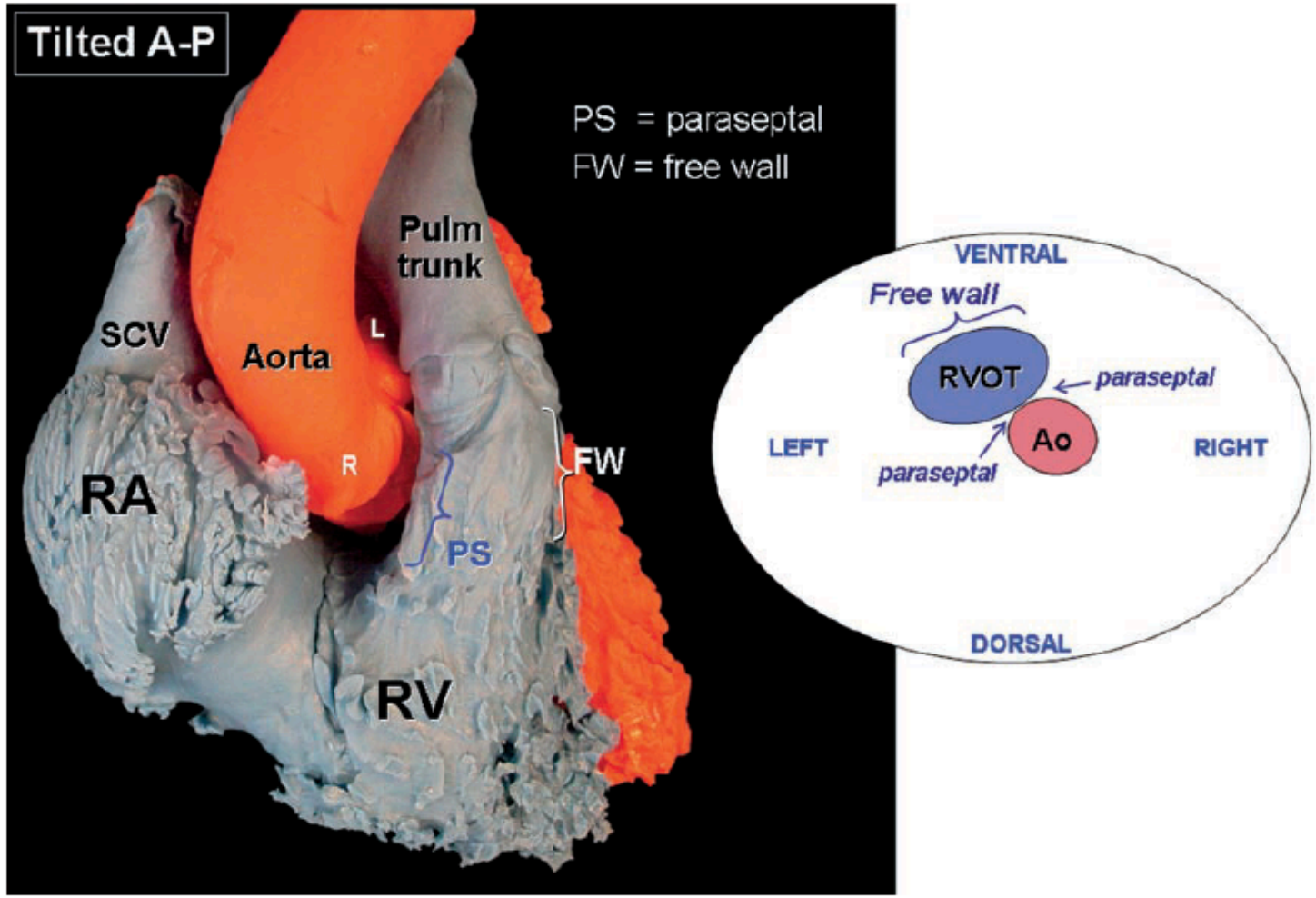
Tilted A-P
PS = paraseptal
FW = free wall
Pulm trunk
SCV
Aorta
L
R
RA
FW
PS
RV
VENTRAL
Free wall
RVOT
paraseptal
Ao
LEFT
RIGHT
paraseptal
DORSAL

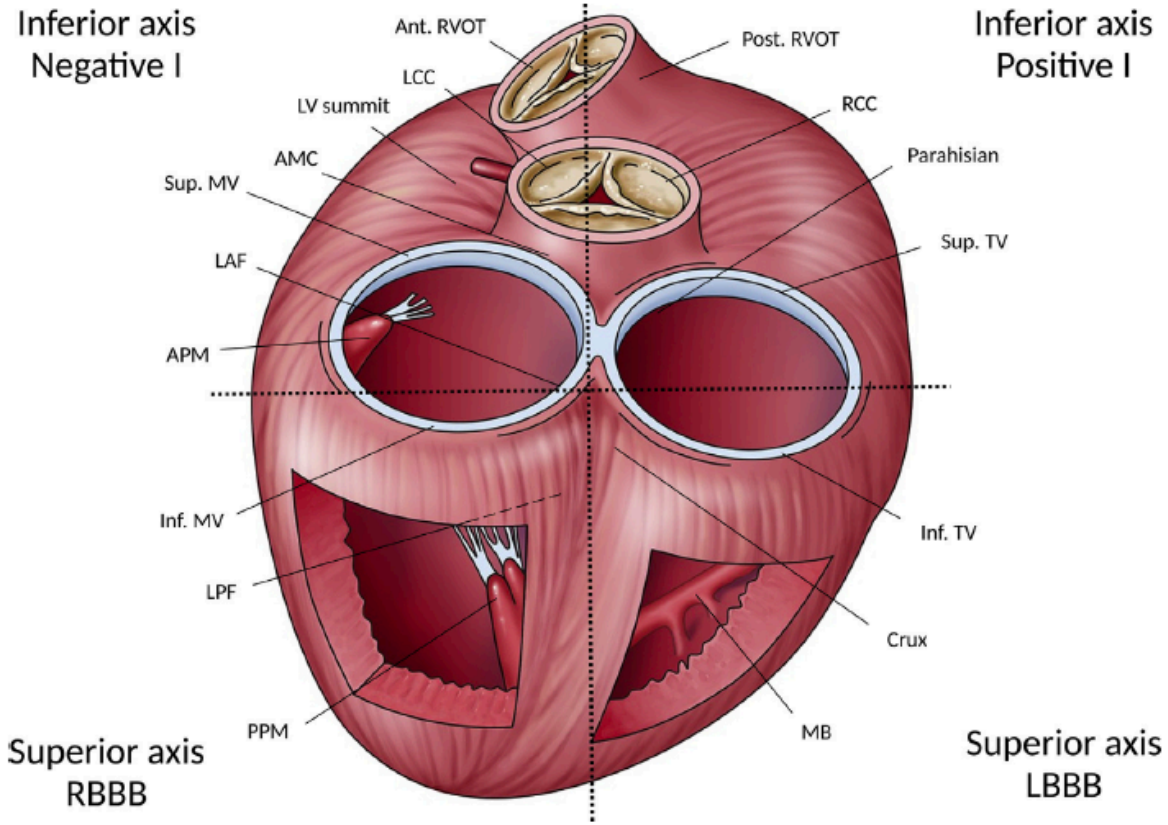

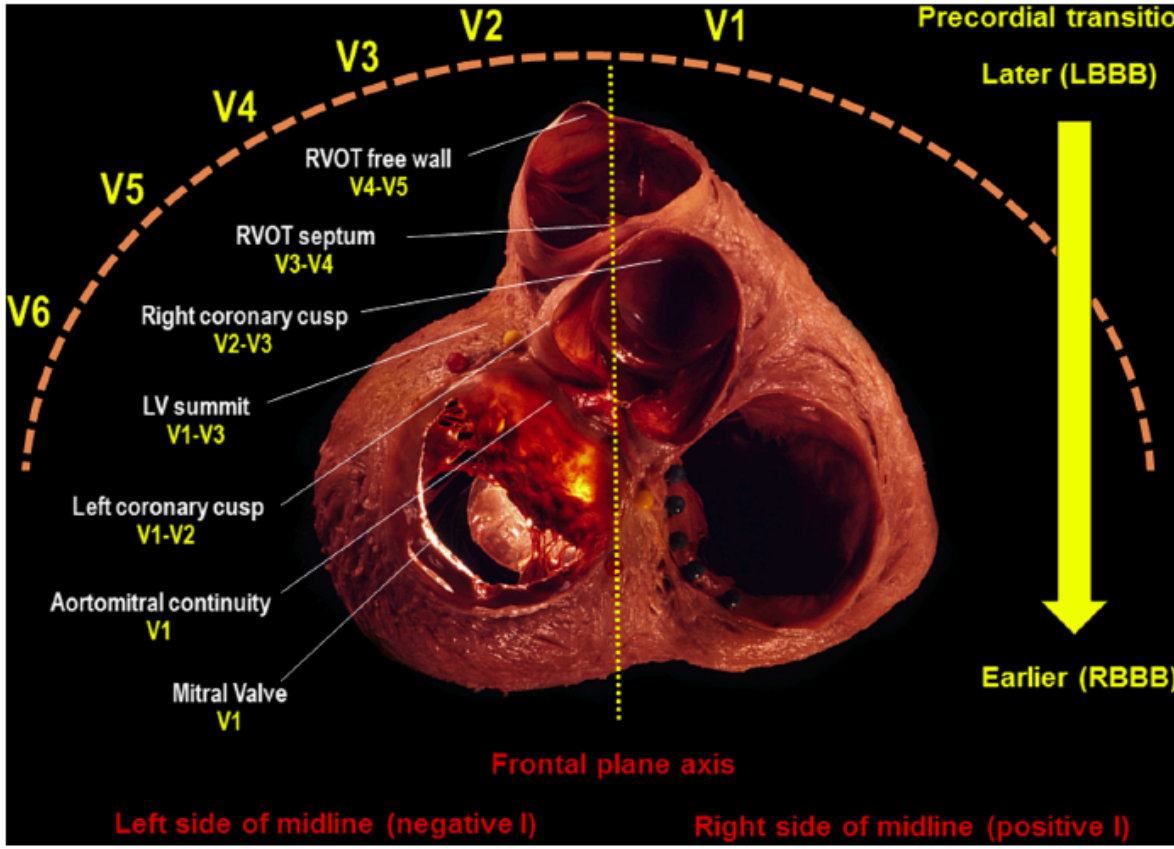

Heart Rhythm 2019;16:1538–1544

D1: QS varsa pulmoner kapak lokalizasyonuna bakılmalı!

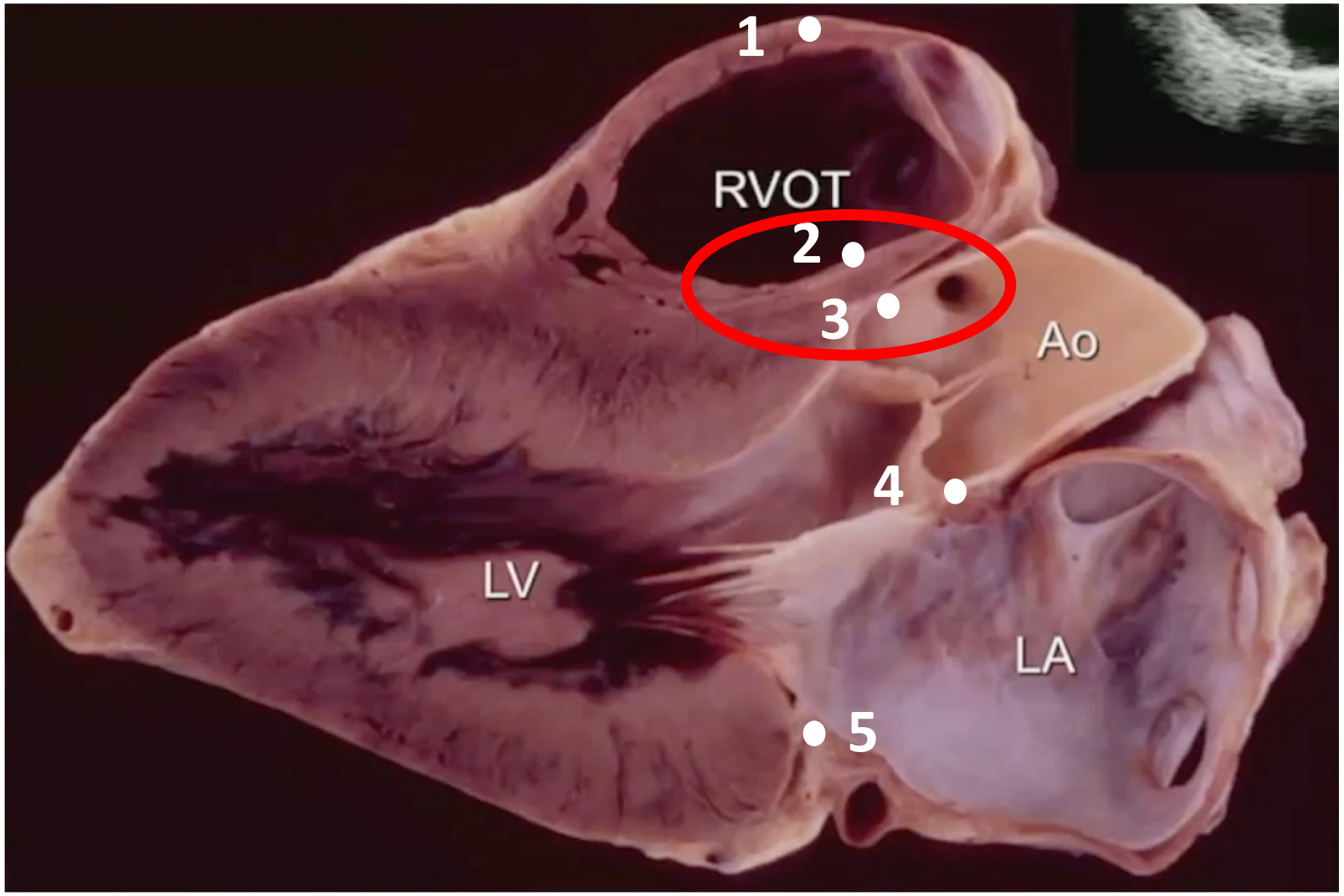

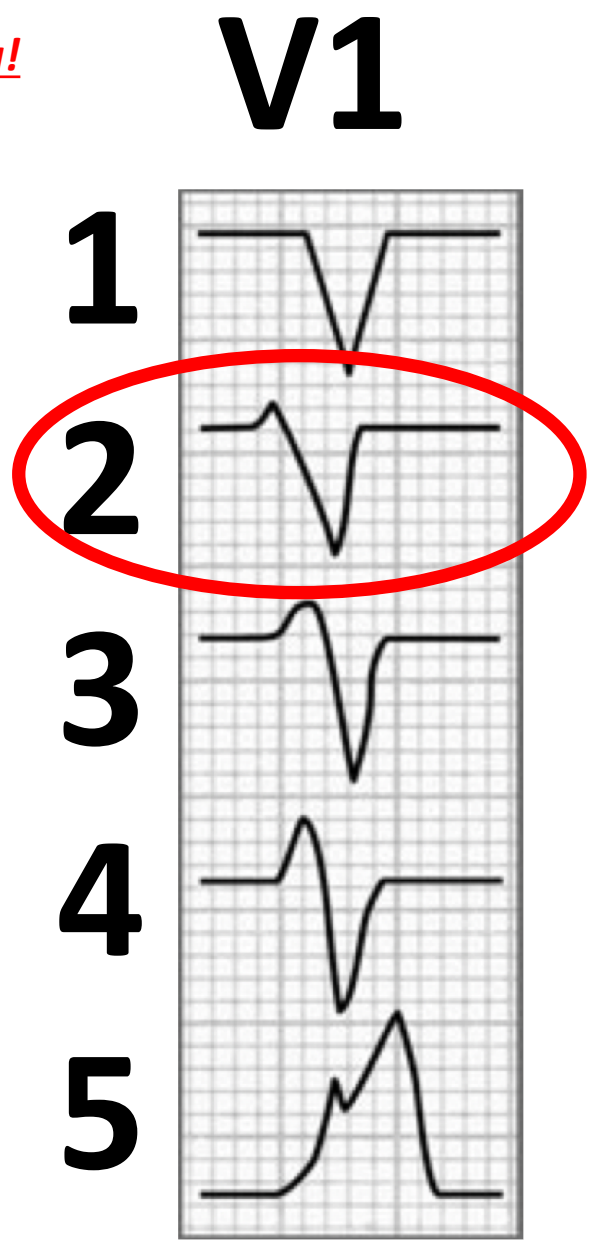

J Cardiovasc Electrophysiol 2009;20:955-968

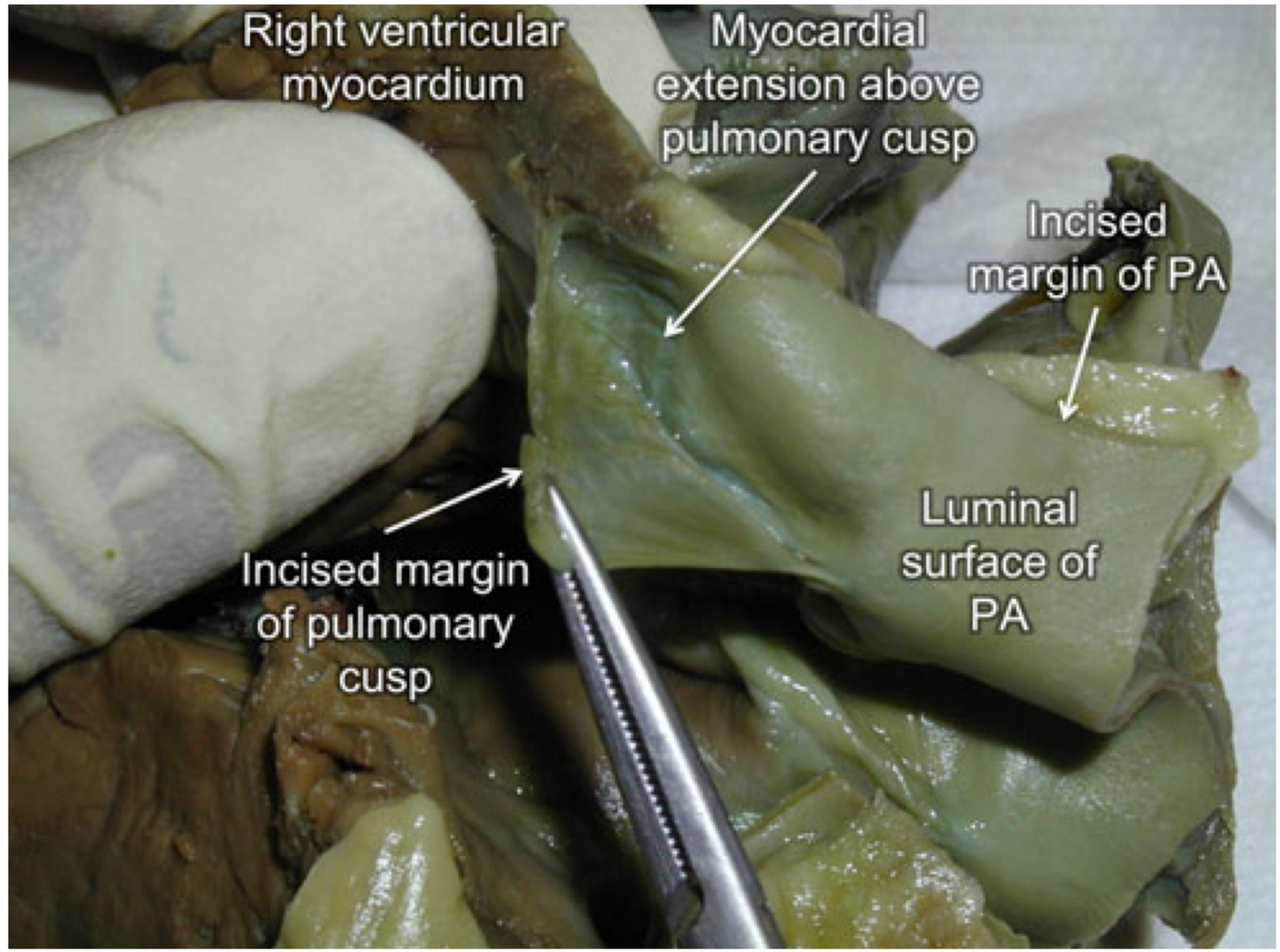

J Interv Card Electrophysiol (2011) 30:5–15

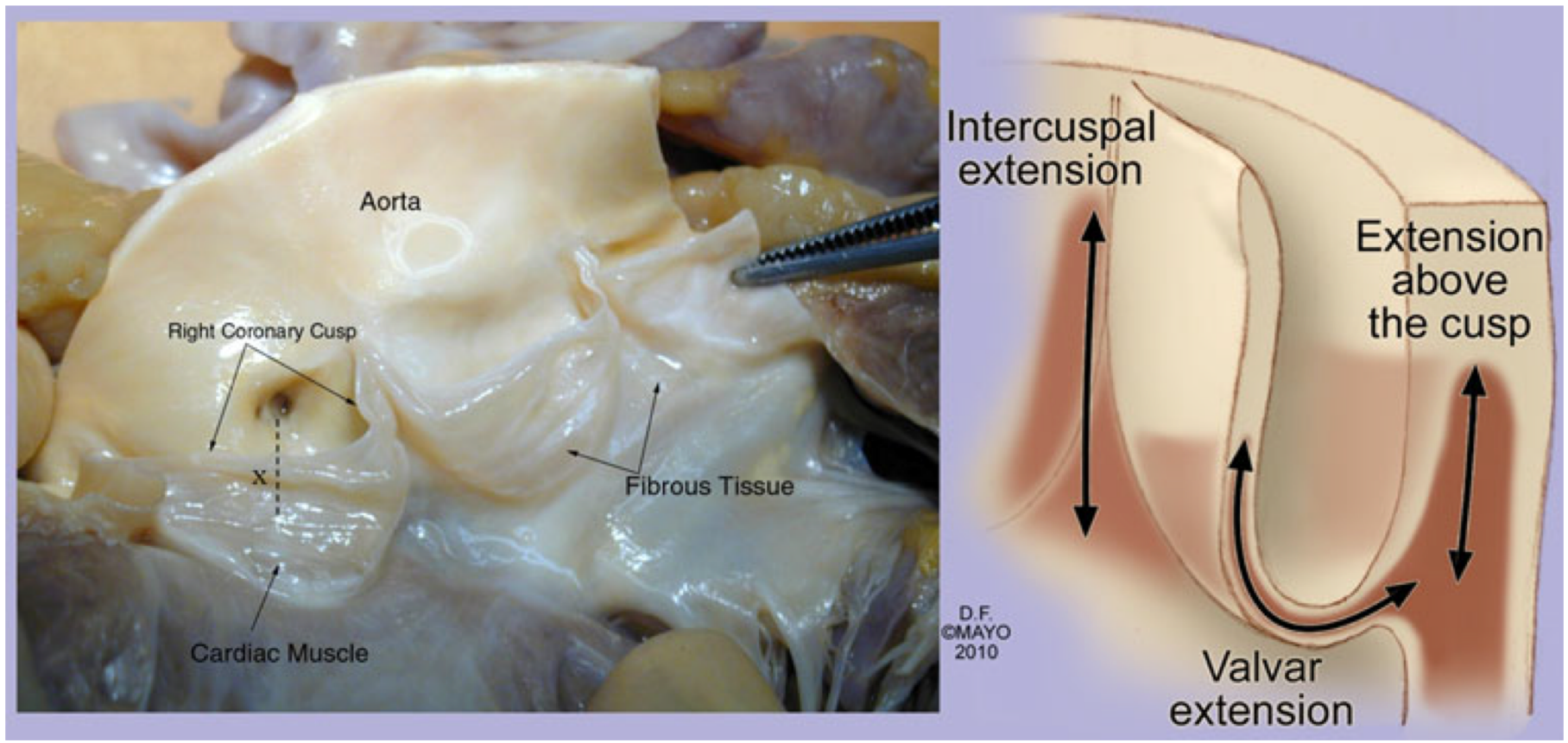

J Interv Card Electrophysiol (2011) 30:5–15

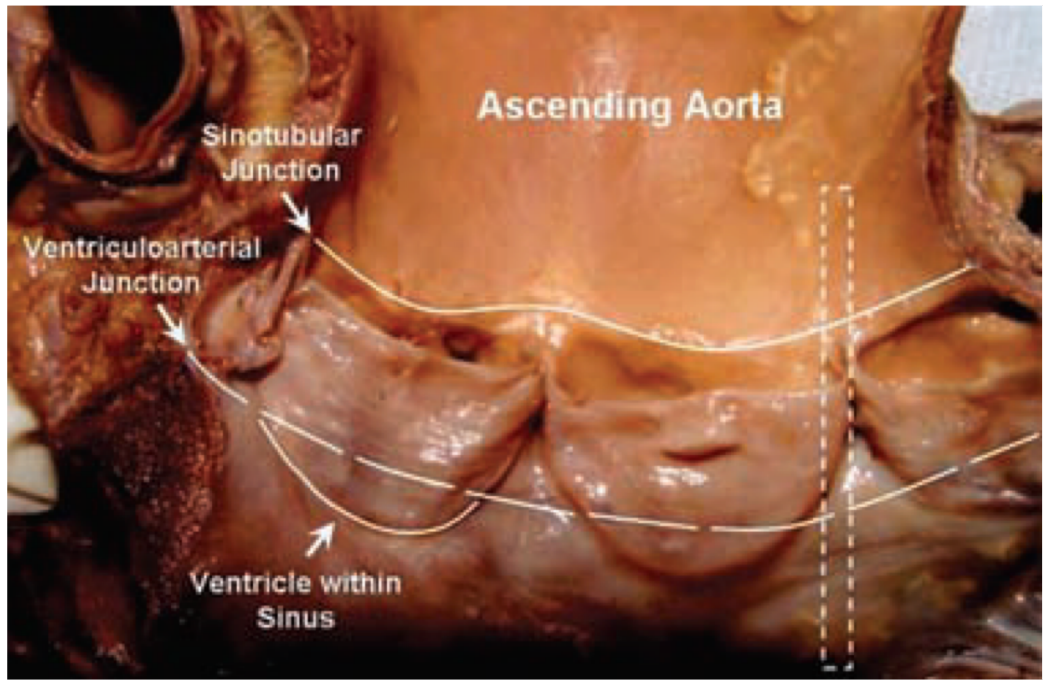

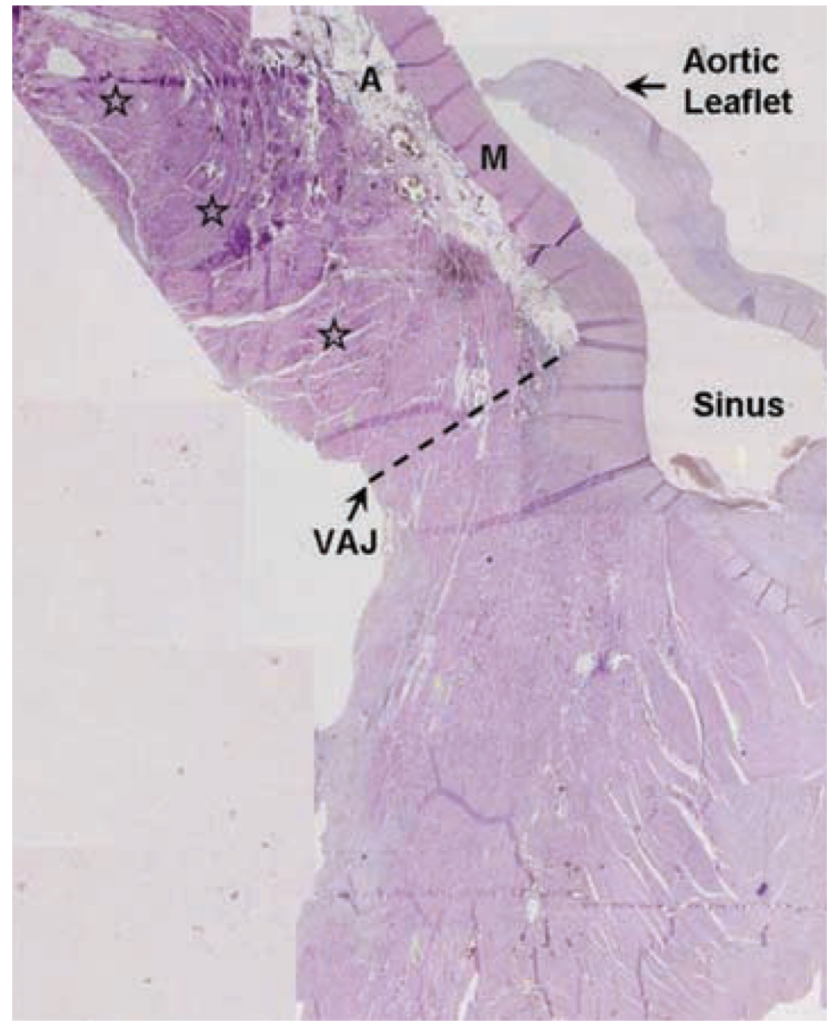

Hasdemir et al. PACE 2007; 30:534–539

Supravalvüler orijinli VTlerin ablasyonu

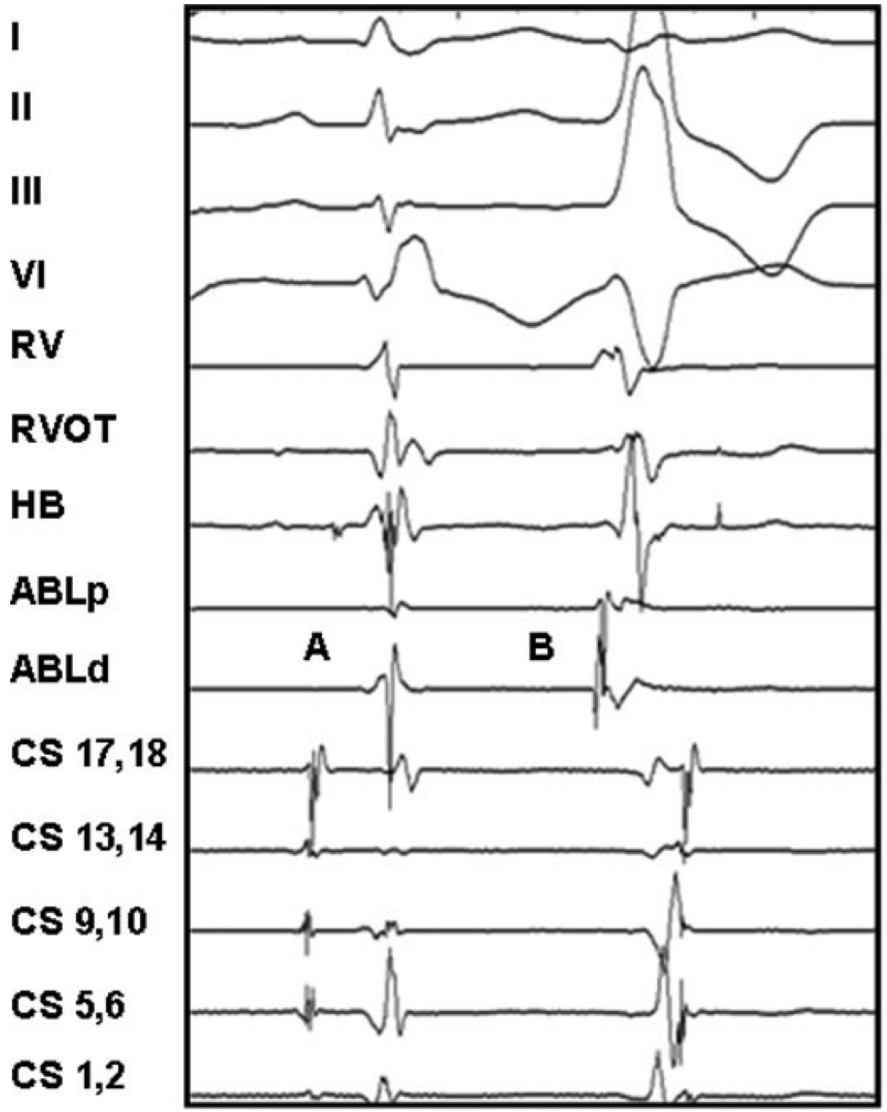

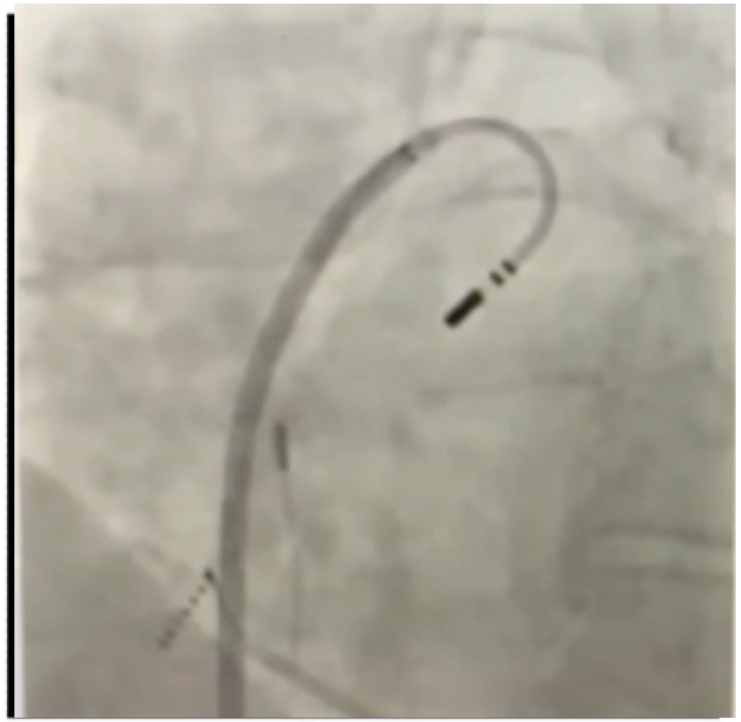

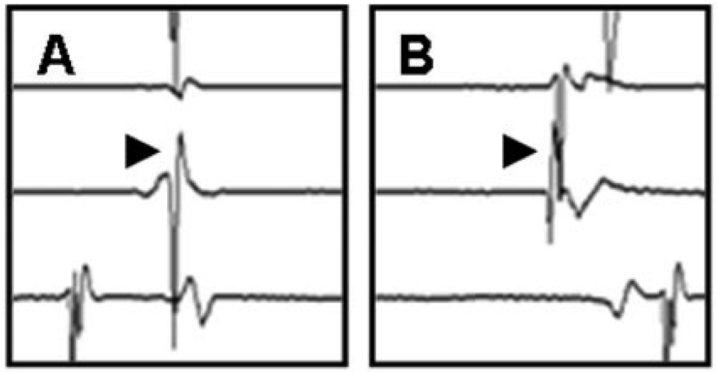

Circ Arrhythmia Electrophysiol. 2008;1:30-38

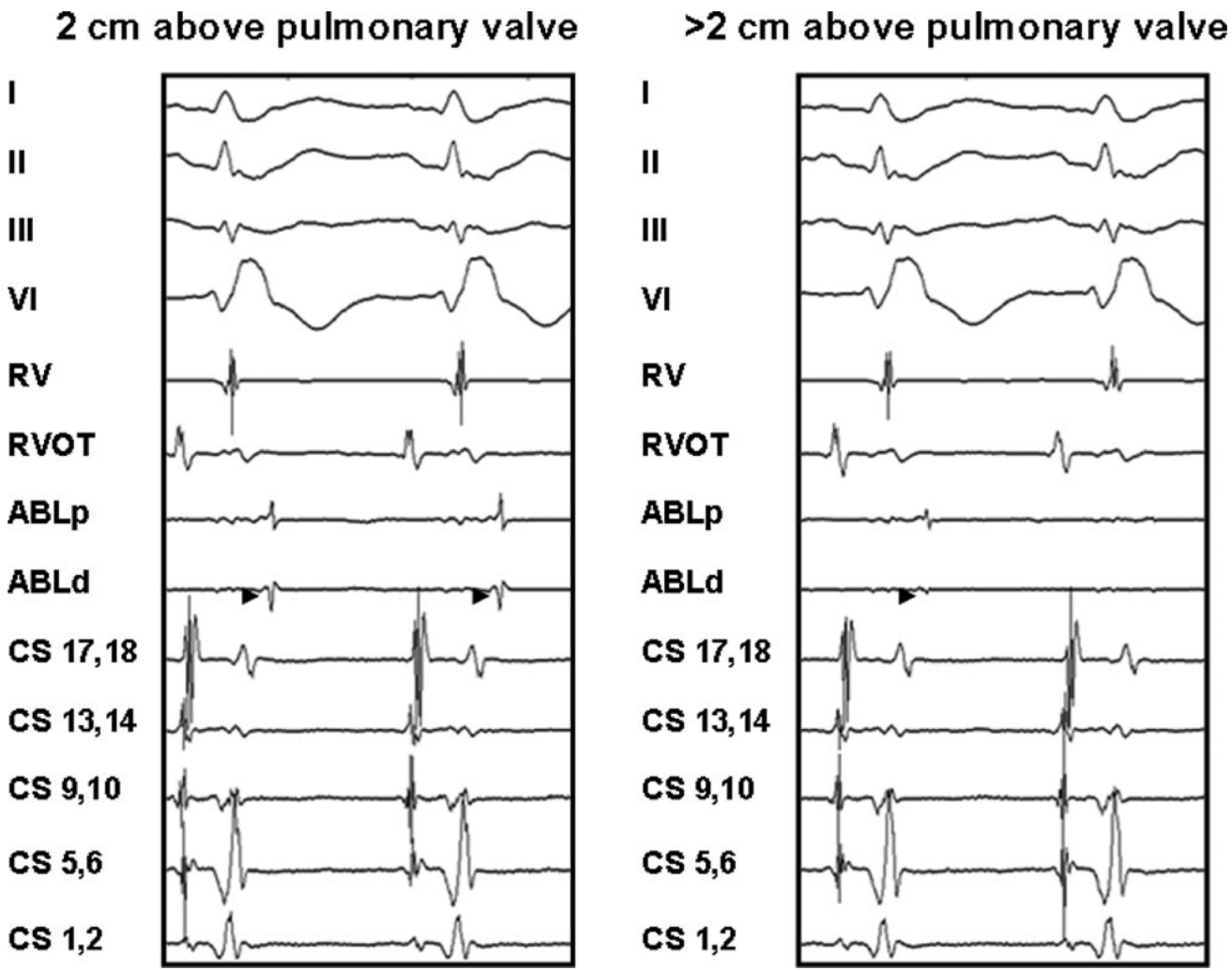

Circ Arrhythmia Electrophysiol. 2008;1:30-38

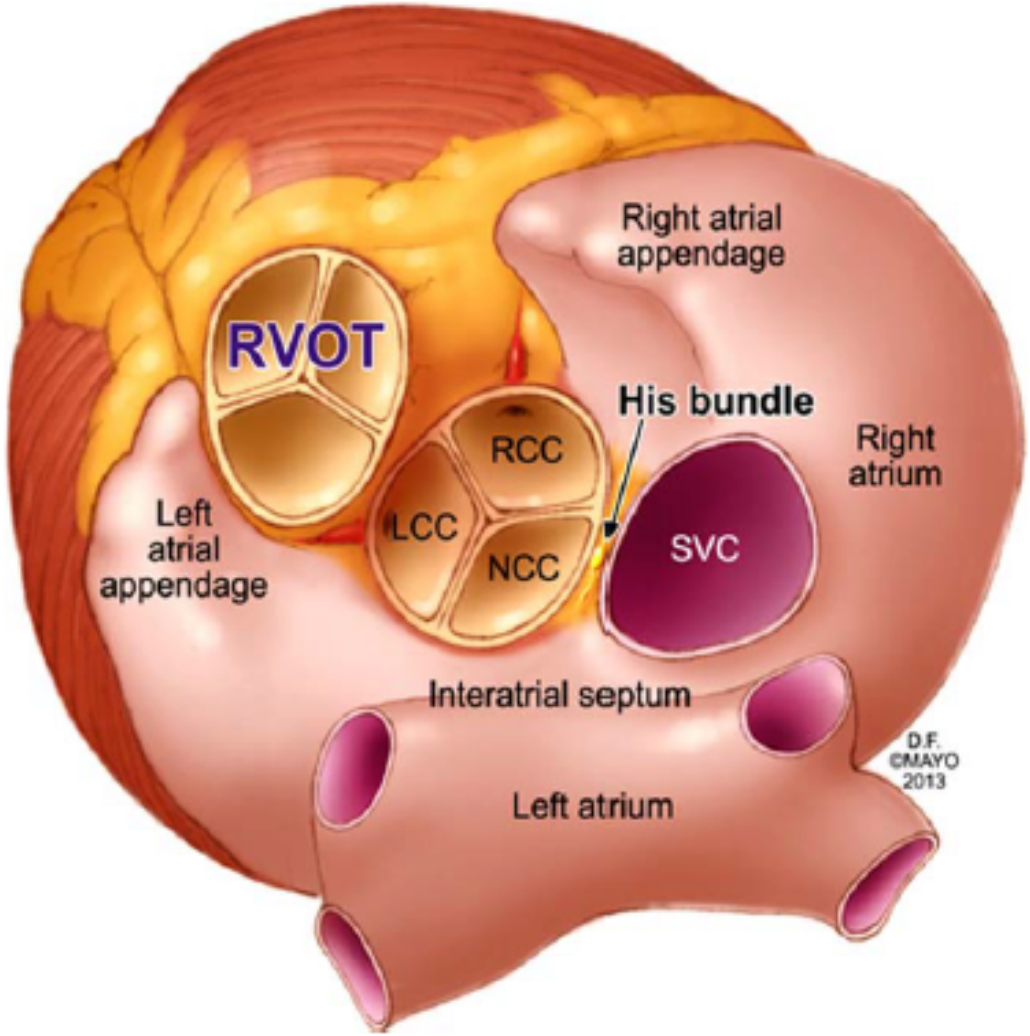

Clin Anat 2014;27(6): 885–893

RVOT

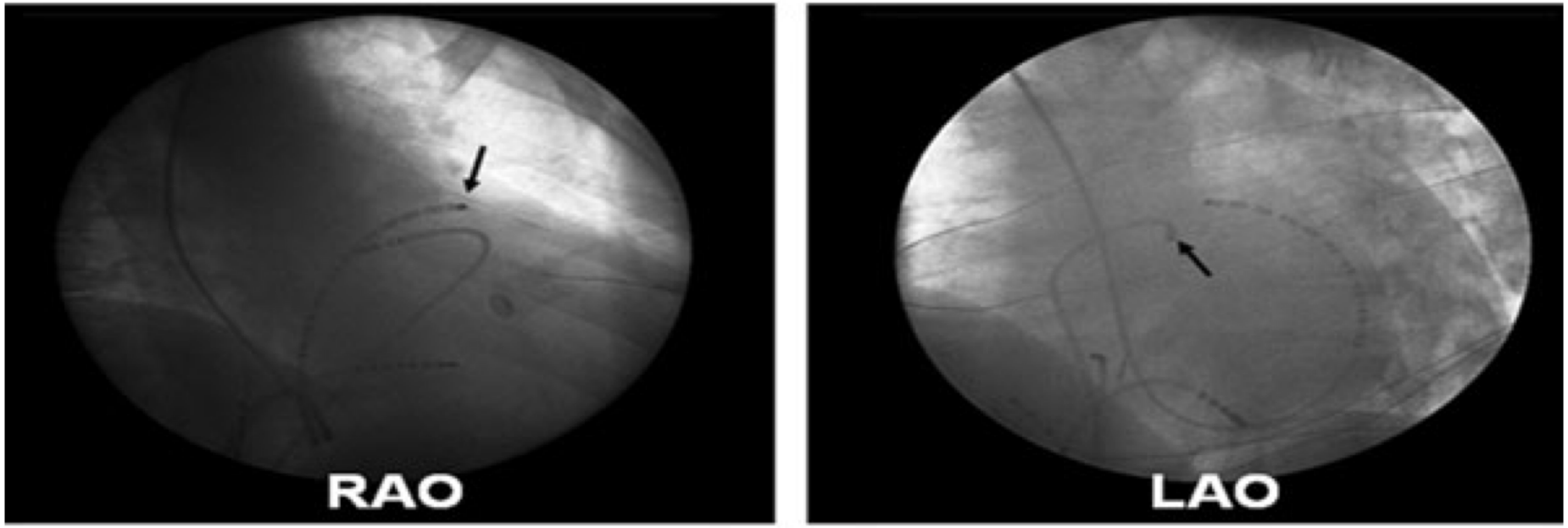

J Cardiovasc Electrophysiol 2009;20:955-968

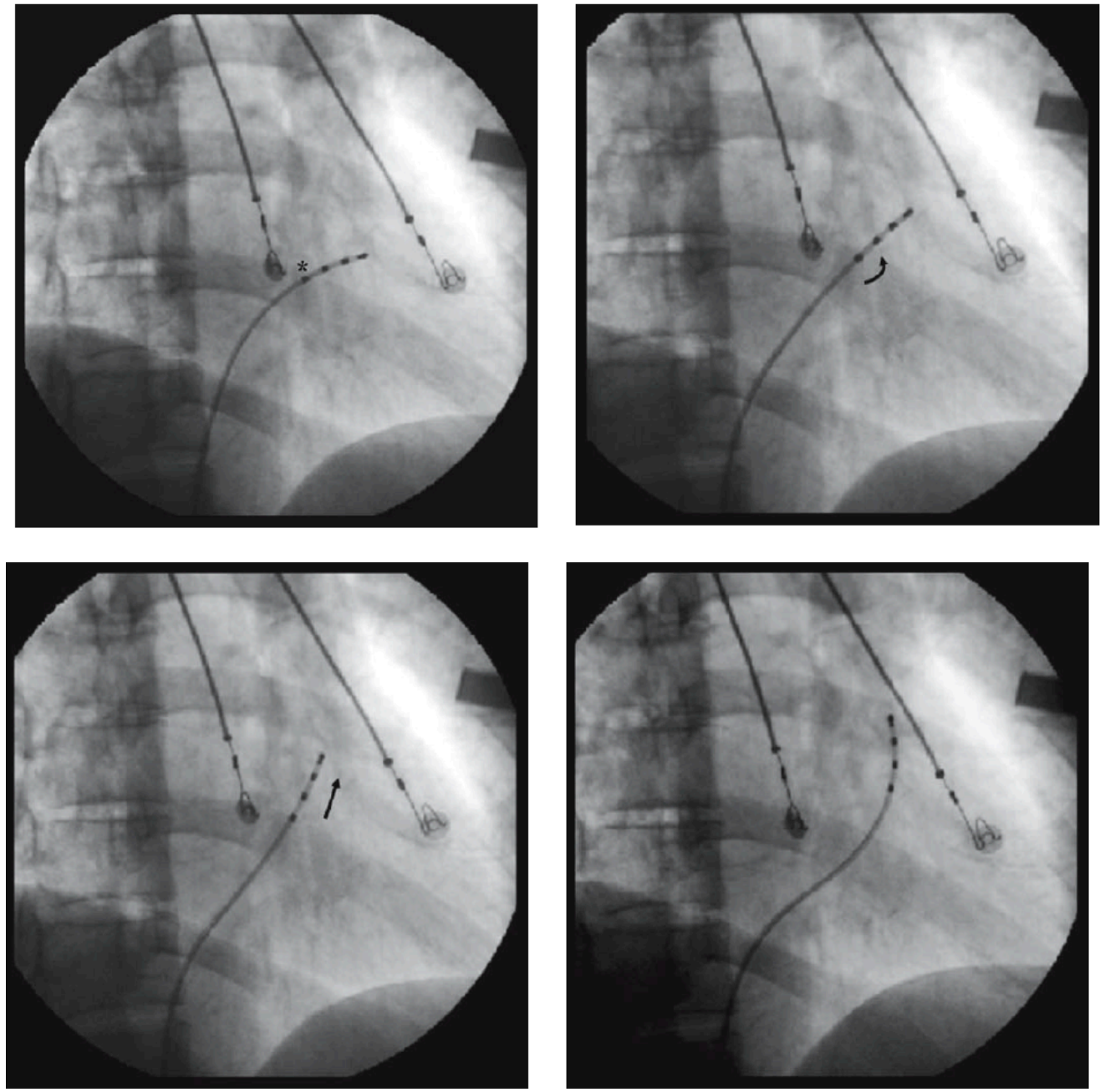

Casella, Della Russo. Springer 2008; 1st ed.

RVOT

LVOT

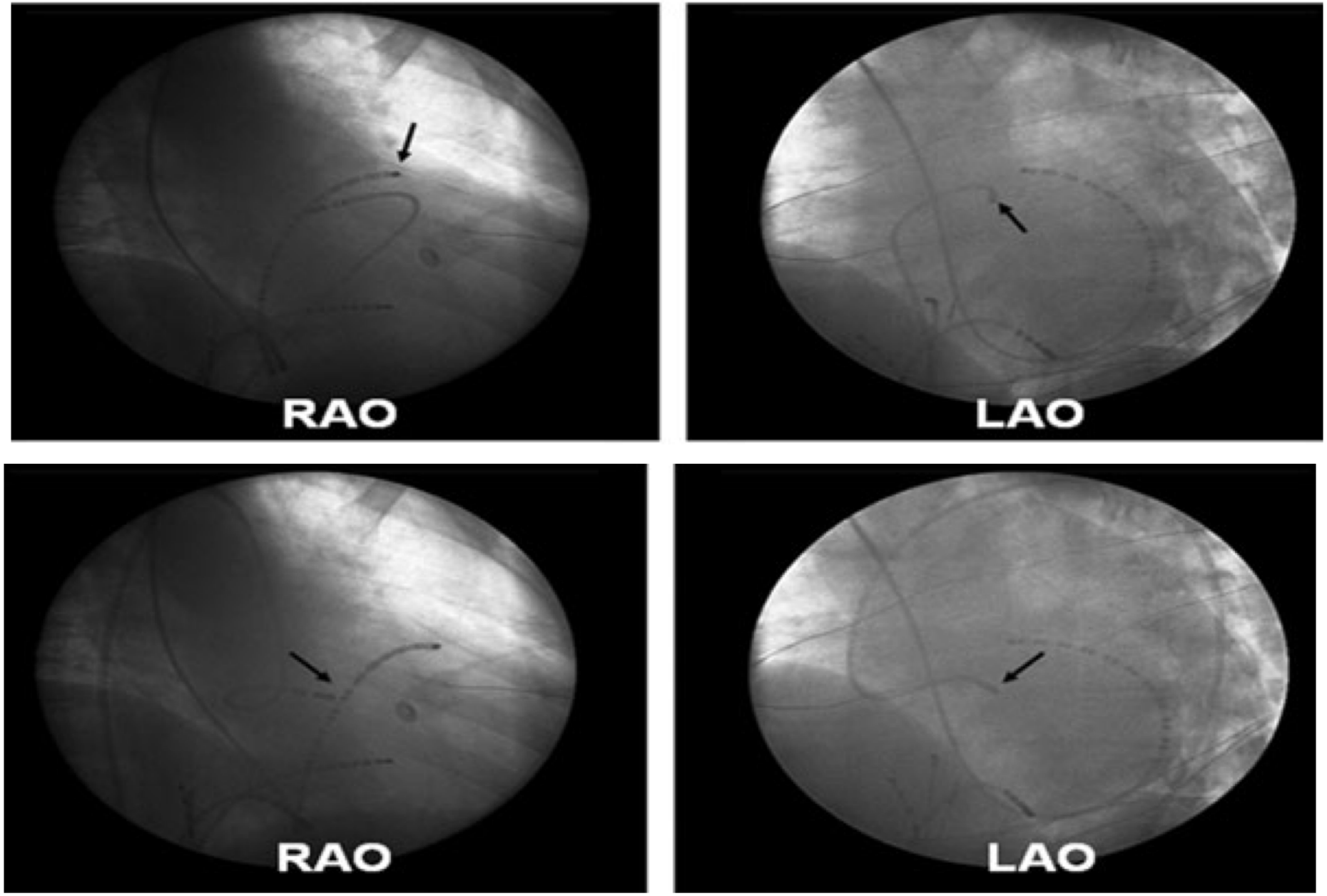

J Cardiovasc Electrophysiol 2009;20:955-968

Tercihli (preferential) ileti

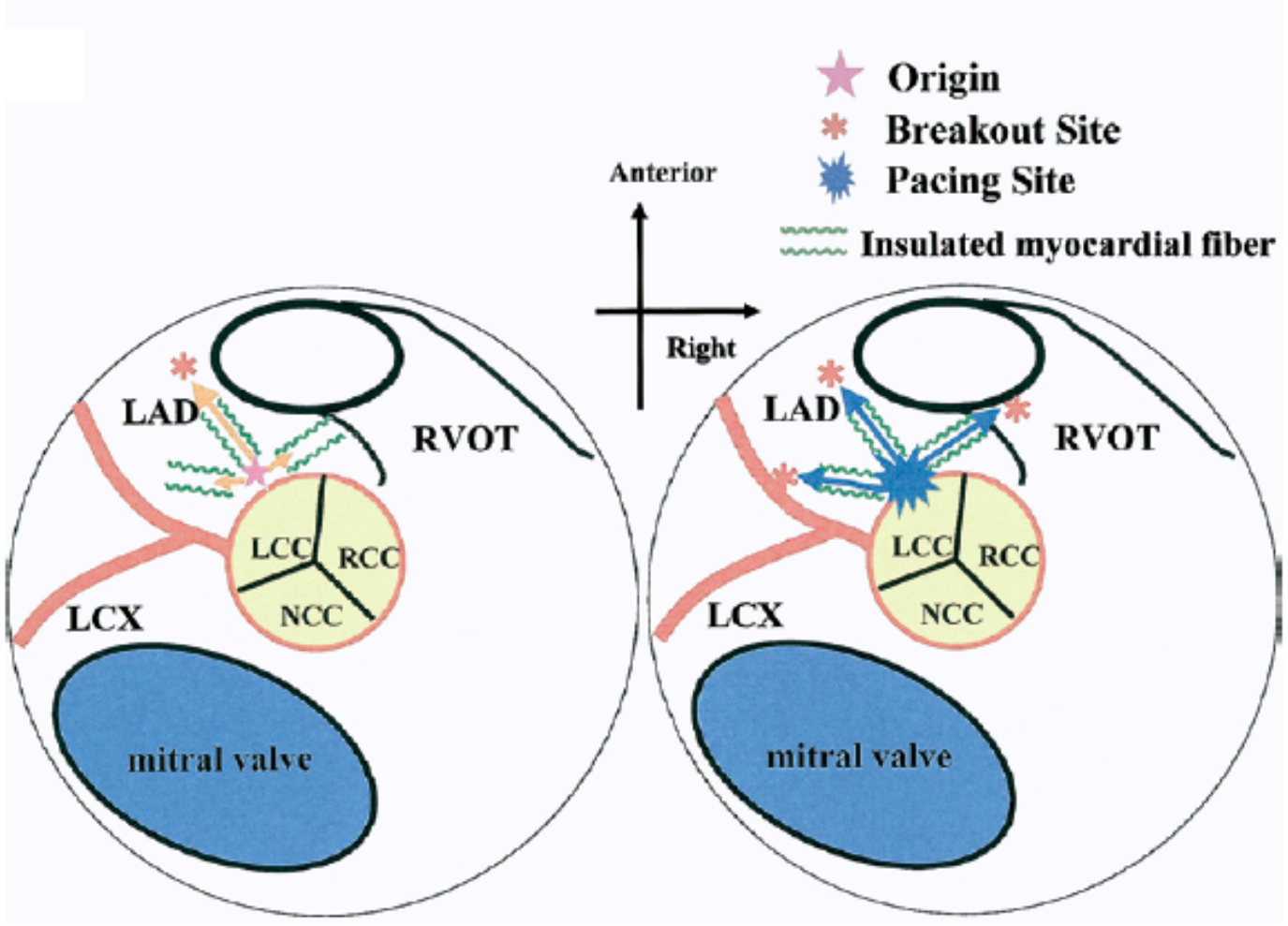

Miyokard lifleri bir çıkış yolundan diğerine uzanım gösterebilir

JACC 2007;50:884-891

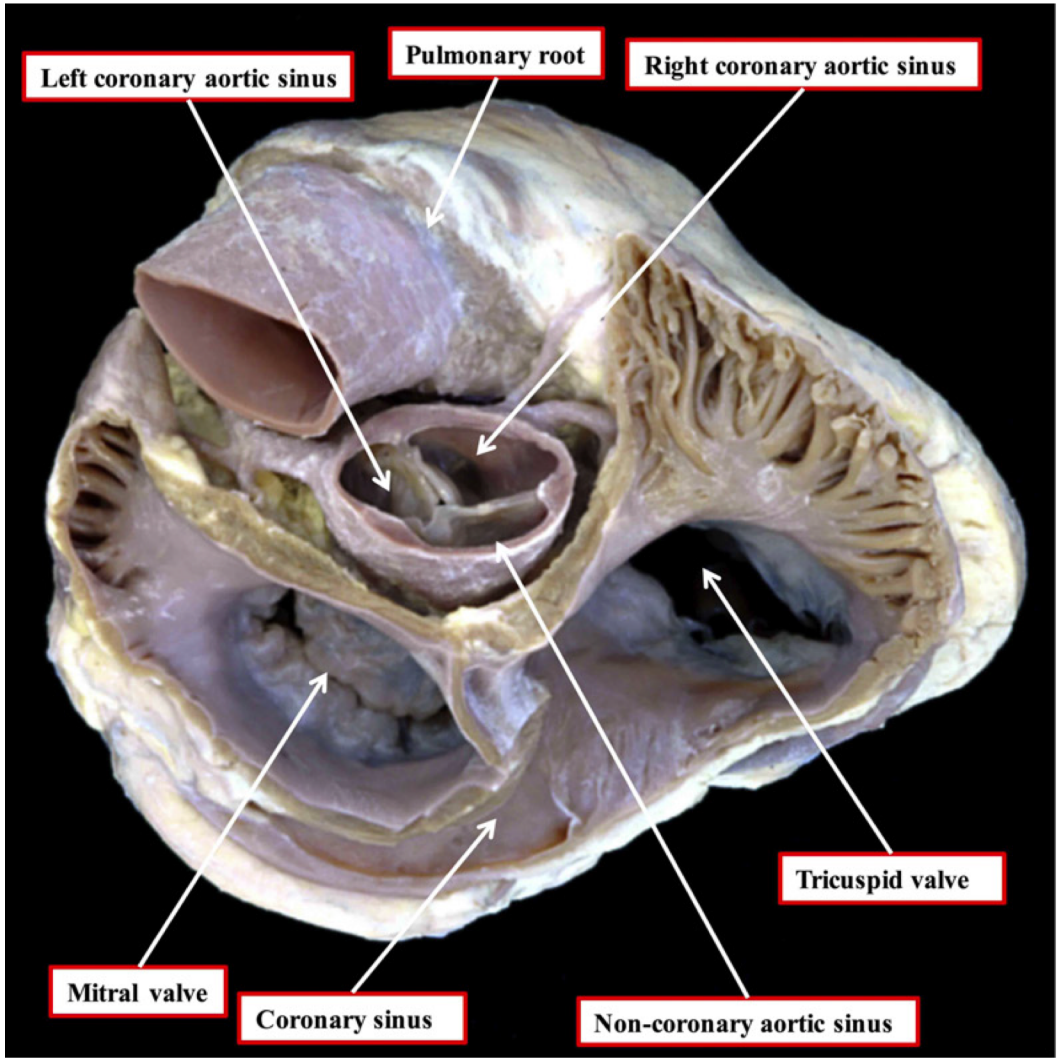
Left coronary aortic sinus
Pulmonary root
Right coronary aortic sinus
Tricuspid valve
Mitral valve
Coronary sinus
Non-coronary aortic sinus

AMC

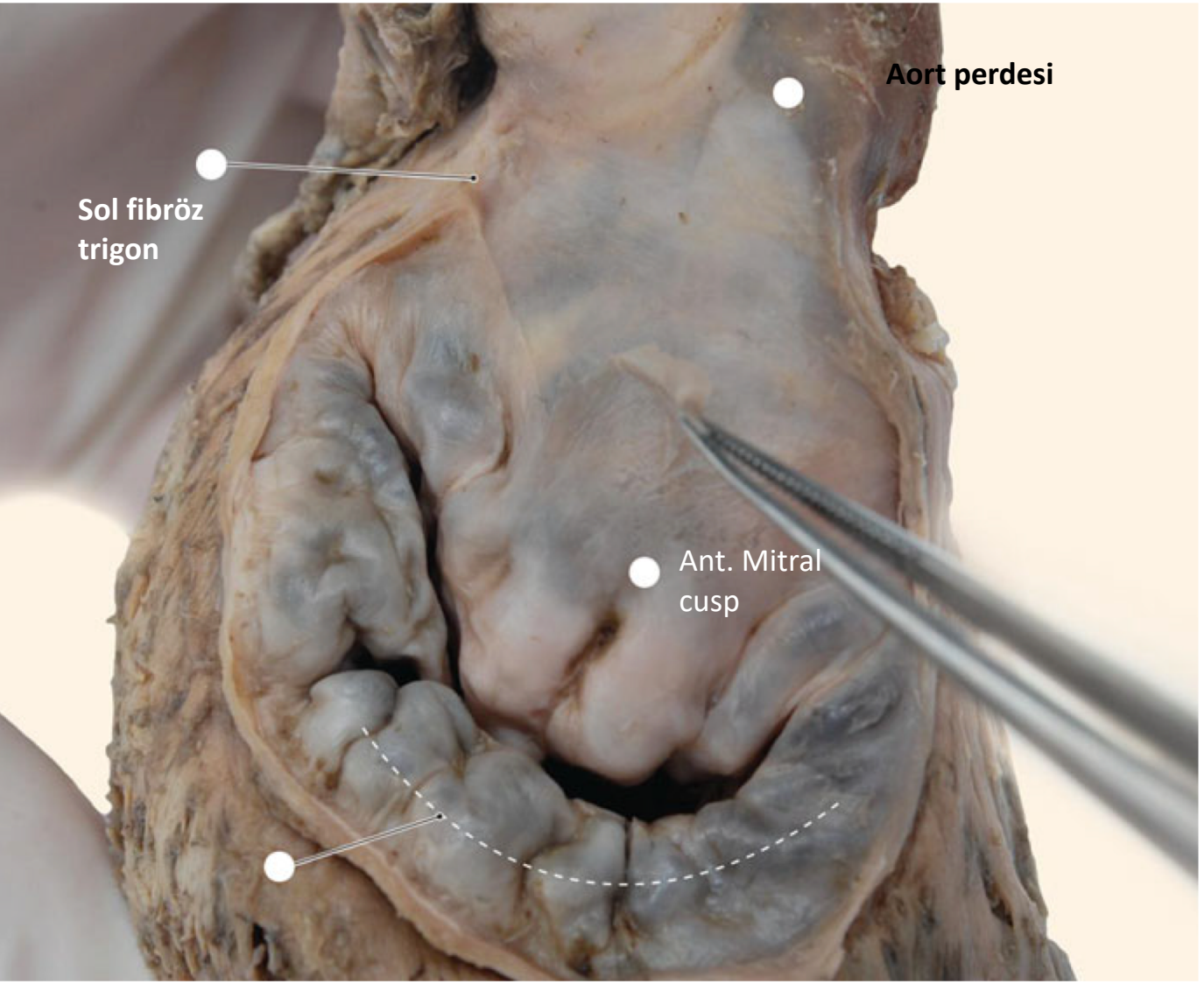

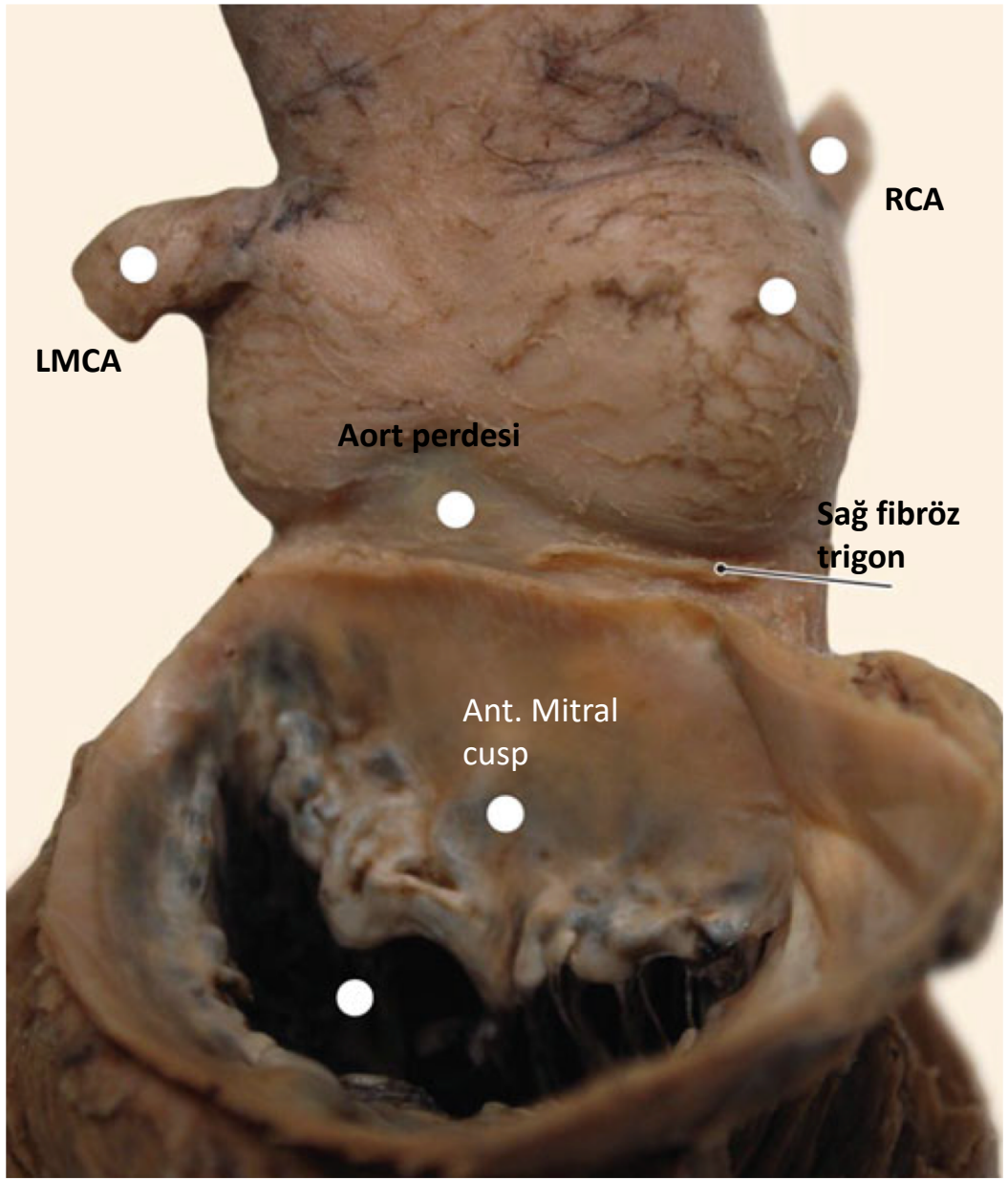

Filipoiu FM. Atlas of Heart Anatomy and Development. Springer 2012

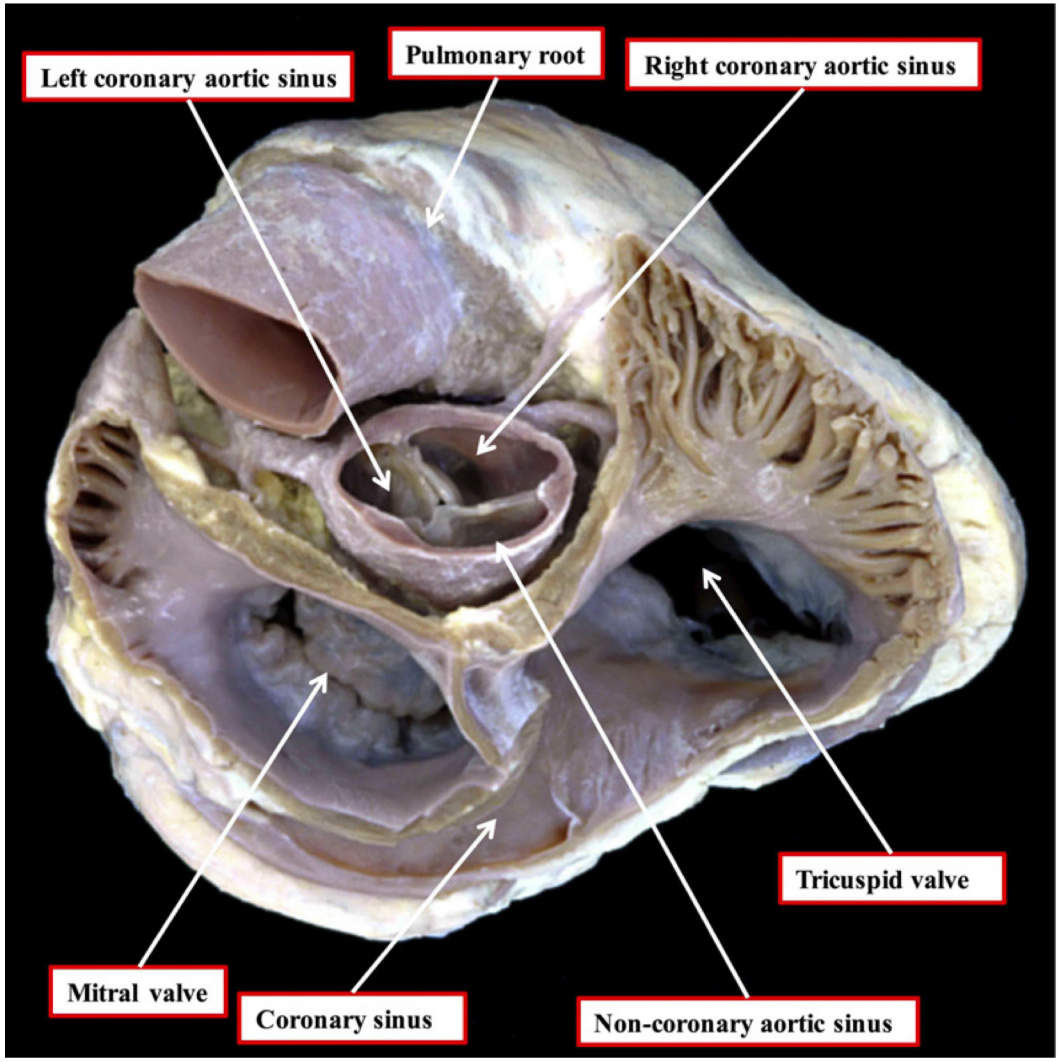
Left coronary aortic sinus
Pulmonary root
Right coronary aortic sinus
Tricuspid valve
Mitral valve
Coronary sinus
Non-coronary aortic sinus

Membranöz septum – Kalbin sol tarafından görünüm

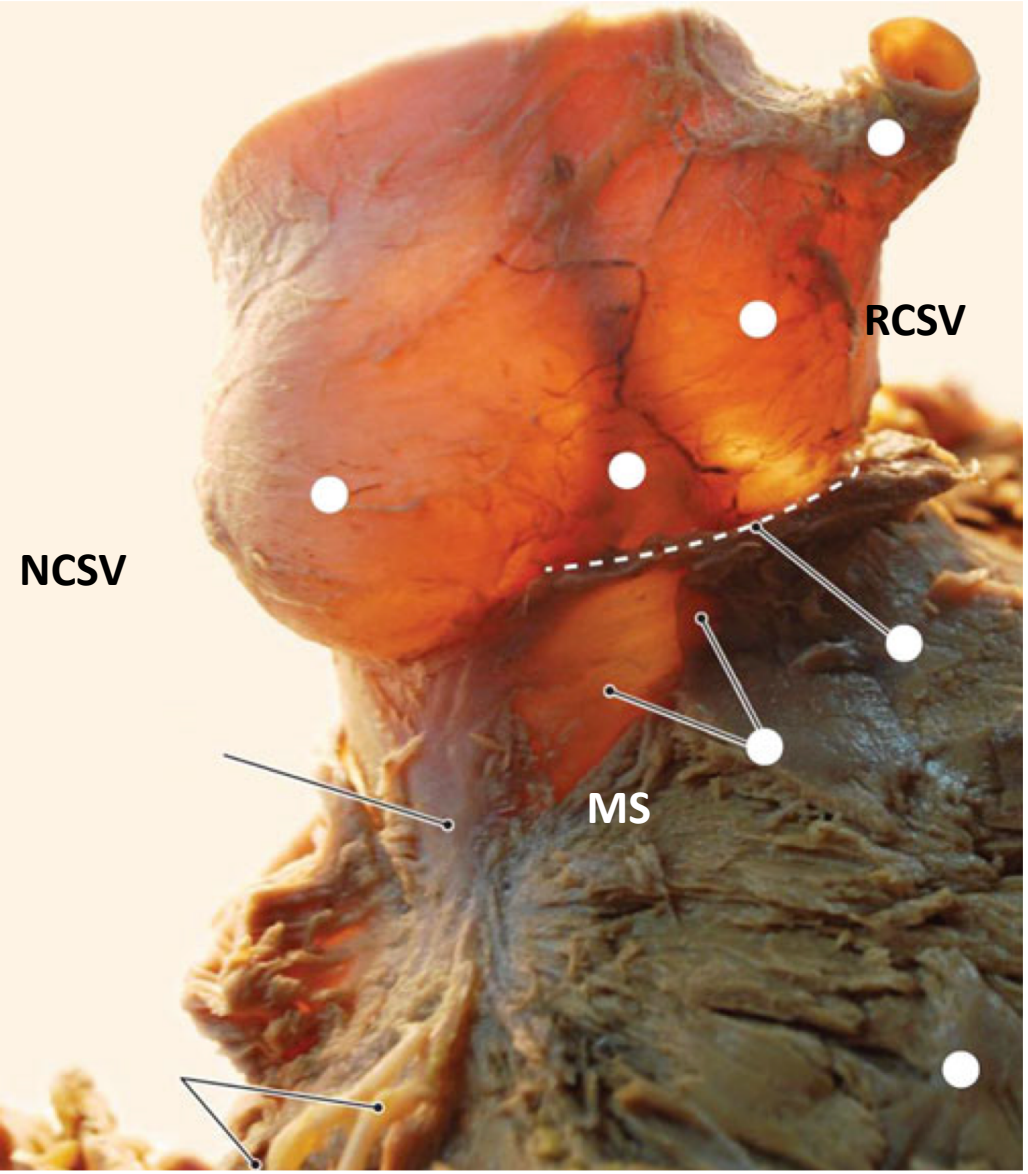

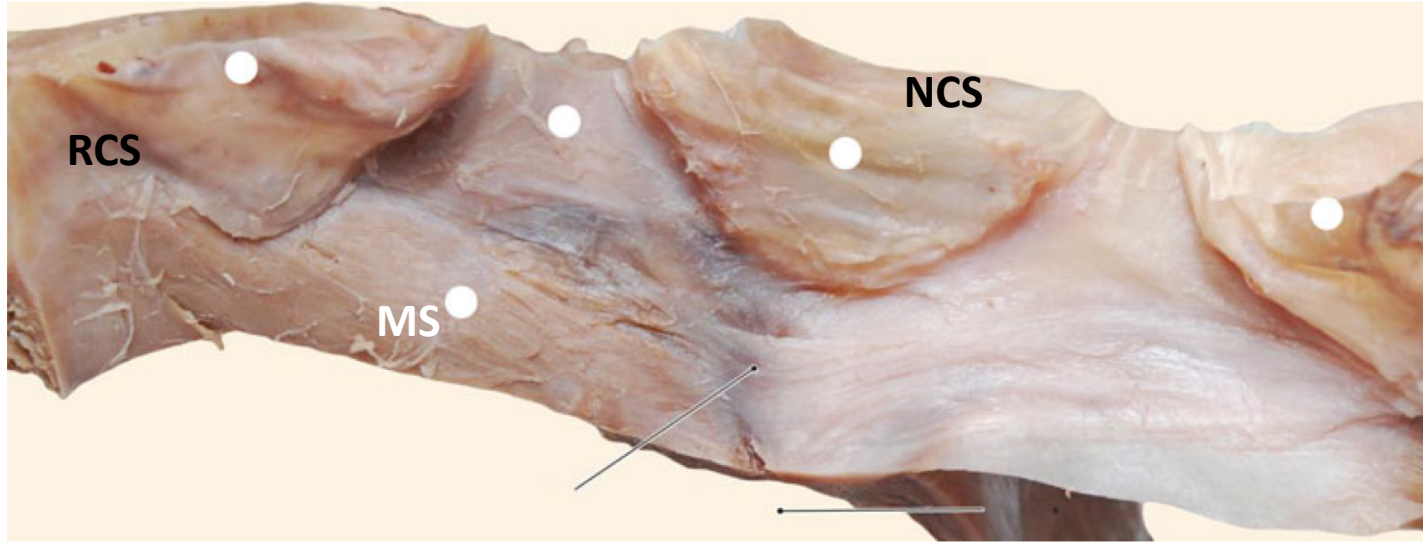

Filipoiu FM. Atlas of Heart Anatomy and Development. Springer 2012

Membranöz septum – Kalbin sağ tarafından görünüm

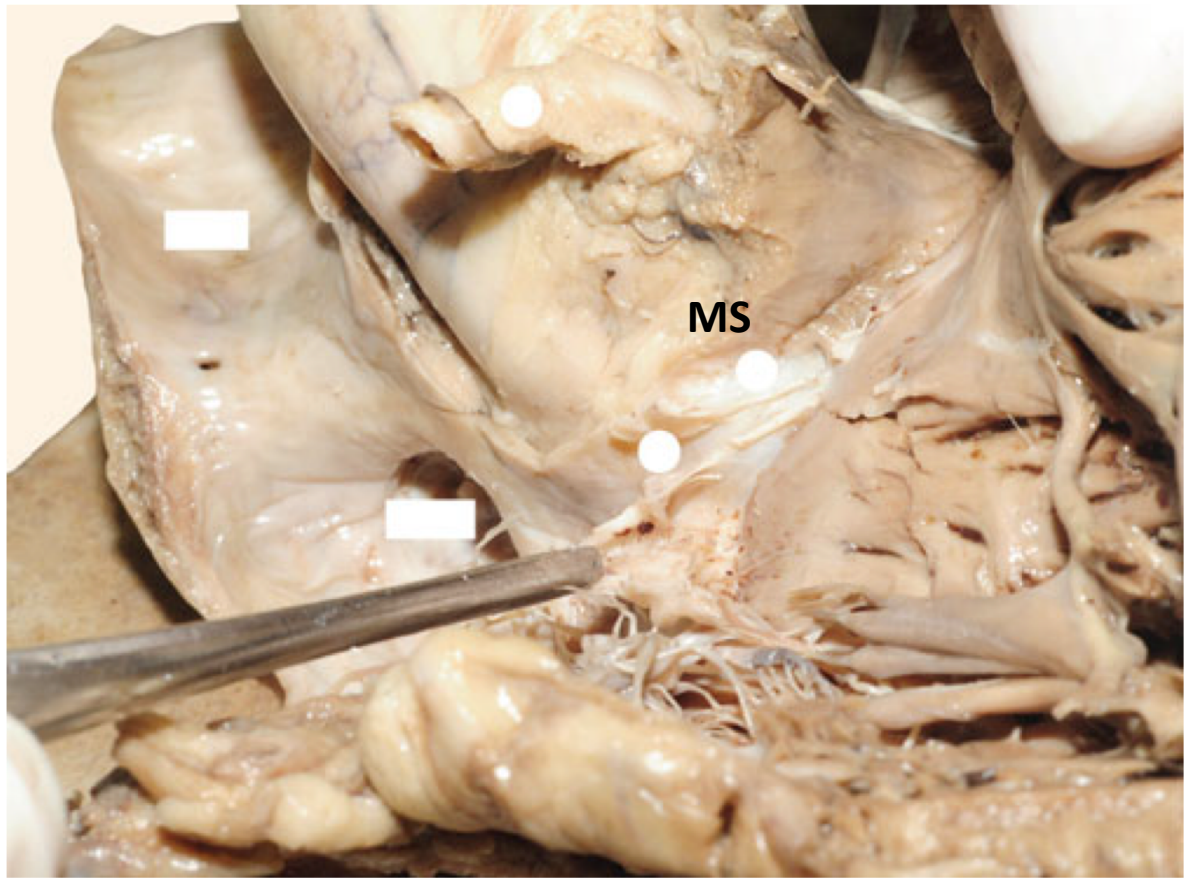

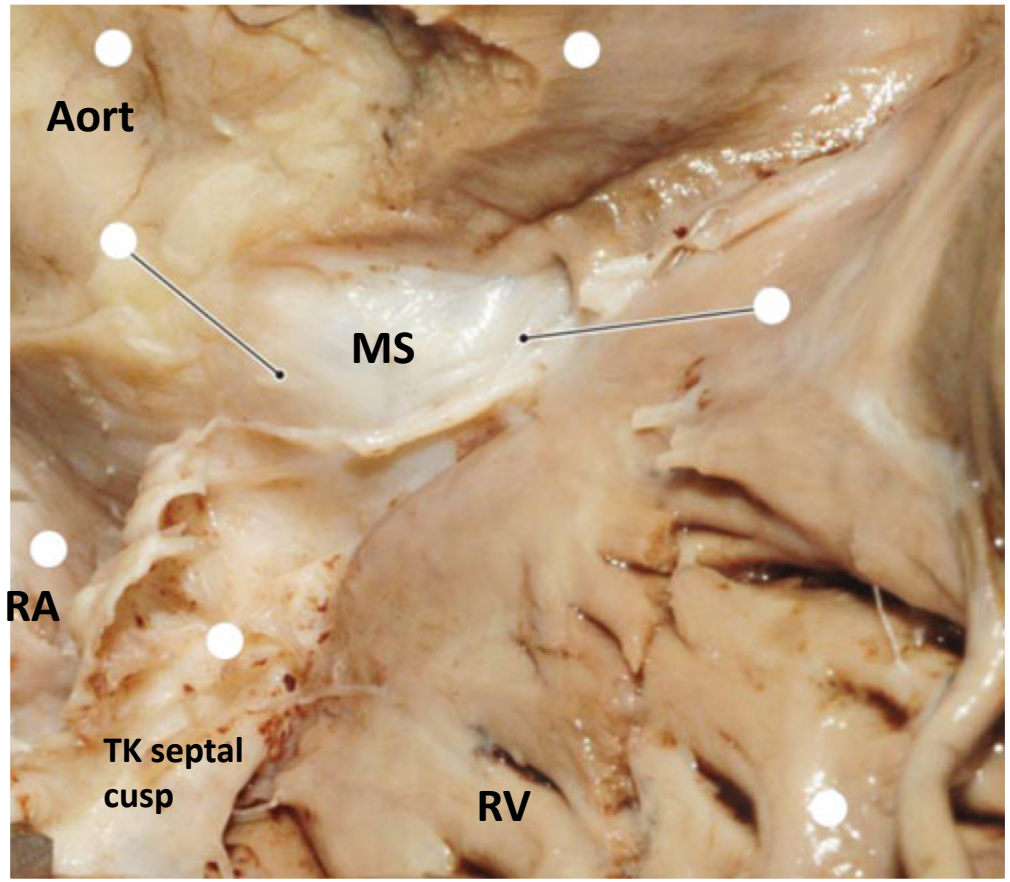

Filipoiu FM. Atlas of Heart Anatomy and Development. Springer 2012

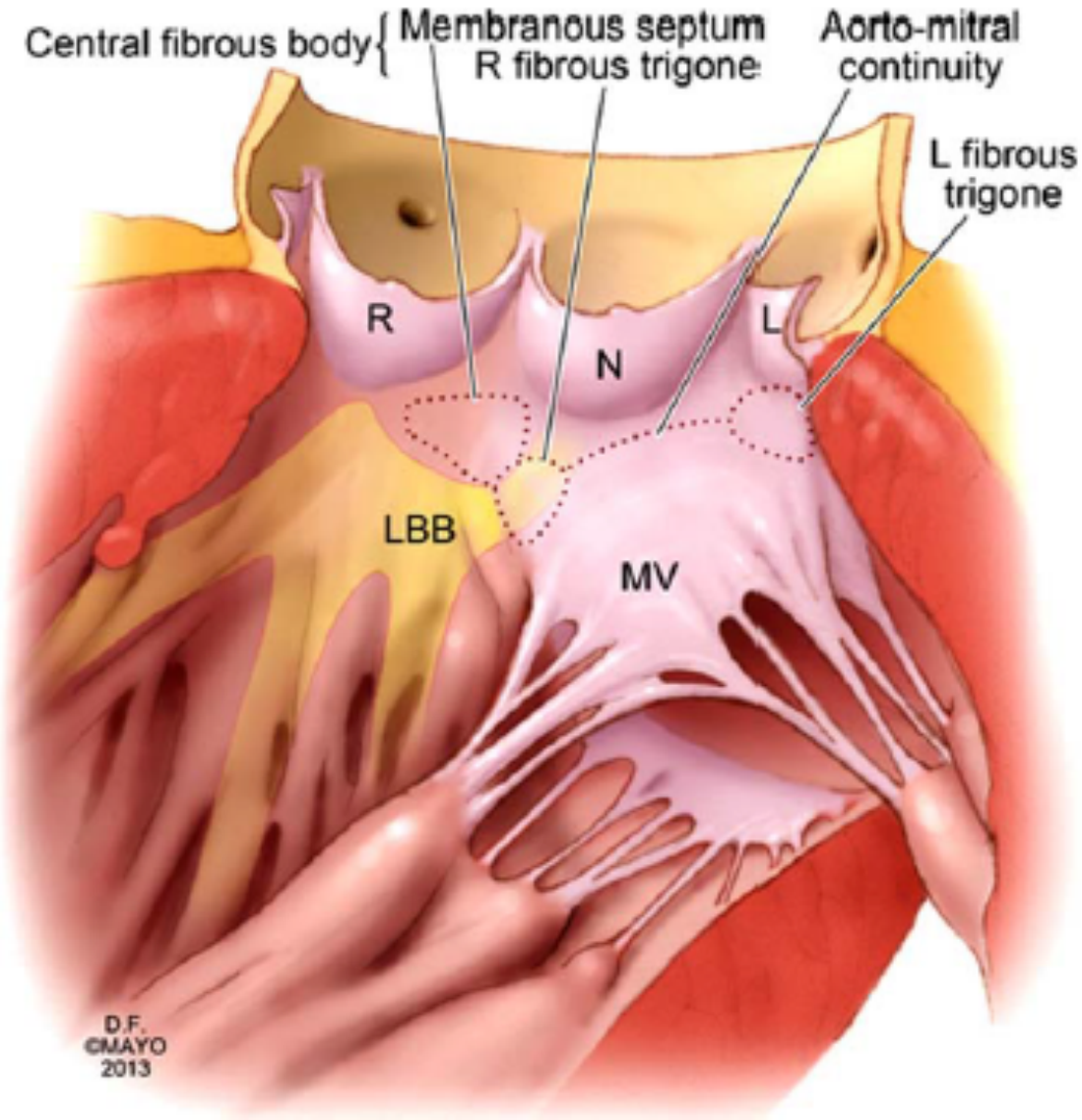

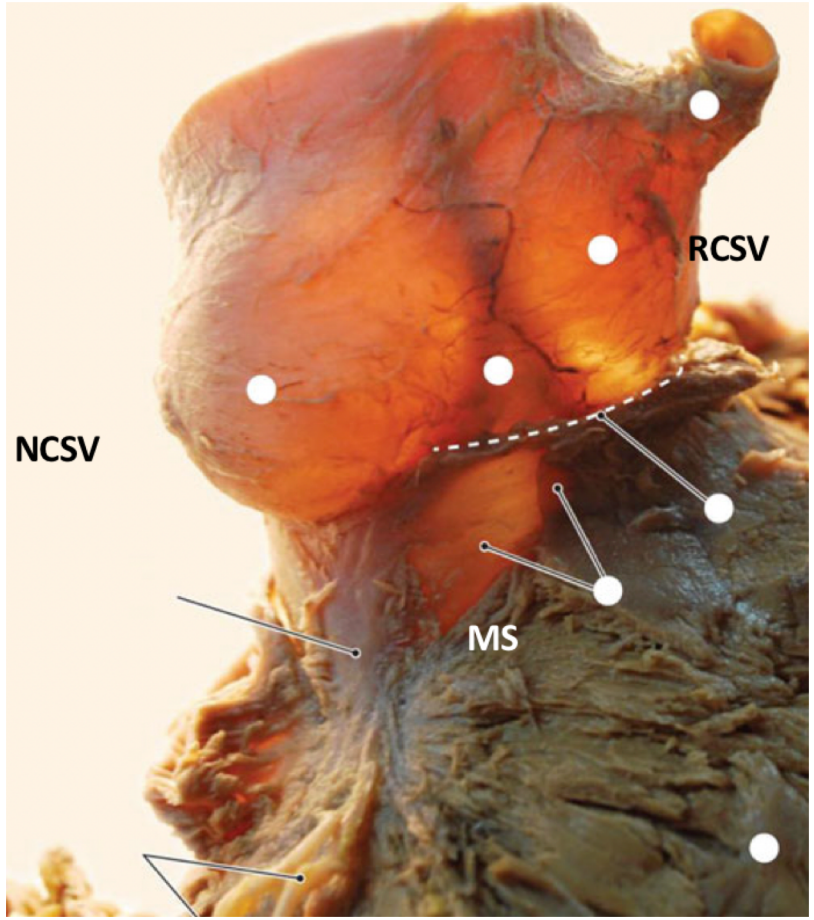

NCC veya NCC/RCC bileşkesinde ablasyon sırasında AH takibi ve junc. Tx dikkat!!

Clin Anat 2014;27(6): 885–893

Membranöz septum kaynaklı VTler

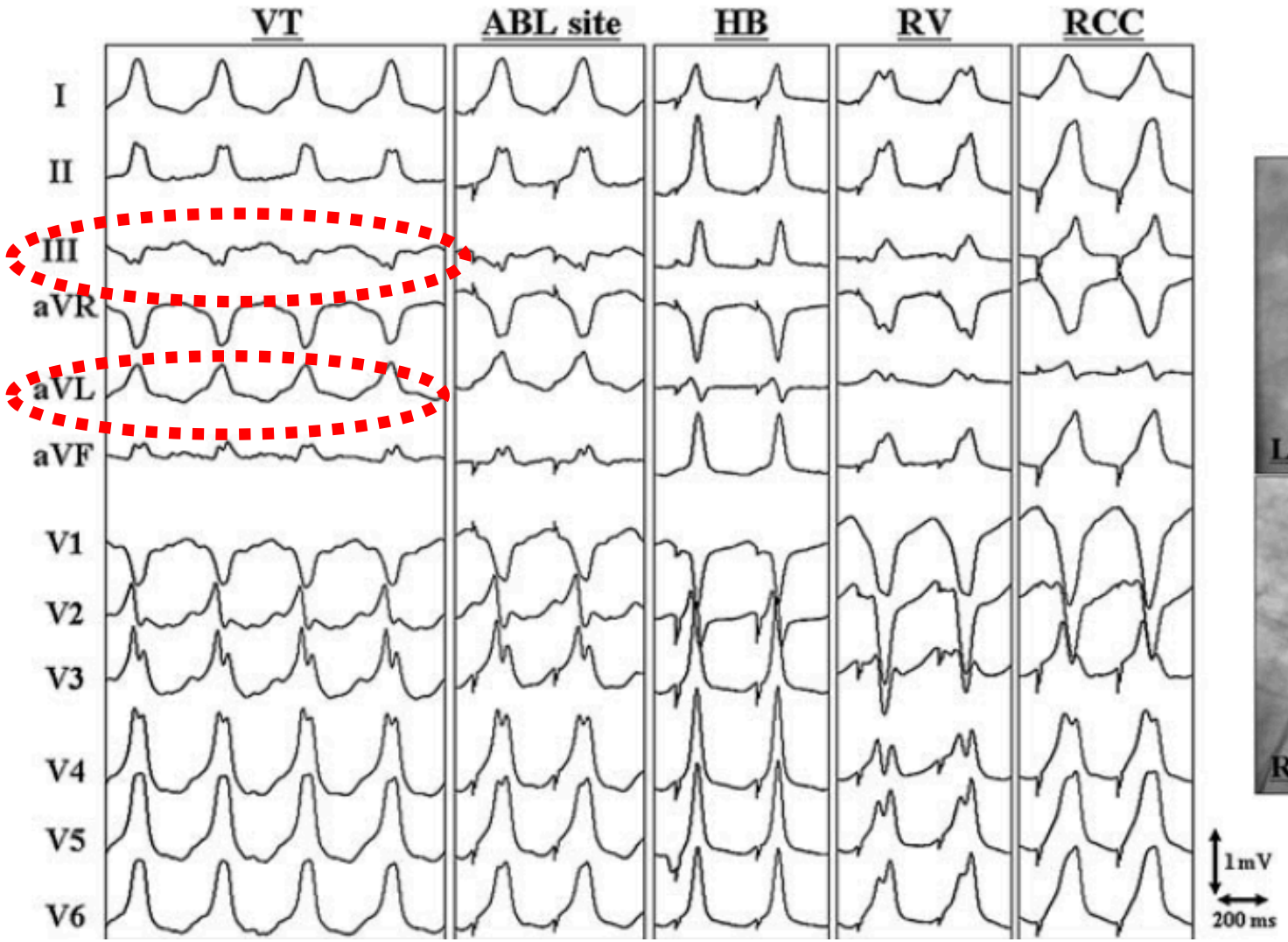

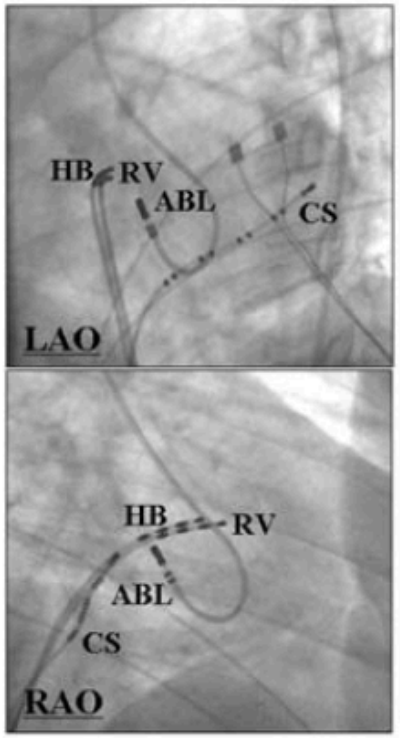

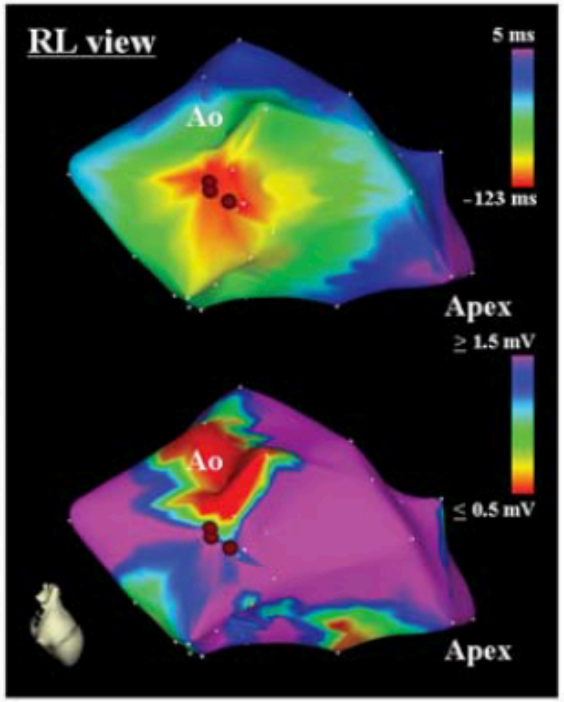

Europace 2010;12:1467–1474

LMCA, RVOT post ve PK inferiorunda seyreder

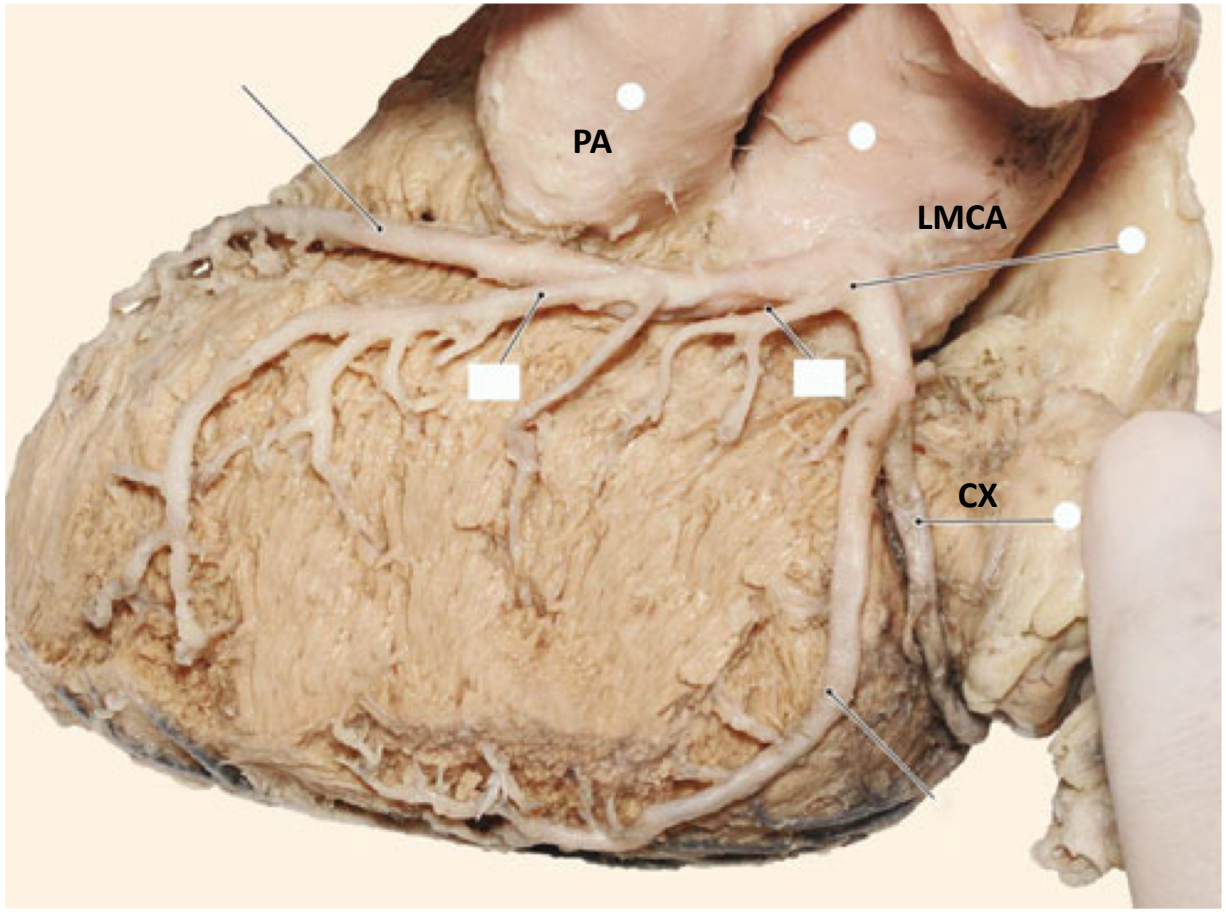

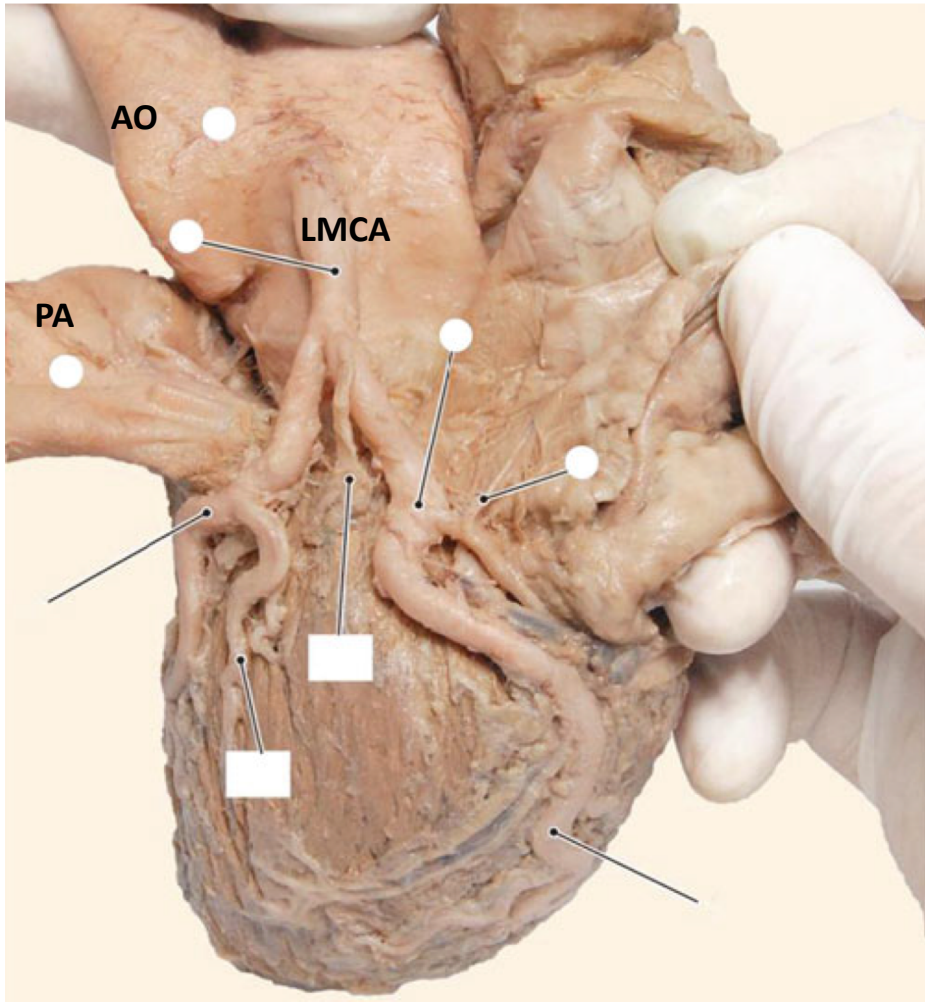

Filipoiu FM. Atlas of Heart Anatomy and Development. Springer 2012

LCC – LMCA ilişkisi

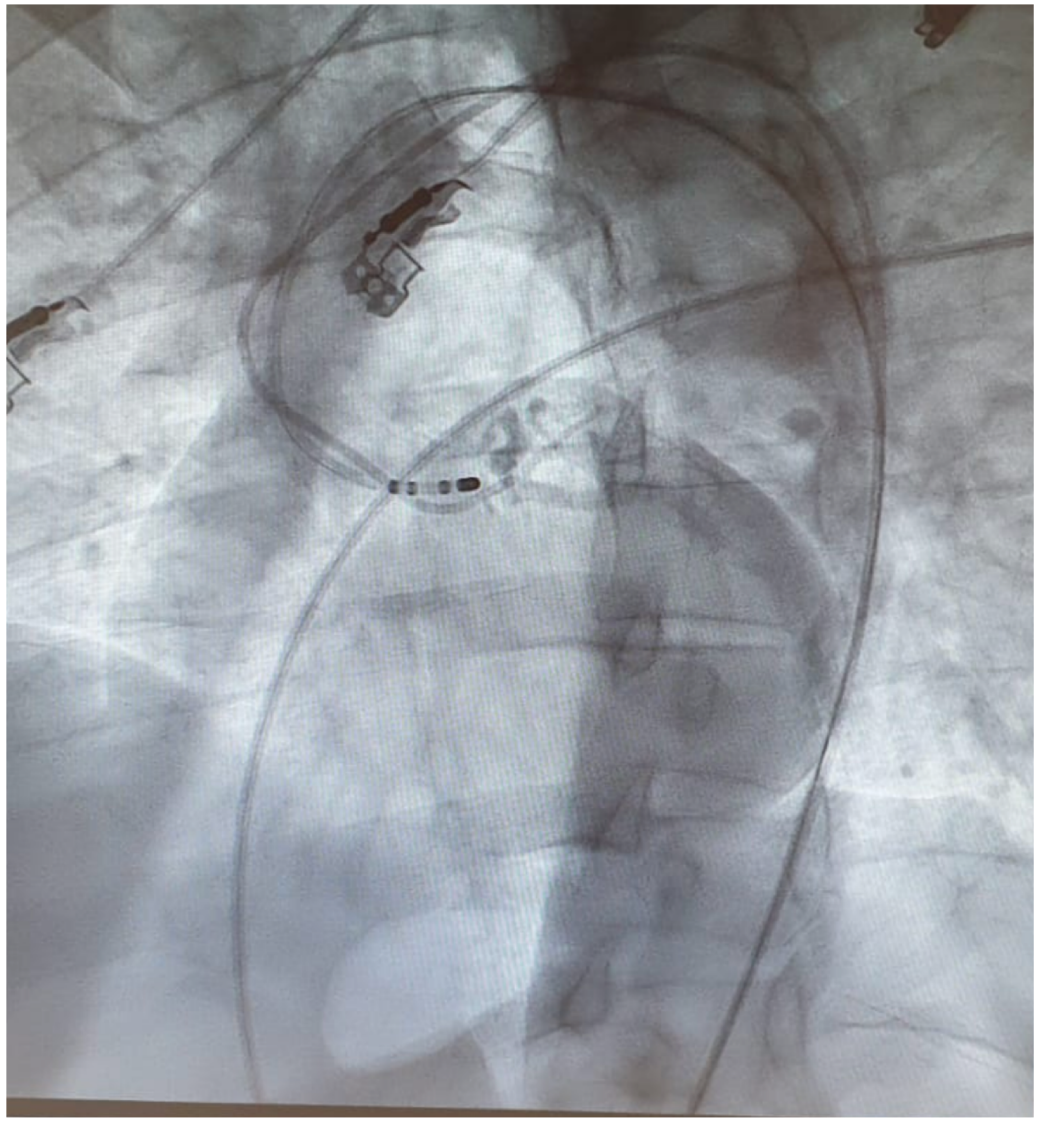

LMCA – PA ilişkisi

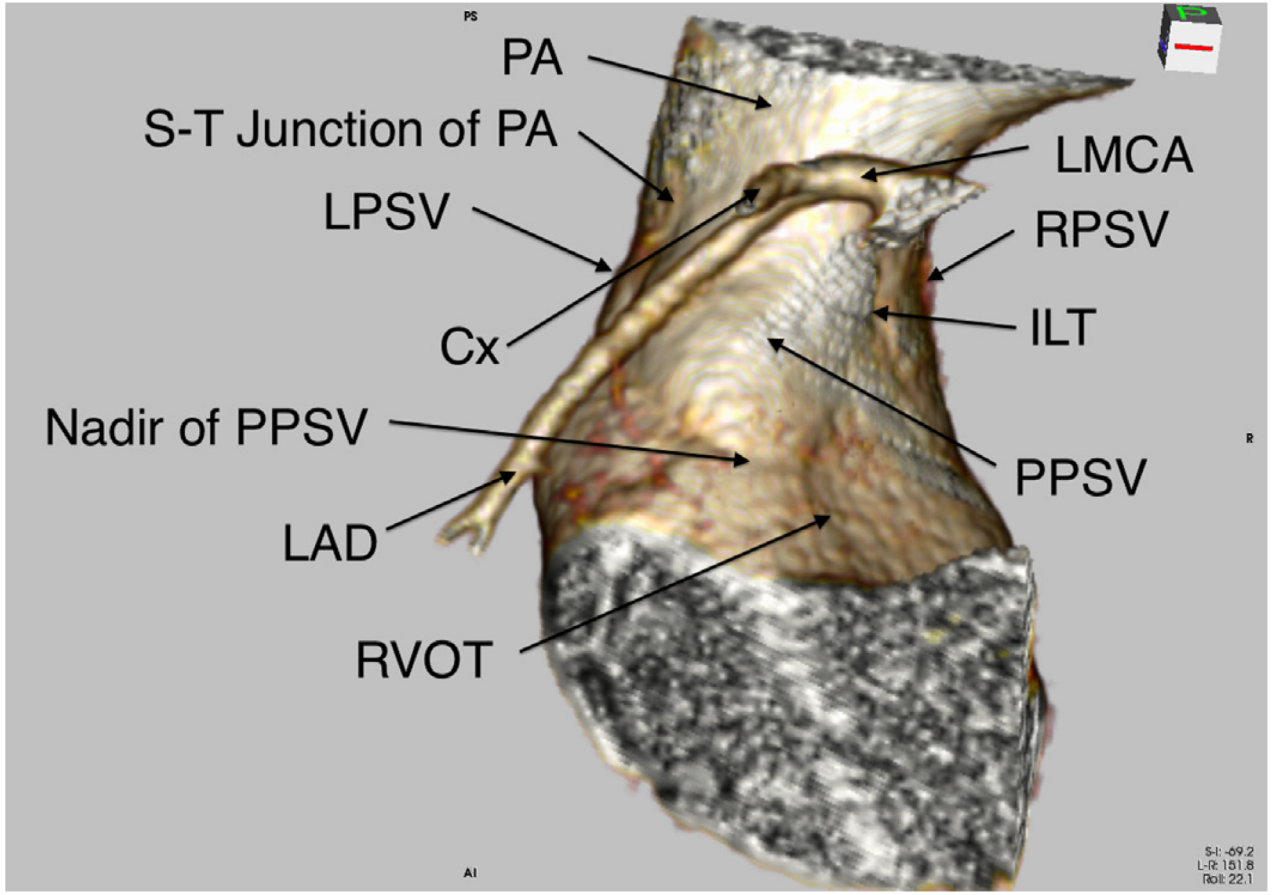

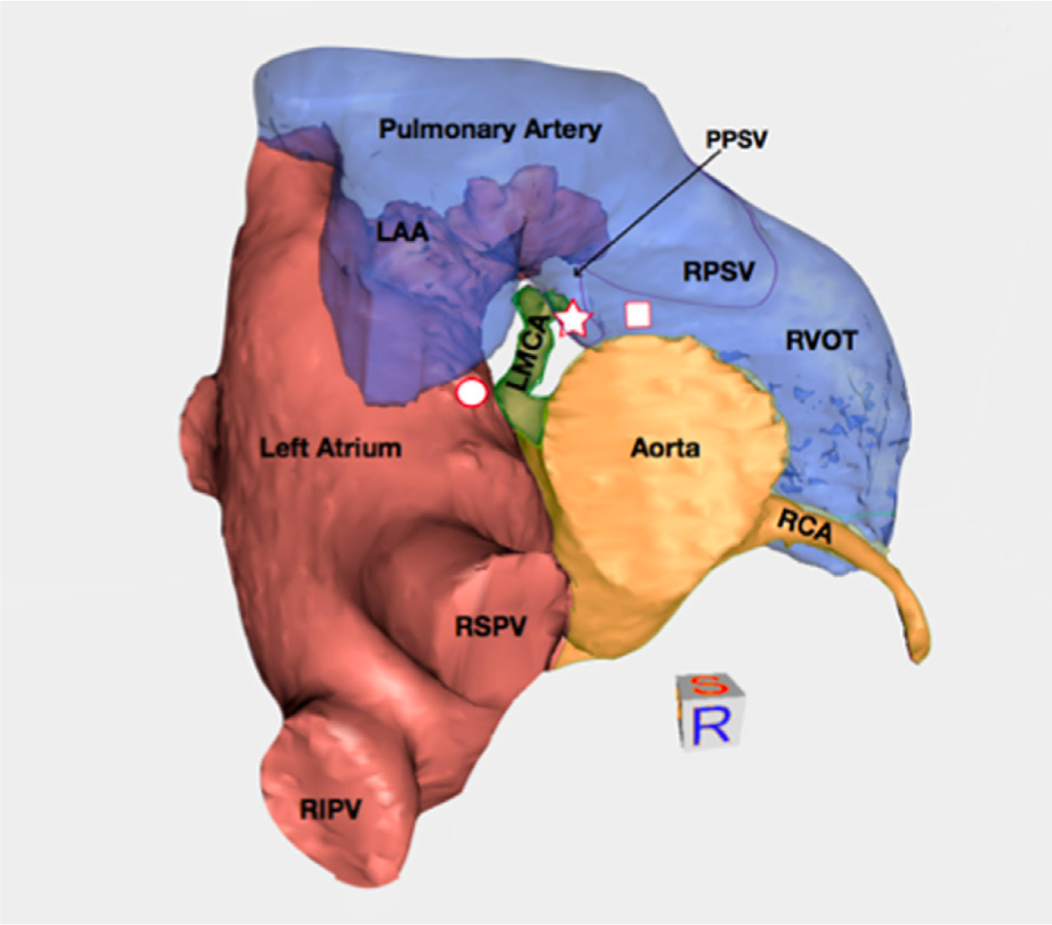

Heart Rhythm2014;11:2231–2238

Summit

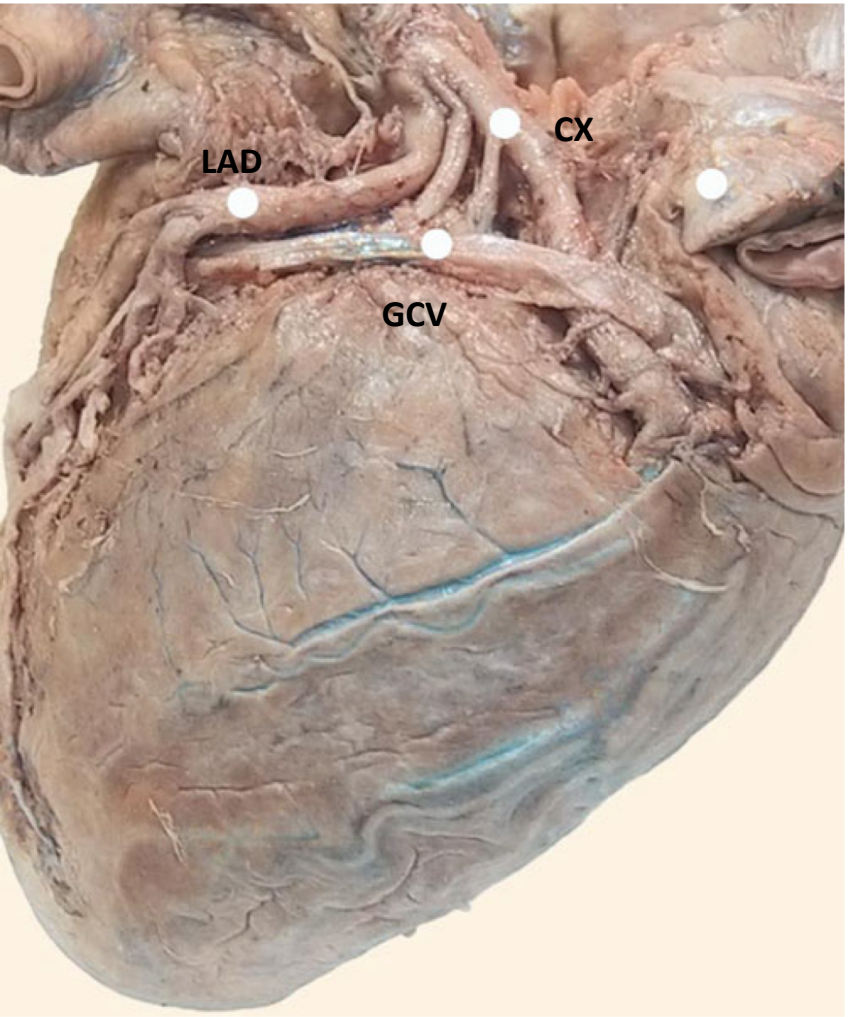
LAD
CX
GCV

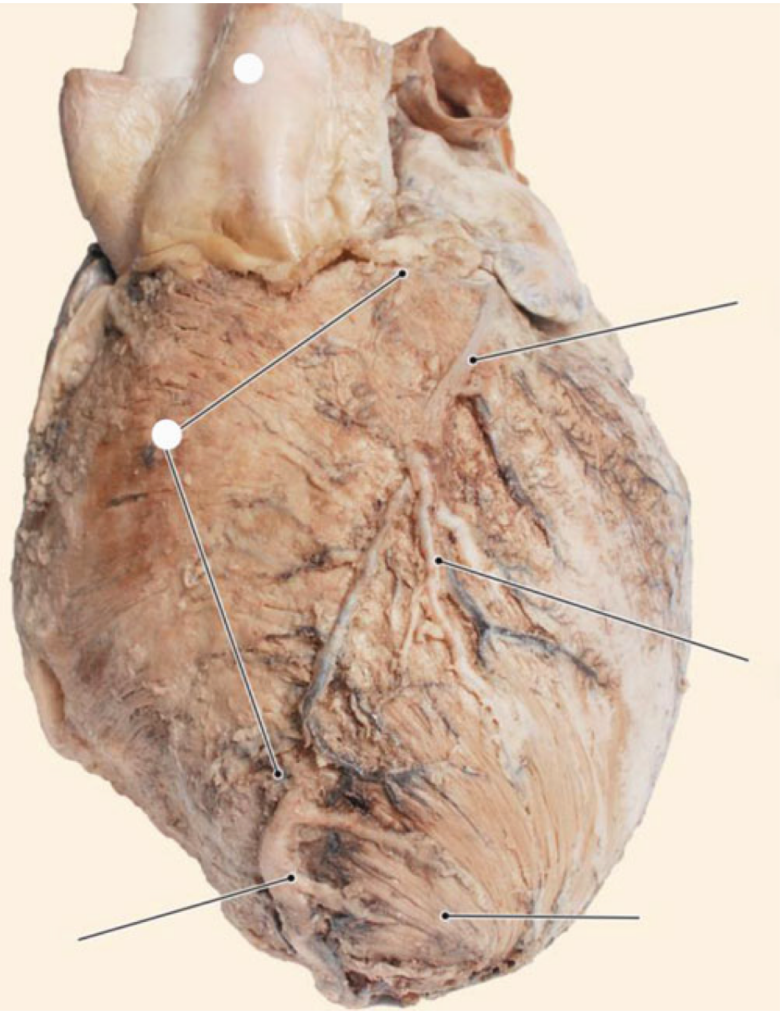

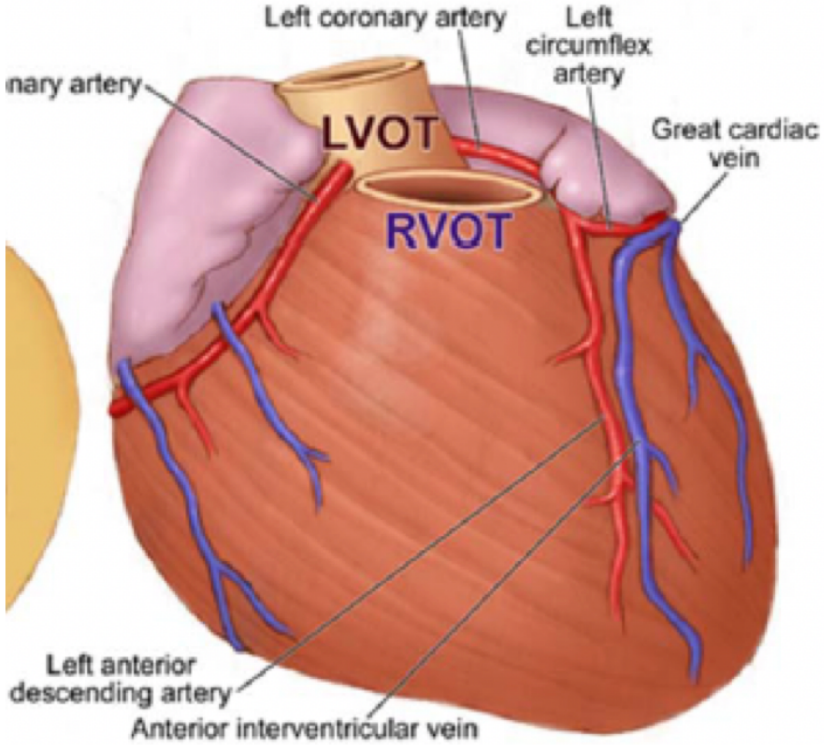
Left coronary artery
Left circumflex artery
nary artery
LVOT
Great cardiac vein
RVOT
Left anterior descending artery
Anterior interventricular vein

AİV- Sol koroner sistem ilişkisi